OPEN ACCESS

Original research

Autologous regulatory T-cell transfer in refractory ulcerative colitis with concomitant primary sclerosing cholangitis

Caroline Voskens ,[1,2] Diane Stoica,[1,2] Marita Rosenberg,[1,2] Francesco Vitali,[2,3] Sebastian Zundler ,[2,3] Marion Ganslmayer,[2,3] Heike Knott,[2,3] Manuel Wiesinger,[1,2] Jutta Wunder,[2,3] Mirko Kummer,[1,2] Britta Siegmund ,[4] Elisabeth Schnoy,[5] Timo Rath,[2,3] Arndt Hartmann,[6] Holger Hackstein,[7] Beatrice Schuler-Thurner,[1,2] Carola Berking,[1,2] Gerold Schuler,[1,2] Raja Atreya ,[2,3] Markus F Neurath [2,3]

► Additional supplemental material is published online only. To view, please visit the journal online (http://dx.doi.org/10.1136/gutjnl-2022-327075).

For numbered affiliations see end of article.

Correspondence to
Professor Markus F Neurath, Department of Medicine 1, Gastroenterology, Endocrinology and Pneumology, Erlangen University Hospital, Erlangen, Germany; markus.neurath@uk-erlangen.de

RA and MFN are joint senior authors.

Received 1 February 2022
Accepted 17 March 2022
Published Online First 15 April 2022

© Author(s) (or their employer(s)) 2023. Re-use permitted under CC BY-NC. No commercial re-use. See rights and permissions. Published by BMJ.

To cite: Voskens C, Stoica D, Rosenberg M, *et al*. *Gut* 2023;**72**:49–53.

ABSTRACT

Objective Ulcerative colitis (UC) is a chronic, debilitating immune-mediated disease driven by disturbed mucosal homeostasis, with an excess of intestinal effector T cells and an insufficient expansion of mucosal regulatory T cells (Tregs). We here report on the successful adoptive transfer of autologous, ex vivo expanded Tregs in a patient with refractory UC and associated primary sclerosing cholangitis (PSC), for which effective therapy is currently not available.

Design The patient received a single infusion of 1×10^6 autologous, ex vivo expanded, polyclonal Tregs per kilogram of body weight, and the clinical, biochemical, endoscopic and histological responses were assessed 4 and 12 weeks after adoptive Treg transfer.

Results The patient showed clinical, biochemical, endoscopic and histological signs of response until week 12 after adoptive Treg transfer, which was associated with an enrichment of intestinal $CD3^+$/$FoxP3^+$ and $CD3^+$/IL-10^+ T cells and increased mucosal transforming growth factor beta and amphiregulin levels. Moreover, there was marked improvement of PSC with reduction of liver enzymes. This pronounced effect lasted for 4 weeks before values started to increase again.

Conclusion These findings suggest that adoptive Treg therapy might be effective in refractory UC and might open new avenues for clinical trials in PSC.

Trial registration number NCT04691232.

Significance of this study

What is already known on this subject?

⇒ Experimental animal colitis models demonstrated that colitogenic immune responses can be ameliorated on administration of regulatory T cells (Tregs).

What are the new findings?

⇒ The adoptive transfer of polyclonal Tregs was associated with an improvement in gut inflammation, liver function tests and an enrichment of intestinal $CD3^+$/$FoxP3^+$ and $CD3^+$/interleukin -10^+ T cells in a patient with refractory ulcerative colitis (UC) and concomitant primary sclerosing cholangitis (PSC).

How might it impact on clinical practice in the foreseeable future?

⇒ This study strengthens the idea of a common liver–gut immune axis and supports further clinical assessment of adoptively transferred polyclonal Tregs in refractory UC and concomitant PSC.

INTRODUCTION

Ulcerative colitis (UC) is one of the major entities of IBD and is characterised by chronic, recurrent intestinal inflammation. UC is a systemic disease that can manifest itself not only in the gut but also in extraintestinal organs, including the skin, joints, eyes and the hepatobiliary tract. Disturbed mucosal homeostasis, with an excess of intestinal effector T cells and an insufficient expansion of mucosal regulatory T cells (Tregs), is a hallmark of UC.[1] The inability of the limited number of local Tregs to control the ongoing immune response leads to the perpetuation of inflammation in UC, inducing symptoms of diarrhoea, rectal bleeding and abdominal cramping. In this context, Tregs and Treg-derived cytokines such as transforming growth factor beta (TGF-β) and interleukin (IL)-10 play a central role in limiting chronic inflammation in the gut. This is based on animal models showing that mice with a disrupted IL-10 gene in their Tregs develop intestinal inflammation[2] and that IL-10 is required to maintain Treg suppressive activity in the intestine.[3] In addition, studies in experimental colitis models have demonstrated that colitogenic immune responses can be ameliorated on administration of Tregs,[4] while adoptive transfer of ex vivo TGF-β-induced Treg cells prevents the onset of colitis,[5] providing a scientific rationale for Treg-based cell therapy in UC. We have developed a protocol to produce autologous polyclonal Tregs intended for clinical use under good manufacturing practice (GMP) conditions,[6] which allowed us to

Gut: first published as 10.1136/gutjnl-2022-327075 on 15 April 2022. Downloaded from http://gut.bmj.com/ on October 20, 2023 by guest. Protected by copyright.

initiate a dose-finding clinical trial of ex vivo expanded autologous Tregs for the treatment of UC.

We here report on a patient with UC with concomitant primary sclerosing cholangitis (PSC) who received a single administration of autologous ex vivo expanded Tregs. PSC is an idiopathic, heterogeneous, cholestatic liver disease characterised by persistent, progressive, biliary inflammation and fibrosis, and frequently associated with IBD. There is no effective medical therapy for this condition and end-stage liver disease necessitating liver transplantation may ultimately develop in affected patients.[7] Reduced peripheral and intrahepatic Treg frequencies have been reported in PSC and may be involved in the immunopathogenesis of PSC by favouring proinflammatory immune responses.[8] Here, we make the unique observation that adoptively transferred Tregs induce a response in a patient with refractory UC with concomitant PSC.

METHODS

Generation and adoptive transfer of autologous ex vivo expanded Tregs

Autologous polyclonal Tregs were produced in the GMP facility of the department of dermatology as previously described.[6] In brief, $CD25^+$ cells were enriched from an initial autologous leucapheresis product by using the automatic CliniMACS Enrichment V.3.2 program of a CliniMACS device (Miltenyi Biotec) and subsequently cultivated in vitro. To facilitate ex vivo $CD25^+$ cell expansion, the supplements IL-2 (Proleucin, 1000 IU/mL), rapamycin (Miltenyi Biotec, 100 ng/mL) and anti-CD3/anti-CD28 expander beads (Miltenyi Biotec, cell-to-bead ratio 1:4) were added to the cell cultures. Cell cultures were incubated at 37°C, 5% CO_2. At days 4, 7, 11 and 18 of ex vivo expansion, cell cultures were substituted with fresh IL-2 and rapamycin. At days 7, 11 and 18 of ex vivo expansion, cell cultures were adjusted to a final concentration of 0.5×10^6 cells/mL. At day 14 of ex vivo expansion, cells were harvested and depleted of potential unwanted $CD19^+$ and $CD8^+$ cells using the automatic CliniMACS Depletion V.2.1 program of the CliniMACS device. At day 21 of ex vivo expansion, cells were harvested and depleted of anti-CD3/anti-CD28 expander beads using the automatic CliniMACS Depletion V.2.1 program of the CliniMACS device. The anti-CD3/anti-CD28 expander bead depleted cells were counted and frozen in aliquots of 45×10^6 cells per vial in a freezing solution consisting of human serum albumin (pharmaceutical grade), glucose monohydrate solution 40% (pharmaceutical grade) and dimethyl sulfoxide (sterile, endotoxin-free). The ex vivo expanded Tregs fulfilled the predefined release criteria and efficiently prohibited the proliferation of autologous $CD8^+$ effector cells in vitro (online supplemental table S1). Autologous ex vivo expanded polyclonal Tregs were adoptively transferred according to our current clinical protocol.[9]

Immunohistochemistry and quantitative PCR

Flexible sigmoidoscopy was done at baseline and weeks 4 and 12, with biopsy samples taken from the area of heaviest inflammation. Paraffin-embedded tissues were deparaffinised and antigen-unmasking was performed using citrate buffer. After blocking, slides were incubated overnight with monoclonal anti-CD3 (clone CD3-12, dilution 1:25; Bio-Rad), polyclonal anti-FoxP3 (dilution 1:100, Atlas) and polyclonal anti-IL-10 (dilution 1:400, Abcam) primary antibodies. After overnight incubation, the anti-CD3 antibody was secondary stained with anti-rat IgG alexa fluor 488 (dilution 1:500, incubation for 90 min at room temperature; Life Technologies). FoxP3 and IL-10 antibodies were secondary stained with anti-rabbit IgG biotin (dilution 1:800, Sigma) for 30 min at room temperature. Finally, for detection of FoxP3 and IL-10, final staining was performed using a TSA Cyanine 3 Kit (dilution 1:100, Akoya) according to the manufacturer's instructions. From each sample, 4–5 high-power fields per patient were analysed using ×40 objective magnification.

RNA was isolated from intestinal biopsies and 1 µg total RNA was reverse transcribed into cDNA using an iScript cDNA synthesis kit according to the manufacturer's instructions (Bio-Rad). For quantitative expression analysis, the QuantiNova SYBR green PCR kit was used according to the manufacturer's instructions (Qiagen), including quantitec primers (Qiagen) specific for TGF-β (Qiagen GeneGlobe ID: QT00000728), amphiregulin (AREG) (Qiagen GeneGlobe ID: QT00030772) and the housekeeping gene HPRT (Qiagen GeneGlobe ID: QT00059066). Data were normalised to the housekeeping gene HPRT.

RESULTS

A 48-year-old woman suffered from refractory UC with concomitant PSC. She had been diagnosed with UC that involved the entire colon (pancolitis) at the age of 18. Previous treatments with 5-aminosalicylic acid, corticosteroids, azathioprine, the anti-TNF antibody golimumab, the α4β7 integrin-antibody vedolizumab and the IL-12/IL-23 inhibitor ustekinumab did not induce a long-lasting clinical response or had, in case of the TNF-inhibitor, to be terminated prematurely due to severe skin allergic reactions (online supplemental table S2). The patient refused the initiation of additional pharmacological therapies (infliximab, cyclosporine and tofacitinib) or colectomy. She developed associated large-duct PSC at the age of 33 and underwent a liver biopsy at the age of 38, where interface hepatitis, compatible with the finding of a low-grade, chronic PSC in the prefibrotic stage (stage 2) was diagnosed. Magnetic resonance cholangiopancreatography examination described extensive stenosis of the intrahepatic and extrahepatic bile ducts, especially proximal of the common bile duct, and hepatic main branches on both sides with increasing dilatation of peripheral intrahepatic bile ducts. In addition, there were rarefied blood vessels and bile ducts as signs of marked structural damage.

On presentation, the patient reported bloody diarrhoea of up to 7×/day with abdominal cramping and reduced well-being, reflecting severe disease. There were signs of marked inflammation on endoscopy with mucosal ulcerations and a total Mayo Score of 8 points. Besides long-term treatment with mesalamine 4 g/day (30 years) and ursodeoxycholic acid 1000 mg/day (16 years), the patient did not take any other concomitant medication, and the last treatment with a biological agent was terminated more than 12 weeks prior to the planned Treg transfer. After preparatory leukapharesis and subsequent ex vivo expansion of autologous polyclonal Tregs, the patient received a single infusion of 1.0×10^6 Tregs/kg bodyweight, totalling 84 million Tregs. Neither preinfusion nor postinfusion conditioning was performed. The patient did not have any adverse events that were considered by the treating physicians to be related to the Treg therapy, and there were no changes in concomitant medication after adoptive Treg transfer. A tabular listing of previous and concomitant medication along with the assessed clinical and laboratory parameters before and after adoptive Treg transfer is provided in online supplemental tables 3–5, respectively.

After adoptive Treg transfer, the patient's symptoms gradually improved with reduction of stool frequency and absence of rectal bleeding, and the clinical disease activity score (partial Mayo

Gut: first published as 10.1136/gutjnl-2022-327075 on 15 April 2022. Downloaded from http://gut.bmj.com/ on October 20, 2023 by guest. Protected by copyright.

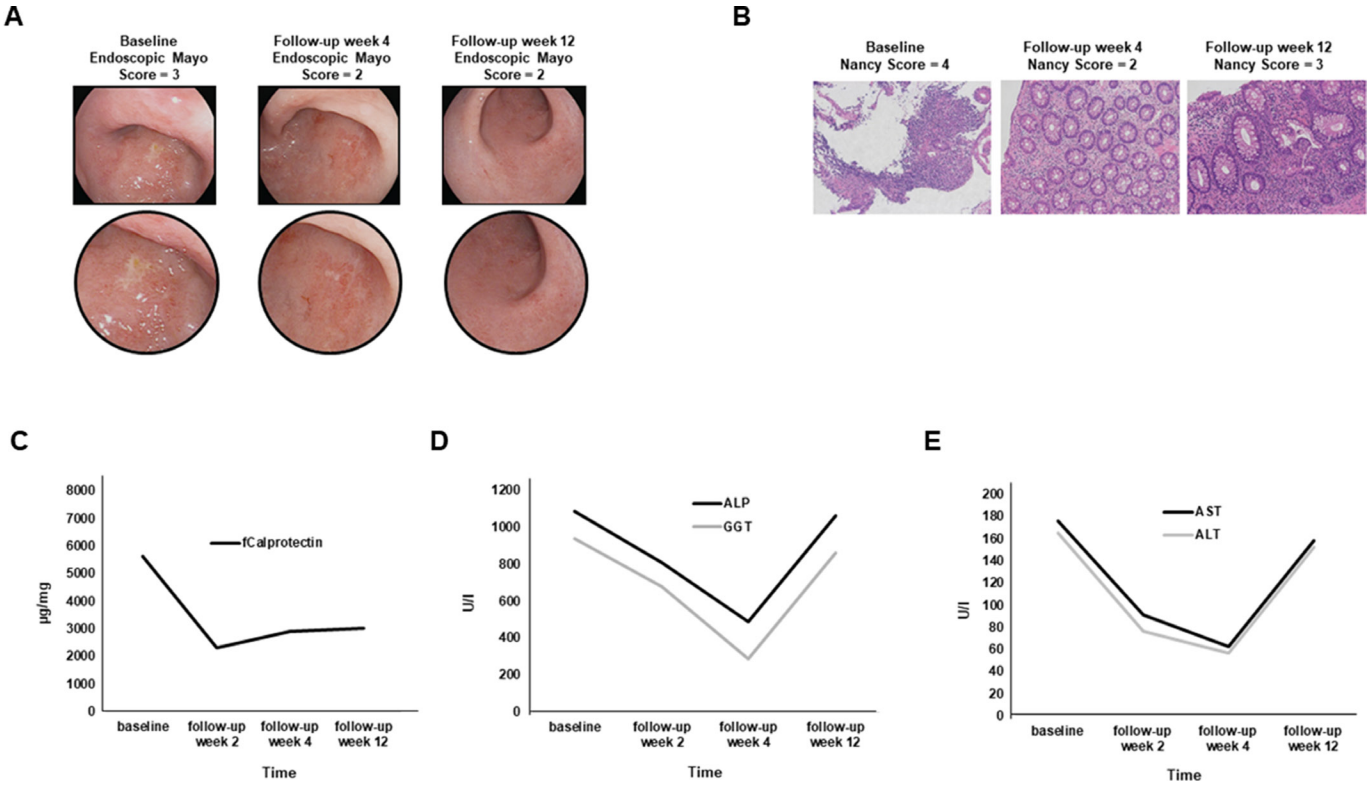

Figure 1 Regression of mucosal ulcerations, reduction of fCalprotectin levels and transient improvement of PSC after adoptive Treg transfer. (A) Endoscopic examination showing a regression of mucosal ulcerations 4 and 12 weeks after adoptive Treg transfer accompanied by a reduction in the endoscopic Mayo score. (B) Representative 20× H&E stainings showing an improvement in Nancy Score 4 and 12 weeks after adoptive Treg transfer. (C) Reduced fCalprotectin levels after adoptive Treg transfer. (D) Transient improvement in serum ALP and GGT levels after adoptive Treg transfer. (E) Transient improvement in serum AST and ALT levels after adoptive Treg transfer. ALP, alkaline phosphatase; ALT, alanine aminotransferase; AST, aspartate aminotransferase; fCalprotectin, faecal calprotectin; GGT, gamma-glutamyl transferase; Treg, regulatory T cell.

Score) decreased from 7 points on the day of the Treg transfer to 4 points (follow-up week 2) and 2 points (follow-up week 8) after Treg transfer, respectively. This clinical improvement was also reflected in the endoscopic evaluation, as the ulcerations had regressed considerably. The Mayo Endoscopic Score dropped from 3 points at baseline to 2 points 4 and 12 weeks after Treg transfer, respectively (figure 1A), resulting in a total Mayo Score of 8 points (baseline), 6 points (follow-up week 4) and 4 points (follow-up week 12), respectively. Moreover, the histological activity score (Nancy Score) also dropped from 4 points (baseline) to 2 points (follow-up week 4) and 3 points (follow-up week 12) after adoptive Treg transfer (figure 1B). These marked improvements were also accompanied by a significant and rapid reduction of faecal calprotectin (fCalprotectin) levels with values dropping from 5637 µg/g at baseline to 2326 µg/g 2 weeks after adoptive Treg transfer and continuously reduced levels 4 and 12 weeks after adoptive Treg transfer (figure 1C). Additional laboratory tests revealed a profound improvement of laboratory liver function values 2 and 4 weeks after Treg transfer. Specifically, we noted a marked decline of serum alkaline phosphatase (ALP) and gamma-glutamyl transferase (GGT) levels (figure 1D), as well as aspartate aminotransferase (AST) and alanine aminotransferase (ALT) levels (figure 1E) that was already visible 2 weeks, and even more pronounced, 4 weeks after adoptive Treg transfer with a decline of ALP levels by 12% and 47%, respectively. This effect was transient, with values returning to baseline levels 12 weeks after adoptive Treg transfer.

The consistent Treg transfer-associated improvement of UC led us to hypothesise that the infused Tregs may have migrated into the gut. We performed immunohistochemistry on biopsies obtained from the same mucosal area at baseline and 4 and 12 weeks after adoptive Treg transfer and stained for the expression of Treg-specific FoxP3 and IL-10. The staining revealed a consequent increase in gut-associated FoxP3-expressing and IL-10-expressing T cells, reflecting Tregs, 4 and 12 weeks after adoptive Treg transfer (figure 2). In addition, using quantitative PCR, we detected an 1.75-fold increase in TGF-β mRNA expression (online supplemental figure 1A) and an 5.39-fold increase in AREG expression (online supplemental figure 1B) in the gut 4 weeks after adoptive Treg transfer.

DISCUSSION

Our findings demonstrate that an adoptive transfer of autologous ex vivo expanded polyclonal Tregs may induce clinical, biochemical, endoscopic and histological responses in refractory UC. The increase of mucosal regulatory FoxP3$^+$ T cells with the corresponding upregulation of IL-10 is in agreement with the concept that transferred Tregs migrated to the inflamed colon on transfer and ameliorated local disease activity. So far, only one study has been conducted in IBD, where the efficacy of ovalbumin-specific Tregs was studied in Crohn's disease.[10] Clinical responses were noted in 40% (8/20) of patients using the Crohn's Disease Activity Index 5 and 8 weeks after adoptive Treg transfer. Endoscopic responses were not assessed in this study and fCalprotectin levels showed a small decreasing trend in the overall study population.

Gut: first published as 10.1136/gutjnl-2022-327075 on 15 April 2022. Downloaded from http://gut.bmj.com/ on October 20, 2023 by guest. Protected by copyright.

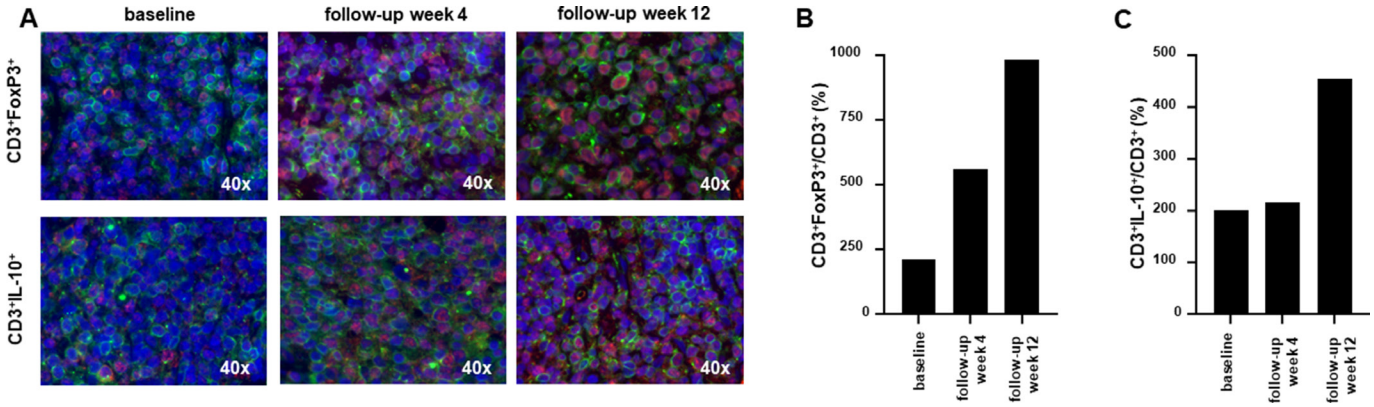

Figure 2 Enrichment of CD3$^+$FoxP3$^+$ and CD3$^+$IL-10$^+$ cell populations in the gut. (A) Images of immunohistochemistry staining demonstrating the enrichment of CD3$^+$FoxP3$^+$ cells and CD3$^+$IL-10$^+$ cells 4 and 12 weeks after adoptive Treg transfer. Samples were analysed using ×40 objective magnification. Green cells represent CD3$^+$ T cells, and red cells are Foxp3$^+$ or IL-10$^+$ cells, as indicated. (B) Quantification of CD3$^+$FoxP3$^+$ cells and (C) CD3$^+$IL-10$^+$ cells in relation to total CD3$^+$ cells 4 and 12 weeks after adoptive Treg transfer. IL, interleukin; Treg, regulatory T cell.

The pronounced improvement of pathological liver values in our patient indicates that Treg therapy may induce a biochemical response in associated PSC as well. PSC is an immune-mediated chronic liver disease characterised by inflammation, fibrosis and progressive destruction of intrahepatic and extrahepatic bile ducts leading to the onset of cirrhosis and end-stage liver disease. There is also an increased risk of the development of cholangiocarcinoma, with a lifetime risk of up to 20%. Currently, there are no approved pharmacological therapies for PSC, and liver transplantation is the only available therapeutic option to improve clinical outcomes. IBD, mostly UC, is closely associated with PSC, as it is present in up to 62%–83% of patients with PSC. The close association of PSC with UC implicates the existence of a common liver–gut immune axis that drives these immune-mediated diseases. T cells play a pivotal role in the pathogenesis of both UC and PSC, as aberrant migration of gut homing mucosal memory lymphocytes have strongly been implicated in disease pathogenesis. After antigen recognition by dendritic cells in gut-associated lymphoid tissue, naïve T cells are imprinted with the gut-specific chemokine receptor CCR9 and integrin α4β7. These primed T cells are thought to migrate to the liver through the aberrant expression of their associated ligands, mucosal vascular addressin cell adhesion molecule (MAdCAM)-1 and the chemotactic protein CCL25 in periportal endothelial cells in PSC. This correlates with the amount of α4β7$^+$CCR9$^+$ effector T cells, constituting approximately 20% of liver-infiltrating lymphocytes in patients with PSC.[11] In addition, CCL28 is upregulated not only in the portal endothelium but also in the inflamed colon, triggering the arrest of α4$^+$β7$^+$ lymphocytes.[12] Vascular cell adhesion protein (VCAM)-1 expression by cholangiocytes furthermore promotes the survival of intrahepatic α4β7 expressing T lymphocytes that perpetuate the ongoing hepatic inflammation in PSC.[13] These findings implicate that α4β7$^+$CCR9$^+$ effector T cells from the inflamed intestine in UC home to the liver and perpetuate immune-mediated hepatic inflammation. The mechanism of T-cell trafficking to drive PSC was enforced by sequencing data of the TCRβ repertoire, where memory T cells of common clonal origin were detected in paired gut and liver samples of patients with PSC/IBD, indicating that memory T cells driven by shared antigens are present in the gut and liver of patients with PSC/IBD[14] . However, aberrant hepatic recruitment of gut-derived T cells is not confined to PSC but appears to be a general feature of other chronic liver diseases as well, since it could be shown that aberrant hepatic expression of MAdCAM-1, CCL25 and subsequent infiltration of α4β7 and CCR9 expressing T cells into the liver is a common feature of chronic liver diseases.[15] These findings suggest that altered trafficking of lymphocytes cannot be regarded as the sole cause of PSC development. Moreover, a recent trial did not find a biochemical response in patients with PSC/IBD on application of the α4β7-integrin antibody vedolizumab, which however showed good efficacy in controlling intestinal inflammation in the treated patients,[16] suggesting that trafficking of mucosal effector T cells to the liver is not critically dependent on α4β7. Importantly, impairment of peripheral and intrahepatic Treg frequencies has been reported to be involved in PSC, providing a rational therapeutic concept for the transfer of Treg cells in this disease. Specifically, a significantly decreased peripheral Treg frequency in the blood of patients with PSC compared with the frequencies in healthy subjects and patients with primary biliary cholangitis (PBC) has been reported.[8] In addition, intrahepatic FOXP3$^+$ cell numbers were significantly decreased in patients with PSC compared with patients with PBC taken at the time of diagnosis, and there might even be impaired functionality of blood Tregs in patients with PSC, as they contained significantly less IL-10 when compared with healthy subjects.[8]

Here, the observed reduction of ALP serum levels up to 55% at week 4 after adoptive Treg transfer is consistent with the idea that the observed ALP reduction is a biological effect induced by the Treg transfer, as the natural history of PSC is usually associated with stable or increasing ALP levels over time. This lack of natural disease improvement was recently confirmed in a clinical trial, investigating the role of 24-norUrsodeoxycholic acid (norUDCA) in patients with PSC, demonstrating that the patients receiving placebo had on average a 1.2% increase of ALP over 12 weeks.[17] The observation that Treg-induced UC effects are long-lasting and that the Treg-induced PSC effects are transient is intriguing and suggests that repetitive adoptive Treg transfers may be necessary to induce long-lasting remission in PSC. The time-limited effect and loss-of-response on therapy may be explained by a reduced survival capacity of the transferred Tregs. A phase I study that investigated the administration of non-radioactively labelled Tregs in patients with type 1 diabetes reported that only 25% of the transferred cells were retained after 90 days, although a small signal could still be detected up to 1 year, suggesting the long-term survival of a small proportion of the transferred Tregs.[18] Further studies with labelled Treg cells are needed to define their persistence in the

Gut: first published as 10.1136/gutjnl-2022-327075 on 15 April 2022. Downloaded from http://gut.bmj.com/ on October 20, 2023 by guest. Protected by copyright.

tissue of interest. Additional studies should also exclude potential loss of phenotype and function of the Tregs over time, which might also contribute to the transient clinical effectiveness after adoptive transfer.

Limitations of this report include the presentation of a single case, and larger studies will be needed to confirm the efficacy and safety of an autologous Treg transfer in patients with UC and PSC. Additionally, this study did not address the efficacy of a Treg transfer in maintaining response to treatment. However, as early response is the best available predictor for long-term outcomes in UC, recorded efficacy might be an important signal of the potential of Treg transfer for long-term disease control. Further trials with repetitive Treg transfers are required for confirmation. Furthermore, the increase of intestinal mucosal Treg cells after Treg transfer does not necessarily prove migration of the transferred cells to the gut but could be due to local Treg expansion in the tissue. Thus, verification of gut homing of transferred T cells is an important point for future studies on Treg transfer in UC, which could be addressed by administration of labelled Treg cells.

To the best of our knowledge, this is the first report showing improvement of UC and associated PSC after a single infusion of autologous ex vivo expanded polyclonal Tregs. Our data show that Treg therapy may induce clinical, biochemical, endoscopic and histological responses in UC and a marked biochemical response in PSC. Given the role of Tregs in a variety of immune-mediated diseases, adoptive transfer of autologous ex vivo expanded Treg cells may have wide therapeutic application in chronic inflammatory disorders associated with an imbalance between effector and Treg subsets.

Author affiliations
[1]Department of Dermatology, Erlangen University Hospital, Erlangen, Germany
[2]Deutsches Zentrum für Immuntherapie (DZI), Erlangen, Germany
[3]Department of Medicine 1, Gastroenterology, Endocrinology and Pneumology, Erlangen University Hospital, Erlangen, Germany
[4]Medical Department, Division of Gastroenterology, Infectious Diseases and Rheumatology, Charité - Universitätsmedizin Berlin, corporate member of Freie Universität Berlin, Humboldt-Universität zu Berlin, Campus Benjamin Franklin, Berlin, Germany
[5]Department of Gastroenterology, University Hospital Augsburg, Augsburg, Germany
[6]Institute of Pathology, Erlangen University Hospital, Erlangen, Germany
[7]Department of Transfusion Medicine, Erlangen University Hospital, Erlangen, Germany

Contributors CV, DS, MR, MW, MK and BS-T manufactured and released the investigational medical product. FV, SZ, MG, HK, JW; TR, AH, ES, BS and HH collected and analysed the data. CV, RA, GS and MFN were involved in the development and conceptual design of the research project. CV, RA and MFN initiated the clinical trial. CV and RA drafted the manuscript with the help of MFN. All authors critically revised the manuscript. CV serves as the guarantor responsible for the overall content of this manuscript.

Funding This study is supported by the German Research Foundation (DFG) with a grant to Caroline Voskens and Markus Neurath (SFB/TransRegio 241 Project C04).

Competing interests GS is the inventor of granted patents related to the manuscript (publication number EP 1379625, CD4+CD25+ regulatory T cells from human blood).

Patient and public involvement Patients and/or the public were not involved in the design, conduct, reporting or dissemination plans of this research.

Patient consent for publication Not applicable.

Ethics approval This study involves human participants and was approved by the ethics committee of Friedrich-Alexander University Erlangen-Nürnberg (number 417_19 Az). The participants gave written informed consent to participate in the study before trial inclusion.

Provenance and peer review Not commissioned; externally peer reviewed.

Data availability statement All data relevant to the study are included in the article or uploaded as supplementary information. Not applicable.

Supplemental material This content has been supplied by the author(s). It has not been vetted by BMJ Publishing Group Limited (BMJ) and may not have been peer-reviewed. Any opinions or recommendations discussed are solely those of the author(s) and are not endorsed by BMJ. BMJ disclaims all liability and responsibility arising from any reliance placed on the content. Where the content includes any translated material, BMJ does not warrant the accuracy and reliability of the translations (including but not limited to local regulations, clinical guidelines, terminology, drug names and drug dosages), and is not responsible for any error and/or omissions arising from translation and adaptation or otherwise.

Open access This is an open access article distributed in accordance with the Creative Commons Attribution Non Commercial (CC BY-NC 4.0) license, which permits others to distribute, remix, adapt, build upon this work non-commercially, and license their derivative works on different terms, provided the original work is properly cited, appropriate credit is given, any changes made indicated, and the use is non-commercial. See: http://creativecommons.org/licenses/by-nc/4.0/.

ORCID iDs
Caroline Voskens http://orcid.org/0000-0001-9398-005X
Sebastian Zundler http://orcid.org/0000-0003-0888-2784
Britta Siegmund http://orcid.org/0000-0002-0055-958X
Raja Atreya http://orcid.org/0000-0002-8556-8433
Markus F Neurath http://orcid.org/0000-0003-4344-1474

REFERENCES

1 Neurath MF. Cytokines in inflammatory bowel disease. *Nat Rev Immunol* 2014;14:329–42.
2 Rubtsov YP, Rasmussen JP, Chi EY, *et al*. Regulatory T cell-derived interleukin-10 limits inflammation at environmental interfaces. *Immunity* 2008;28:546–58.
3 Murai M, Turovskaya O, Kim G, *et al*. Interleukin 10 acts on regulatory T cells to maintain expression of the transcription factor FOXP3 and suppressive function in mice with colitis. *Nat Immunol* 2009;10:1178–84.
4 Griseri T, Asquith M, Thompson C, *et al*. Ox40 is required for regulatory T cell-mediated control of colitis. *J Exp Med* 2010;207:699–709.
5 Fantini MC, Becker C, Tubbe I, *et al*. Transforming growth factor beta induced Foxp3+ regulatory T cells suppress Th1 mediated experimental colitis. *Gut* 2006;55:671–80.
6 Wiesinger M, Stoica D, Roessner S, *et al*. Good manufacturing practice-compliant production and lot-release of *Ex Vivo* expanded regulatory t cells as basis for treatment of patients with autoimmune and inflammatory disorders. *Front Immunol* 2017;8:1371.
7 Lazaridis KN, LaRusso NF. Primary sclerosing cholangitis. *N Engl J Med* 2016;375:1161–70.
8 Sebode M, Peiseler M, Franke B, *et al*. Reduced FOXP3(+) regulatory T cells in patients with primary sclerosing cholangitis are associated with IL2RA gene polymorphisms. *J Hepatol* 2014;60:1010–6.
9 Voskens CJ, Stoica D, Roessner S, *et al*. Safety and tolerability of a single infusion of autologous ex vivo expanded regulatory T cells in adults with ulcerative colitis (ER-TREG 01): protocol of a phase 1, open-label, fast-track dose-escalation clinical trial. *BMJ Open* 2021;11:e049208.
10 Desreumaux P, Foussat A, Allez M, *et al*. Safety and efficacy of antigen-specific regulatory T-cell therapy for patients with refractory Crohn's disease. *Gastroenterology* 2012;143:1207–17.
11 Eksteen B, Grant AJ, Miles A, *et al*. Hepatic endothelial CCL25 mediates the recruitment of CCR9+ gut-homing lymphocytes to the liver in primary sclerosing cholangitis. *J Exp Med* 2004;200:1511–7.
12 de Krijger M, Visseren T, Wildenberg ME, *et al*. Characterization of gut-homing molecules in non-endstage livers of patients with primary sclerosing cholangitis and inflammatory bowel disease. *J Transl Autoimmun* 2020;3:100054.
13 Afford SC, Humphreys EH, Reid DT, *et al*. Vascular cell adhesion molecule 1 expression by biliary epithelium promotes persistence of inflammation by inhibiting effector T-cell apoptosis. *Hepatology* 2014;59:1932–43.
14 Henriksen EKK, Jørgensen KK, Kaveh F, *et al*. Gut and liver T-cells of common clonal origin in primary sclerosing cholangitis-inflammatory bowel disease. *J Hepatol* 2017;66:116–22.
15 Graham JJ, Mukherjee S, Yuksel M, *et al*. Aberrant hepatic trafficking of gut-derived T cells is not specific to primary sclerosing cholangitis. *Hepatology* 2022;75:518–30.
16 Lynch KD, Chapman RW, Keshav S, *et al*. Effects of Vedolizumab in patients with primary sclerosing cholangitis and inflammatory bowel diseases. *Clin Gastroenterol Hepatol* 2020;18:179–87.
17 Fickert P, Hirschfield GM, Denk G, *et al*. norUrsodeoxycholic acid improves cholestasis in primary sclerosing cholangitis. *J Hepatol* 2017;67:549–58.
18 Bluestone JA, Buckner JH, Fitch M, *et al*. Type 1 diabetes immunotherapy using polyclonal regulatory T cells. *Sci Transl Med* 2015;7:ra189.

Gut: first published as 10.1136/gutjnl-2022-327075 on 15 April 2022. Downloaded from http://gut.bmj.com/ on October 20, 2023 by guest. Protected by copyright.

BMJ Publishing Group Limited (BMJ) disclaims all liability and responsibility arising from any reliance placed on this supplemental material which has been supplied by the author(s)

Supplemental Material

Supplemental figure 1

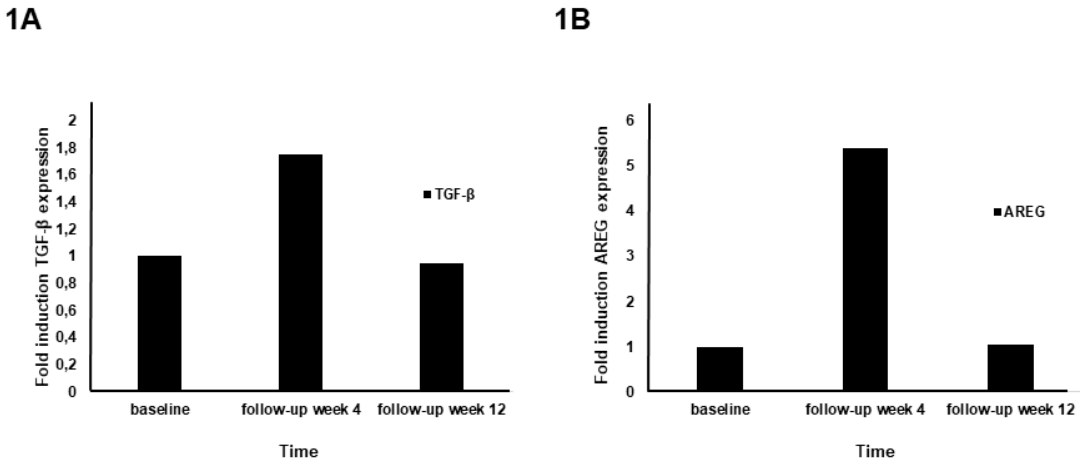

Supplemental figure 1. Adoptive Treg transfer is associated with enhanced TGF-β expression and tissue repair. mRNA expression levels of TGF-β **(A)** and amphiregulin **(B)** were measured by qRT-PCR and normalized to the housekeeping gene HPRT in gut biopsies derived before adoptive Treg transfer (baseline) and 4 weeks and 12 weeks after adoptive Treg transfer. TGF-β, transforming growth factor beta; AREG, amphiregulin.

Voskens C, *et al. Gut* 2022;0:1–5. doi: 10.1136/gutjnl-2022-327075

BMJ Publishing Group Limited (BMJ) disclaims all liability and responsibility arising from any reliance placed on this supplemental material which has been supplied by the author(s)

Supplemental table 1 Lot-release of the Treg product intended for clinical use

Parameter				**Specification**
Cell count	Cell count alive/ml	8.44	X 10^6/ml	≥ 5.0
Vitality	Cell count alive/dead	89.7	%	≥ 75
Phenotype	$CD4^+$	98.9	%	≥ 90
	$CD25^+$	85.1	%	≥ 80
	CD127+	1.4	%	≤ 10
	$CD4^+CD25^+CD127^{low/-}$	81.6	%	≥ 70
	$CD8^+$	0.0	%	≤ 0.5
	$CD19^+$	0.0	%	≤ 1.0
	$CD56^+$	0.0	%	≤ 1.0
Suppression	Tresp+Treg (1+1)	99.6	%	≥ 80
	Tresp+Treg (5+1)	96.7	%	≥ 60
	Tresp+Treg (10+1)	87.3	%	≥ 50
Expander beads	Remaining bead count	< 400	n/100 x 10^6	< 1000
Sterility	Microbiological growth	negative	-	negative
	Endotoxin	< 0.75	IU/ml	< 5
	Mycoplasma DNA	negative	-	negative

Voskens C, *et al. Gut* 2022;0:1–5. doi: 10.1136/gutjnl-2022-327075

BMJ Publishing Group Limited (BMJ) disclaims all liability and responsibility arising from any reliance placed on this supplemental material which has been supplied by the author(s)

Supplemental table 2 Previous ulcerative colitis related medications

Previous therapies	Duration of treatment	Reason for discontinuation
Azathioprine	2007-2016	Loss of response
Golimumab	2017-2018	Severe skin allergic reactions
Vedolizumab	2018-2019	Non-response
Ustekinumab	2019-2021	Non-response

Voskens C, *et al. Gut* 2022;0:1–5. doi: 10.1136/gutjnl-2022-327075

BMJ Publishing Group Limited (BMJ) disclaims all liability and responsibility arising from any reliance placed on this supplemental material which has been supplied by the author(s)

Supplemental table 3 Concomitant medication during the study

Concomitant therapies	Dose
5-aminosalicylic acid	4 g / day
Ursodeoxycholic acid	1 g / day

Voskens C, *et al. Gut* 2022;0:1–5. doi: 10.1136/gutjnl-2022-327075

BMJ Publishing Group Limited (BMJ) disclaims all liability and responsibility arising from any reliance placed on this supplemental material which has been supplied by the author(s)

Supplemental table 4 Clinical markers during the study

	Baseline	Treg transfer	Follow-up week 2	Follow-up week 4	Follow-up week 8	Follow-up week 12
Mayo Score SF	2	3	3	2	2	1
Mayo Score RB	1	1	0	0	0	0
PGA	2	3	1	2	0	1
Partial Mayo Score	5	7	4	4	2	2

SF= Stool frequency; RB= Rectal bleeding; PGA= Physician Global Assessment

Voskens C, *et al. Gut* 2022;0:1–5. doi: 10.1136/gutjnl-2022-327075

BMJ Publishing Group Limited (BMJ) disclaims all liability and responsibility arising from any reliance placed on this supplemental material which has been supplied by the author(s)

Supplemental table 5 **Laboratory parameters**

Parameter	normal range	baseline	Follow-up week 2	Follow-up week 4	Follow-up week 12
Calprotectin	0 - 50 µg/g	5637.0	2325.6	2925.0	3029.9
Leucocytes	(4 - 11) x 10e3/µl	6.69	6.17	7.64	5.21
Haemoglobin	(11.8 - 15.5) g/dl	14.2	13.3	13.3	13.6
Thrombocytes	(160 - 400) x 10e3/µl	411	392	392	347
neutrophils	%	69.0	52.2	57.4	53.9
eosinophils		2.1	1.6	1.7	1.7
basophils		0.9	1.1	0.8	1.0
lymphocytes		18.4	32.1	29.2	29.4
monocytes		9.6	13.0	10.9	14.1
potassium	(3.6 - 4.8) mmol/l	4.3	4.0	4.1	4.3
sodium	(135 - 145) mmol/l	138	136	139	140
creatin-kinase	(< 170) U/l	39	103	26	35
AST	(< 35) U/l	176	91	63	158
ALT	(< 35) U/l	165	76	57	152
LDH	(< 250) U/l	177	102	110	167
Gamma-GT	(< 40) U/l	938	679	289	859
alk. Phosphatase	(35 - 105) U/l	1089	811	490	1065
Glucose	(70 - 110) mg/dl	118	80	75	86
Calcium	(2.20 - 2.65) mmol/l	2.28	2.31	2.18	2.28
urea	(17 - 43) mg/dl	23	17	17	20
Kreatinin	(0.51 - 0.95) mg/dl	0.64	0.68	0.63	0.71
Bilirubin total	(< 1.1) mg/dl	1.8	1.5	1.1	1.5
Magnesium	(0.7 - 1.1) mmol/l	0.8	0.8	0.8	0.8
Albumin	(35 - 55) g/l	35.7	37.2	34.7	38.3
CRP	(< 5) mg/l	16.4	8.0	9.8	14.4

Voskens C, *et al. Gut* 2022;0:1–5. doi: 10.1136/gutjnl-2022-327075