

Progress report

Colonoscopy

In the three years since fiberoptic colonoscopes became generally available there have been a number of reports¹⁻¹² and reviews¹³⁻¹⁴ describing the clinical value of colonoscopy. The technical difficulties and time involved in the procedure, the initial expense of the instruments, and the need for x-ray facilities have discouraged many centres from becoming involved in colonoscopy. Colonoscopy and biopsy has, however, been shown to be more accurate in diagnosis than barium enema^{8,9,12} and to remove the need for laparotomy in many cases; colonoscopic polypectomy^{15,16,17,18,19} is now a practicable alternative to abdominal operation. It has therefore become mandatory on economic as well as clinical grounds that colonoscopy should be generally available, but because some technical difficulties remain it is also important that its indications, limitations, and relationship to radiological methods are understood.

Much of the literature on colonoscopy has to date been in obscure or specialized journals, individual experience has been small, and variations in technique have been considerable. This review is therefore augmented by personal contacts with colonoscopists throughout the world and by experience of over a thousand colonoscopies. Because of the technical problems involved practical aspects of the procedure are covered in some detail.

Instruments

An ACMI fiberoptic colonoscope was produced in 1963²⁰ but the first instruments with manoeuvrable tips appeared in Japan in 1966⁷ and in Europe in 1969-1970 as the fibresigmoidoscopes of Olympus (CF-SB), Machida (FSS), and subsequently ACMI (Overholt 9000)—all now outdated. The current instruments have four-way tip angulation, air, water, and suction controls, and biopsy facilities but may be 'medium' (105-110 cm: Olympus CF-MB; Machida, FSM, ACMI 9000P) or 'long' colonoscopes (165-185 cm: Olympus CF-LB; ACMI 9000PL, Machida FCS). Fuller details are given elsewhere²¹. Of the commonly used colonoscopes the shorter instruments have proved easier to use, but limit the examination to the left colon. The ACMI instruments as a whole are more robust while those from Olympus have more convenient controls and sharper optics.

A new generation of 'operating colonoscopes' is now being presented with either a single large channel, snare deflector, and CO₂ control (Olympus CF-MB₂, CF-LB₂) or two channels and integral stiffness control (ACMI F9A). Wolf, Saas-Wolf, and Storz endoscopes are not yet in general use.

A wide range of essential accessories is available including fiberoptic 'teaching aids', excellent spiked biopsy forceps (ACMI), cytology brushes (ACMI, Olympus), polypectomy snares (ACMI, Olympus, Storz), and the new stiffening tubes described later. Adaptors are available to interconnect ACMI instruments with Olympus light sources and cameras and it is hoped

that similar devices will be available from other firms so that different endoscopes can be used without duplication of supporting equipment.

A colonoscope is subject to forces, including torsional movements, which are not encountered in upper gastrointestinal endoscopy and in some cases if the examination is not to be abandoned the instrument is stressed nearly to its limit. Even with experience a long colonoscope is unlikely to reach 150 examinations without major repairs and it should be assumed that during a working life of, at the most, 200 examinations a repair bill of up to one third the cost of the instrument will be incurred.

Colonoscopy Technique

BOWEL PREPARATION

In a few cases where very limited examination is required, preparation may be restricted to a single enema, as for rigid proctosigmoidoscopy. If diverticular disease or stricturing is present, however, full preparation is needed to achieve a clean bowel. Preparation of the whole colon sufficient to give a perfect result for the endoscopist requires drastic treatment of the patient and an acceptable compromise is necessary. Whichever regime is chosen, the patient must be given fluid diarrhoea and the bowel then fully evacuated by an enema given one to two hours before examination. Dietary measures are helpful with intake limited to clear fluids for one to two days before examination. With a five to seven day fluid regime it is possible to avoid purgation altogether⁹. Iron preparations should not be taken for three days before colonoscopy, but other medication should continue normally.

The aperient most commonly used is castor oil (30-60 ml)^{2,5,7,11,12,22} but senosides (Senokot DX, Xprep)³, bisacodyl (Dulcolax)⁸, magnesium citrate⁹, magnesium sulphate⁶, or liquid paraffin² have all been found effective. In active inflammatory bowel disease drastic purgatives such as castor oil should not be used. One or more enemas are given, ranging from tap water^{2,9}, saline⁸, or hypertonic solutions⁶ to purgative agents such as oxyphenisatin (Veripaque)¹¹ or bisacodyl (Dulcolax)⁸. Oxyphenizatin enemas do not cause jaundice, as has been reported after oral administration. The most important part of bowel preparation is that the nurse should check with the patient that clear fluid is being returned before colonoscopy begins. 'Successful' preparation has been claimed in anything up to 96% of cases² but in the spirit of compromise the endoscopist is sometimes forced to accept less than the ideal providing that solid faeces is not present.

MEDICATION

Even in the best hands colonoscopy is occasionally a traumatic procedure. Some limited examinations may prove unexpectedly painful and yet total colonoscopy is possible in other patients without any sedation. This unpredictability and the need to provide analgesia rather than sedation alone has led most colonoscopists to use a combination of agents, often including diazepam (Valium) 5-20 mg^{9,11} or haloperidol (Serenace)³ given intramuscularly or intravenously, and analgesics such as inhaled nitrous oxide (Entonox)²³, or morphine or pethidine (Dolantin, Demerol) 25-50 mg intravenously^{6,11}. The sigmoid colon is the most common site of pain and it is therefore usually preferable to administer these agents *before* starting the examination in a moderate dose related to the patient's age, size, and clinical

state. Some endoscopists^{24,25} employ no routine sedation, stressing the importance of pain as a warning sign to the endoscopist, but with the correct level of sedation the patient can still complain of any undue pain without becoming distressed by it. The majority of patients undergoing more than very limited colonoscopy should probably have an intravenous dose of an analgesic such as pethidine, supplemented by a small dose of intravenous diazepam. Since the combined effect of these drugs and the autonomic assault of a difficult colonoscopy may cause vomiting or hypotension in a few cases, full facilities for resuscitation should be available in the room.

There will occasionally be a place for colonoscopy under general anaesthetic, particularly in children and those with a markedly low pain threshold. Although in one centre⁵ colonoscopy has been routinely performed under anaesthesia this is generally considered both unnecessary and inadvisable since elsewhere there has been a high incidence of bowel perforation under general anaesthetic. Colonoscopy is, however, technically easy during laparotomy²⁶ providing that the abdominal incision is extended so as to allow the surgeon to guide the instrument round flexures and that rigorous bowel preparation has been employed.

The routine use of anticholinergics such as hyoscine-n-butyl bromide (Buscopan) or atropine has been advocated^{6,27} but probably makes the bowel atonic and more difficult to intubate. In the presence of diverticular disease or pronounced 'spastic' contractions hyoscine-n-butyl bromide 40 mg intravenously can make full inspection of the lumen easier.

EXAMINATION

Before examination the colonoscope controls and light source should be checked and the flexible part of the biopsy channel lubricated with silicone liquid. If the stiffening tube is to be used it is placed over the proximal end of the instrument shaft before starting. A few drops of concentrated peppermint oil (BP) added to the suction bottle will stop odours.

X-ray fluoroscopy using image intensification should be used during colonoscopy^{8,11,13}. While some colonoscopists have claimed it to be unnecessary^{3,15,28}, the use of fluoroscopy allows the examination to be made more quickly and accurately with less trauma to the patient and instrument. Limited colonoscopy is possible without fluoroscopy, just as limited examination of the chest is possible without a stethoscope, but is not the ideal. Because of the short mechanical life span of a colonoscope, damage to the fibre bundle by irradiation during fluoroscopy should not be a problem provided that screening time is minimized by using bursts of only one to two seconds and a total of less than 30-60 seconds per examination. With such intermittent screening we found that the instrument and patient receive less irradiation during colonoscopy than during the exposure of a single x-ray plate. Using continuous screening the bundle can become yellow and unusable in as few as 50 colonoscopies.

The patient is placed on the x-ray table or radiolucent trolley in a comfortable left lateral position and the instrument is inserted after rectal examination with generous lubrication. Thereafter there are two methods of handling the colonoscope. Either the controls can be worked with both hands, with an assistant viewing down a 'teaching aid' and inserting, withdrawing, and rotating the shaft of the instrument, or the endoscopist uses his left hand to control the push-buttons and provide up and down movement of the

instrument tip, and his right hand to manipulate the shaft. The 'single-handed' method is more difficult to master but eventually provides better and quicker control. Whichever method is used the object is to attempt to pass the tip down the centre of the lumen at all times, withdrawing the instrument to regain the view when it is lost. By careful steering the sigmoid colon can often be made to concertina itself over the instrument and the descending colon is reached directly. Sometimes as the colonoscope is inserted the mucosa is seen to pass by the tip but the lumen cannot be seen, indicating that a sigmoid loop is being formed (fig 1). 'Blind' insertion is safe providing that the

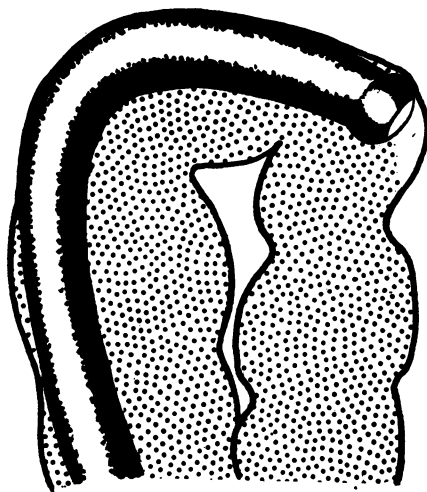


Fig 1 'Blind' insertion of the colonoscope around a loop or flexure.

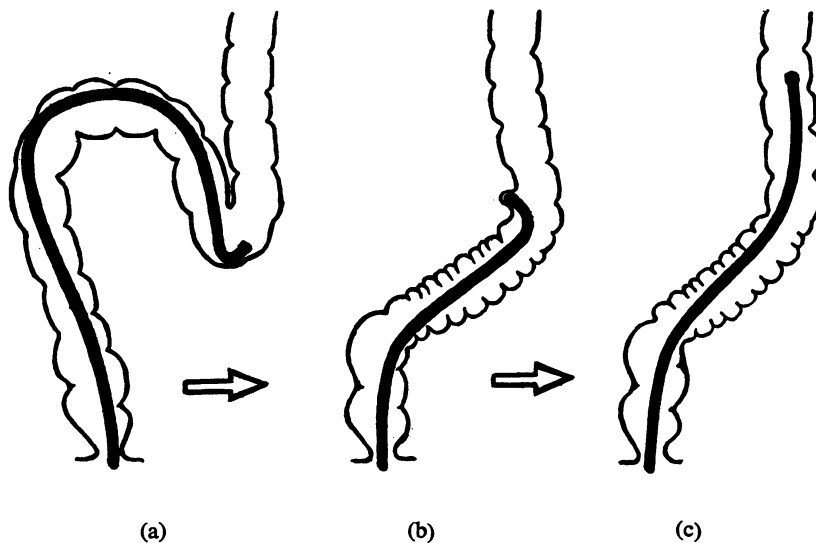


Fig 2 The colonoscope (a) impacted at the sigmoid-descending colon junction, (b) withdrawn to shorten the sigmoid loop, and then (c) re-inserted.

colonoscope is immediately withdrawn when the mucosa stops moving by and whitens, or when the patient complains of pain. If this rule is ignored there is a risk of bowel perforation. 'Blind' insertion should not be attempted in the presence of diverticular disease (see Limitations and Complications).

Once the colonoscope has reached the proximal sigmoid colon if there is difficulty it may be helpful to change the patient from the left lateral to a prone or supine position. This allows fluoroscopy and the very change of position may restore a luminal view. If the tip of the instrument is seen to be impacted in the acutely angled junction of the sigmoid and descending colon (fig 2a) and if simple withdrawal does not straighten the instrument for further insertion²⁹ (fig 2b,c), the 'alpha loop manoeuvre' can be used^{22,30}. In this manoeuvre the colonoscope is withdrawn to 25 cm with the tip slightly hooked at the recto-sigmoid junction (fig 3a) and the shaft of the instrument is then forcibly rotated 180° counterclockwise (fig 3b) until the tip is seen on fluoroscopy to point *away from* the descending colon. The colonoscope is then reinserted steering carefully but maintaining counterclockwise torque, and it will be seen on fluoroscopy to pass in a loop down into the pelvis and then up the descending colon (fig 3c). Once the loop has been successfully formed insertion is easy because there is no point of acute angulation, and although there is sometimes mild discomfort the patient will not experience the severe pain which can be caused by forcing through the sigmoid-descending junction.

Once the splenic flexure is reached, the loop can be straightened out again by withdrawal and 180° clockwise rotation of the whole instrument^{22,30,31}. If the loop tends to re-form it is straightened once again and the stiffening tube³² is inserted over the colonoscope under fluoroscopic control to the upper descending colon to hold the sigmoid colon straight (fig 4). At a later

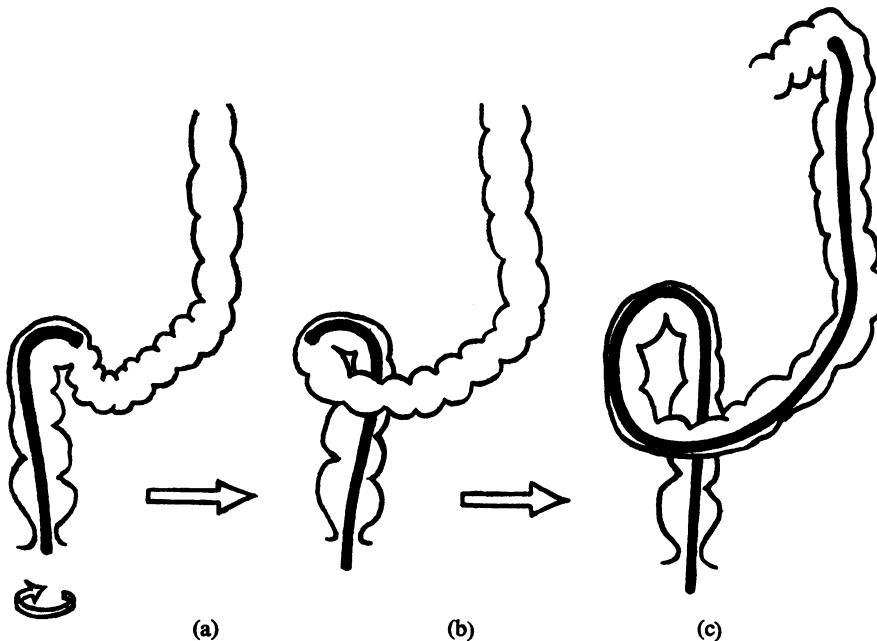


Fig 3 Stages in the 'alpha loop' manoeuvre (see text).

Fig 4 *The stiffening tube inserted over the colonoscope.*

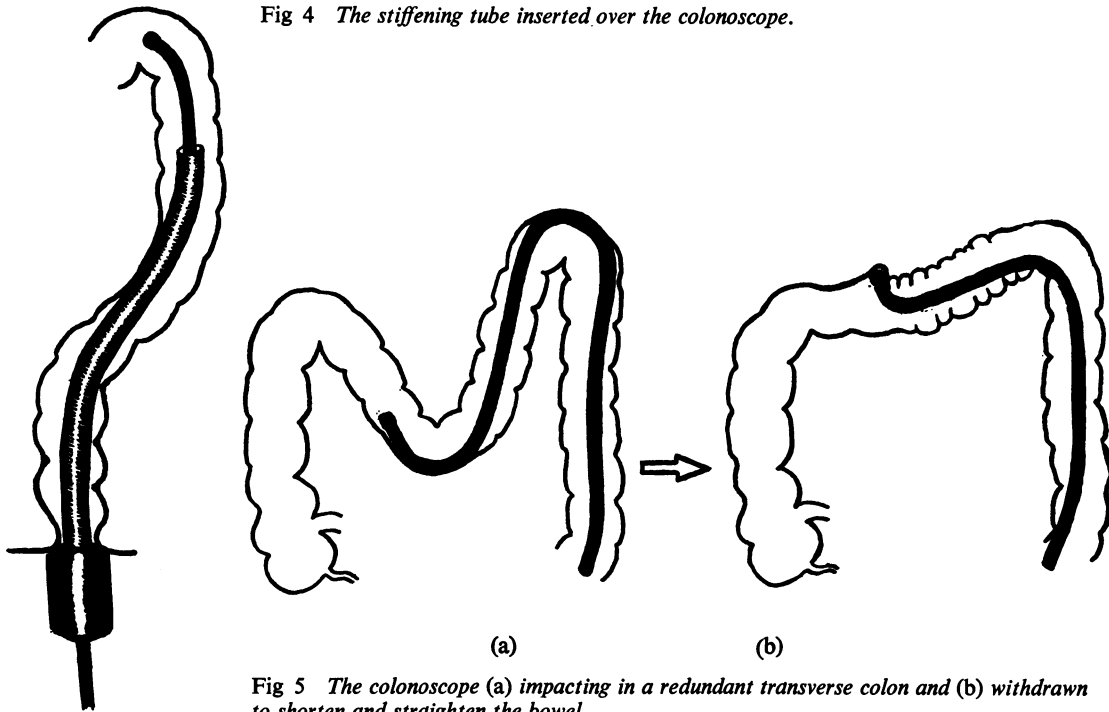


Fig 5 *The colonoscope (a) impacting in a redundant transverse colon and (b) withdrawn to shorten and straighten the bowel.*

stage of the examination the colonoscope can even be completely withdrawn and replaced through this tube during the removal of multiple polyps or in order to change instruments. The only disadvantage of the stiffening tube is that it must be continuously held by an assistant to prevent its removal during withdrawal manoeuvres of the colonoscope. Spring steel stiffening wires^{11,33,34} are practically outdated by the stiffening tube, but can be helpful when the transverse colon is redundant. The new ACMI F9A colonoscope will have an integral 'stiffenable' device. A sigmoid loop which is not straightened out will dissipate the force of insertion so that it is difficult to advance the tip and its mobility is greatly reduced. The colonoscopist should therefore be familiar with straightening manoeuvres, and employ *x-ray* fluoroscopy to achieve them.

In the transverse colon or at the hepatic flexure the instrument tip may sometimes become impacted in a redundant loop or fold and fluoroscopy is again useful to allow the tip to be pointed in the correct direction, the air-filled bowel being visible on the screen. In some patients with a redundant transverse colon the instrument may loop down towards the pelvis and make it difficult to reach the hepatic flexure (fig 5a). By hooking the tip and withdrawing the instrument³¹ this loop can be straightened out (fig 5b), and, because of the springiness of the colonoscope, the tip may actually advance in the process. It may be necessary to repeat this procedure several times, sometimes using abdominal palpation or a change of the patient's position, before the hepatic flexure is reached and the tip hooked round. If the colonoscope is then straightened out a final time the tip will usually spring round into the ascending colon and can be advanced to the caecum.

Endoscopically it is possible to get some idea of the position of the instrument in the colon from the appearance of the bowel lumen²⁸, even though fluoroscopy is the final arbiter. The descending colon appears as a long straight with circular haustrations, ending abruptly at the acute splenic flexure. The transverse colon has triangular haustrations, and the hepatic flexure has sharp infoldings and often shows a blue 'stain' where it overlies the liver. Once the caecum is reached a red transilluminating glow may be seen in the right iliac fossa, but this can also be produced when there is a deeply looped transverse colon.

The ileocaecal valve is variable in appearance, sometimes being shallow and patent, sometimes polypoid with a contracted orifice or often hidden behind the large mid-caecal fold. To pass the valve either its position must be gauged and the instrument tip hooked in the correct direction, or the colonoscope can be inverted at the caecal pole, a view obtained and the instrument withdrawn until the tip enters the ileum. Pentagastrin (Peptavlon) or metaclopramide (Maxolon) given intravenously may provoke efflux and identify the valve. It is rarely possible to examine more than 20 cm of the terminal ileum.

Technical Results

Although some of the earliest reports^{3,35} indicated difficulty in even reaching the proximal sigmoid colon with short instruments, subsequently the test of technical skill has been the ability to reach the caecum when necessary. Initial series quoted success rates of between 30 and 50%^{5,9,22,30} but more recently full examination has been shown to be possible in 95% or more of cases^{9,11,34}. The best published rate of insertion into the terminal ileum is 66%³⁶ but most experienced endoscopists can now reach the ileum in almost every case if an indication exists to do so. With experience the time taken also decreases and whereas figures have been quoted of up to 30 minutes for insertion to the proximal sigmoid^{2,35} and 40-60 minutes to the caecum^{2,5,11}, it should take less than five minutes to traverse a sigmoid colon unaffected by diverticular disease or adhesions and around 10-25 minutes to reach the caecum. Careful examination of the bowel during withdrawal will at least double this time, and biopsy taking or other operative procedures make it longer still so that an average colonoscopy can be expected to occupy approximately an hour.

As well as acquiring manipulative skill with the instrument, the colonoscopist should be able to take adequate biopsies speedily and often. The size of biopsies is mainly dependent on the length of the forceps jaws, the ACMI spiked forceps being the best in this respect, but forceps should be pressed firmly into the mucosa to get the largest bite. In strictured areas and around bends it may be difficult to obtain satisfactory biopsies and in these areas cytology can be useful.

Indications for Colonoscopy

There are a number of practical and theoretical reasons why colonoscopy is unsuited to compete with the barium enema as a routine screening procedure for all patients. Obviously fluid contrast medium will flow to the proximal colon, even though narrowed areas, quickly and without pain—

which cannot be said of the colonoscope. X-ray film provides a permanent image of the whole bowel, whereas the colonoscope gives a transient view of small areas (unless cine film or video-recording is used). An x-ray department has also evolved the supporting staff, facilities, and finance necessary to provide an overall service which the ordinary gastroenterologist or surgeon will at present find difficult to match. The particular virtues of the fibroendoscope, however, are its close-up colour view and the ability to take biopsies which make it an ideal partner to the barium enema *in selected cases*. In general the indications for colonoscopy may be classified under five headings: (1) abnormal or equivocally abnormal areas demonstrated on barium enema; (2) normal barium enema but unexplained symptoms such as rectal bleeding, diarrhoea, abdominal pain, etc; (3) assessment of some cases of inflammatory bowel disease; (4) postoperative, for examination of an anastomosis or through a colostomy or ileostomy; (5) operative for polypectomy, etc.

There are few contraindications to colonoscopy. In acute toxic conditions of the bowel such as severe ulcerative, Crohn's, ischaemic or irradiation colitis, or in the presence of peritonitis, colonoscopy is likely to lead to bowel perforation. Diverticular disease, stricturing, or previous pelvic surgery may make effective colonoscopy difficult (see Limitations and Complications).

Results

It is difficult to make any objective assessment of the results of colonoscopy from published series since case selection depends largely on barium enemas, standards of which vary from centre to centre. Colonoscopy excels in certain fields.

ABNORMAL AREAS ON BARIUM ENEMA

The endoscopist can discriminate between faeces and cancer or between spasm and stenosis with a facility sometimes denied the radiologist. He can confirm or exclude the possibility of carcinoma by inspection and biopsy where laparotomy or bowel resection would have been indicated previously. The radiologist should consider asking for colonoscopy when reporting 'doubtful' areas.

RECTAL BLEEDING, ETC, NORMAL BARIUM ENEMA

Even when the barium enema is reported as normal, colonoscopy may discover lesions in up to 26.5%⁹ of cases where there are symptoms or signs suggesting disease. The commonest finding is of adenomatous polyps in the sigmoid colon, but unsuspected (often resectable)³⁷ cancer has been found in 7% of the cases in one large series⁹, and this alone would justify colonoscopy as a diagnostic procedure. 'X-ray negative' colitis^{9,38,39} or haemangiomas⁴⁰ have been described as the cause of unexplained bleeding.

INFLAMMATORY BOWEL DISEASE

The majority of cases of ulcerative or Crohn's colitis do not require colonoscopy, except where there is a particular clinical or radiological indication. Routine examination of over a hundred patients with chronic total ulcerative colitis in our centres has yielded no evidence of malignancy or precancerous change in any of 1500 mucosal biopsies. However, colonoscopy shows that both standard and double-contrast barium enema techniques may seriously

underestimate the extent of ulcerative colitis^{9,39,41}. In 20% of one series of patients with active disease³⁹, total involvement of the colon was proven by colonoscopy when barium enema either suggested distal disease or showed no abnormality at all. On inspection alone the disease may be seen to extend beyond the limit indicated on barium enema, but more commonly it is the colonoscopic biopsies which show obvious abnormality even where the endoscopic and radiological appearances are normal. Only long-term followup will determine whether these patients with 'occult' total colitis have the same prognosis and potential complications as those with total involvement radiologically.

Colonoscopic biopsies of strictures and polyps in chronic inactive ulcerative colitis frequently show no abnormality³⁹, and with this assurance surgery can be avoided. In right-sided colitis or Crohn's disease the involvement of the terminal ileum can be assessed and diagnostic histology obtained.

POSTOPERATIVE

The radiological assessment of an irregular bowel anastomosis is difficult and colonoscopic biopsies or cytology provide the ideal answer. Patients with colostomies (or those with gross weakness of pelvic floor musculature) may be unable to retain barium and air. Although this is not a routine indication for colonoscopy, examination presents no special difficulty and is surprisingly easy down the stoma.

POLYPECTOMY

Removal of polyps of any size and from any site in the colon is possible using the colonoscope and diathermy snare^{15,16,17,18,19}, and this technique also enables large biopsy samples to be taken from other protuberant lesions such as suspected carcinomas. There are several commercially available snares (Storz, ACMI, Olympus) or a loop can be formed from a bent length of braided wire passed down an insulating tube. Electrical safety precautions must be carefully observed⁴² and flushing of the bowel with an inert gas such as CO₂ is generally considered advisable because of the risk of explosion. In one large series^{18,19} air insufflation has been used but this practice is only defensible if the whole bowel has been completely cleansed of methane-producing organisms.

Once the snare has been closed over a polyp coagulating current is applied until there is visible discolouration of the stalk. No haemorrhage should occur during transection. With very large or sessile lesions there is a greater risk of bowel perforation and the polyp can be removed piecemeal¹⁸ or after injecting submucosal saline solution to reduce heating of the bowel wall¹⁶. Very small polyps can be both biopsied and simultaneously destroyed using insulated forceps⁴³. After transection the polyp must be removed for histological examination either using the snare, a special polyp retrieving forceps⁴⁴ or basket¹⁷ or else by aspiration onto the tip of the colonoscope, which blocks any further view of the bowel. In patients with multiple polyps the colonoscope has usually to be reinserted several times, which prolongs the procedure. With a saline purgative enema 'lost' polyps can be recovered before autolysis.

The only significant complication in each of two series of over 300 polypectomies^{18,45} was a single localized perforation not requiring immediate surgery. In experienced hands colonoscopic polypectomy is a quick and

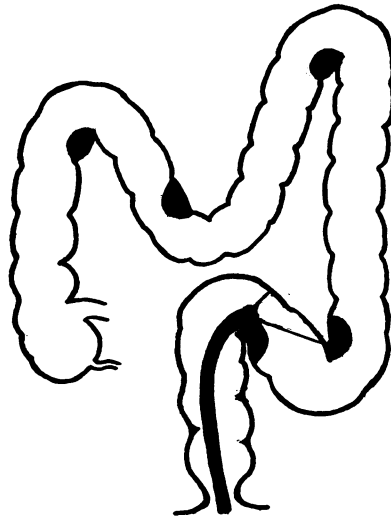


Fig 6 Possible 'blind spots' during colonoscopy.

safe alternative to laparotomy and colotomy—a procedure with significant morbidity and mortality⁴⁶. However, to obtain a full view of a polyp and to snare and retrieve it often requires the utmost in technical skill and an inexperienced endoscopist employing diathermy techniques may not only endanger the patient but also achieve poor results. The corollary is that sometimes a physician or radiologist experienced in colonoscopy may be better suited to undertaking endoscopic polypectomy than a surgeon with knowledge of diathermy but little facility with fiberoptic instruments.

Limitations and Complications

Assuming successful bowel preparation, the colonoscope is capable of giving a perfect detailed view of almost every part of the bowel, although around flexures (fig 6) and behind haustral folds it is possible to miss lesions. Redundant loops which have become shortened by the instrument during insertion spring off the tip on withdrawal and are difficult to examine. The success of examination depends on the technique and obsessional persistence of the colonoscopist, who may need to re-examine one area several times to be sure of a complete view. It is not uncommon to see a lesion during insertion and not to see it on withdrawal, or vice versa.

Where there are fixed loops or bends, as occurs with the adhesions following previous surgery or diverticular disease, it may be impossible to pass the colonoscope. In the presence of tight stenosis a bad view is often obtained and the biopsy forceps may not be able to be inserted in the required direction. In diverticular disease the large muscular folds encountered make it impossible to slide the instrument and once the tip is turned into a fold there is danger of mistaking the orifice of a diverticulum for the bowel lumen (fig 7) and of then insufflating air and causing perforation⁴⁷. Since Olympus instruments generate high air pressures (600-800 cm H₂O) they must be particularly carefully used under these circumstances⁴⁸.

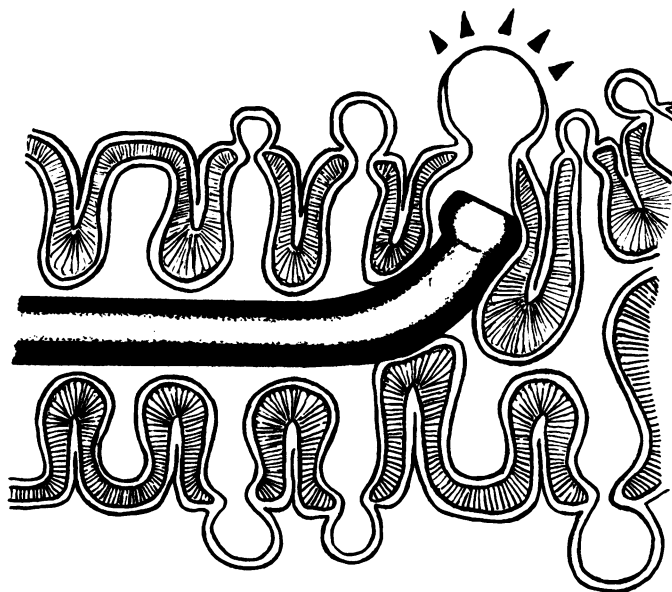


Fig 7 False passage of the colonoscope into a diverticular fold, risking perforation.

A number of perforations are known to have taken place during diagnostic colonoscopy although only few have been reported^{8,9,47,48}. The majority have occurred in the hands of inexperienced operators, especially when using general anaesthesia, when forcing the instrument or in the presence of diverticular or inflammatory disease. During the use of the diathermy snare perforations have also occurred due to full-thickness necrosis of the bowel at the base of the polyp, due to an incompletely closed snare and when the head of the polyp has been allowed to touch the opposite wall of the bowel. Because of the scrupulous bowel cleansing needed for colonoscopy the majority of perforations have apparently been easily managed, surgically or conservatively, but there has been a death following undeclared perforation and consequent peritonitis.

The Relationship of Colonoscopy to Barium Enema

The speed, ease, and overall view of the barium enema have already been stressed. The *x*-ray department of a large hospital may perform 1000 to 2500 examinations of the whole colon annually and a colonoscopy service is unlikely to wish to compete with this. The standard of barium enemas varies, however, from the refined 'Malmö' double-contrast technique^{50,51}, which can demonstrate polyps down to 5 mm diameter, to the other air-contrast or standard barium enema techniques which may miss carcinomas in up to 10% of cases^{52,53}. Bowel preparation before barium enema is not infrequently inadequate with resultant uncertain 'masses'. Both disciplines are, however, debased if colonoscopy is invoked because of bad *x*-ray technique.

In the majority of patients barium enema examination will provide a satisfactory answer and in the minority of cases where the radiologist or clinician requests colonoscopy the value of a good preceding barium enema is to point out the problem areas. If the proximal colon has been properly

outlined it may be possible to perform only a limited examination, which is quicker and less traumatic than a total colonoscopy. Where the patient cannot retain barium (colostomy or incontinence) or where an area of the colon is repeatedly inadequately demonstrated, colonoscopy may help the radiologist. The colonoscopist and radiologist should act in partnership, with colonoscopy reserved as a 'special investigation'.

Organization of Colonoscopy

In general we feel that colonoscopy should initially be confined to regional centres able to provide a full service and having the instruments, manpower, and technical and financial resources to maintain the service. The instruments are difficult to use and fragile, most of the problems and breakages occurring in the early experience of an endoscopist, so that it is logical to designate one or two 'colonoscopists' with a reasonably long or permanent tenure if the technique is to give the best results. Colonoscopy will usually only be a part interest of the individual concerned, but it is sterile to dispute whether a surgeon, physician, or radiologist should be selected providing that he has enthusiasm and enough time.

In setting up colonoscopy provision must be made for supporting nursing, technical, and secretarial services, and also arrangements for bowel preparation, for supervision of day cases, or for overnight stay. X-ray facilities should be arranged, either in the x-ray department or using a small image intensifier. 'Back-up' instruments will be required and as well as capital expenditure reasonably heavy maintenance costs must be expected. The armamentarium should ideally include two long colonoscopes and one medium 'operating' colonoscope, with a 'teaching' attachment and all necessary accessories including diathermy apparatus. As with upper gastrointestinal examinations, colonoscopy is best performed in a properly organized endoscopy room with staff experienced in handling patients and instruments and used to dealing with the problems which may occur with either. Even 'fibre-sigmoidoscopy' may be a prolonged and difficult procedure and anyone thinking of starting colonoscopy with limited time and facilities would be wise to visit an established unit before committing himself.

There is also an urgent need to develop methods, models, and other means for teaching colonoscopy if the present generation of self-taught colonoscopists is to save others the expensive and dangerous mistakes they have made themselves and to encourage an overall high standard of examination.

Costs

It is difficult to give a realistic estimate of the costs of colonoscopy. Instruments and the techniques of using them are improving continuously but the life span of a long colonoscope is still probably around 200 examinations, including major repairs. Breakages of expensive forceps, snares, and other equipment increase the costs further. Only two to three examinations can be performed in a session and salary costs will be high. On the other hand colonoscopy can be performed on an outpatient, day case, or overnight stay basis and may greatly reduce the amount of other investigation, may avoid hospital admission or laparotomy, or make diagnosis (as in colonic cancer) at an early stage where cure is possible. The advent of 'operative' colonoscopy

and polypectomy will both reduce the number of follow-up barium enema examinations and remove the need for laparotomy and colotomy in these cases.

Overall the cost of a colonoscopy is certainly greater than that of a barium enema, but because of the enormous expense of inpatient investigation and of surgery, postoperative care, convalescence, and missed employment, colonoscopy is likely to justify its cost many times over⁵⁴. The gain from early diagnosis is of course incalculable.

Research

As a means of reaching previously inaccessible regions of the bowel and obtaining samples or inserting tubes and probes colonoscopy is a welcome new technique. Histology, electron microscopy, and histochemistry can be applied to tissue samples, chemical or bacteriological techniques to fluid aspirates, and pharmacological, electrical,⁵⁵ or pressure-recording methods to the intact bowel. The first impact may be in the assessment of conditions such as inflammatory bowel disease and precancerous and cancerous conditions, where material for study can be obtained at all stages of the disease without trauma to the patient.

Conclusion

Colonoscopy is a demanding new technique with a remarkable clinical yield in early or more accurate diagnosis. It complements rather than supplants the barium enema, but should stimulate radiologists to improved technique. Colonoscopy will make 'diagnostic' laparotomy unnecessary in many cases and with the use of the diathermy snare allows removal of polyps of all sizes anywhere in the colon without abdominal surgery. The resulting financial saving to the hospital service will greatly outweigh its apparent expense.

Colonoscopy is a safe and acceptable technique in skilled hands, but a potentially traumatic or dangerous one for the inexperienced endoscopist. At present it should be considered as a specialist service to be performed in well organized centres and on selected patients.

We are grateful to Dr Y. Sakai for his help in the preparation of the illustrations for this article.

CHRISTOPHER WILLIAMS AND ROBIN TEAGUE
*St Mark's Hospital, London, and the
Department of Medicine, Royal Infirmary, Bristol*

References

- ¹Berezov, Y. E., Sotnikov, V. N., and Kornilov, Y. M. (1972). Colonoscopy in diagnosing disease of the large intestine (Russian). *Vestn. Akad. med. Nauk.*, 27 (2), 65-69.
- ²Chabanon, R. (1972). La fibro-colonoscopie. *Ann. Gastroent. Hepat.*, 8, 239-244.
- ³Dean, A. C. B., and Shearman, D. J. C. (1970). Clinical evaluation of a new fiberoptic colonoscope. *Lancet*, 1, 550-552.
- ⁴Gregg, J. A., and Garabedian, M. (1971). Colonoscopy. *Surg. Clin. N. Amer.*, 51, 661-665.
- ⁵Hansen, L. K. (1971). Colonoscopy: a study of 50 cases. *Scand. J. Gastroent.*, 6, 687-691.
- ⁶Nagy, G. S. (1973). Fibrecolonoscopy. *Med. J. Aust.*, 1, 378-382.
- ⁷Niwa, H., Utsumi, Y., Nakamura, T., Yoshida, A., Yoshitoshi, Y., Fujino, M., Kaneko, E., Kasumi, A., and Matsumoto, M. (1969). Clinical experience of colonic fiberoscope. *Gastroent. Endosc. (Tokyo)*, 11, 163-173.
- ⁸Overholt, B. F. (1971). Flexible fiberoptic sigmoidoscopy—technique and preliminary results. *Cancer (Philad.)*, 28, 123-126.
- ⁹Teague, R. H., Salmon, P. R., and Read, A. E. (1973). Fiberoptic examination of the colon: a review of 255 cases. *Gut*, 14, 139-142.

- ¹⁰Waye, J. D. (1972). Colonoscopy. *Surg. Clin. N. Amer.*, **52**, 1013-1024.
- ¹¹Williams, C. B., and Muto, T. (1972). Examination of the whole colon with the fiberoptic colonoscope. *Brit. med. J.*, **3**, 278-281.
- ¹²Wolff, W. I., Shinya, H., Geffen, A., and Ozaktay, S. Z. (1972). Colonofiberoscopy: a new and valuable diagnostic modality. *Amer. J. Surg.*, **123**, 180-184.
- ¹³Classen, M. (1971). Fibreendoscopy of the intestines. *Gut*, **12**, 330-338.
- ¹⁴Morrissey, J. E. (1972). Gastrointestinal endoscopy. *Gastroenterology*, **62**, 1241-1268.
- ¹⁵Deyhle, P., Seuberth, K., Jenny, S., and Demling, L. (1971). Endoscopic polypectomy in the proximal colon. *Endoscopy*, **3**, 103-105.
- ¹⁶Ottenjahn, R. (1972). Colonic polyps and colonoscopic polypectomy. *Endoscopy*, **4**, 212-216.
- ¹⁷Williams, C. B., Muto, T., Rutter, K. R. P. (1973). Removal of polyps with fiberoptic colonoscope: a new approach to colonic polypectomy. *Brit. med. J.*, **1**, 451-452.
- ¹⁸Wolff, W. I., and Shinya, H. (1973). Polypectomy via the fiberoptic colonoscope. *New Engl. J. Med.*, **288**, 329-332.
- ¹⁹Wolff, W. I., and Shinya, H. (1973). New approaches to the management of colon polyps. *Advanc. Surg.*, in press.
- ²⁰Turell, R. (1963). Fiberoptic coloscope and sigmoidoscope. *Amer. J. Surg.*, **105**, 133-136.
- ²¹Cotton, P. B., and Williams, C. B. (1972). Fiberoptic instruments for gastro-intestinal endoscopy. *Brit. J. hosp. Med.*, **8**, 35-44. (Equipment Suppl., Nov.).
- ²²Matsunaga, F., Tajima, T., Toda, S., Maeda, Y., Sato, H., Munakata, A., and Higuchi, K. (1970). Endoscopic examination of the large bowel. *Sogo Rinsho*, **19**, 325-337.
- ²³Bennett, J. A., Salmon, P. R., Branch, R. A., Baskett, P. J. F., and Read, A. E. A. (1971). The use of inhalational anaesthesia during fibre-optic colonoscopy. *Anaesthesia*, **26**, 294-297.
- ²⁴Deyhle, P. Personal communication.
- ²⁵Sakai, Y., Personal communication.
- ²⁶Espiner, H. J., Salmon, P. R., Teague, R. H., and Read, A. E. (1973). Operative colonoscopy. *Brit. med. J.*, **1**, 453-454.
- ²⁷Nagasako, K., Endo, M., Takemoto, T., Kondo, T., and Kimura, K. (1970). The insertion of fibercolonoscope into the cecum and the direct observation of the ileocecal valve. *Endoscopy*, **2**, 123-126.
- ²⁸Nagasako, K., and Takemoto, T. (1972). Fibercolonoscopy without the help of fluoroscopy. *Endoscopy*, **4**, 208-212.
- ²⁹Deyhle, P. (1972). A new technique for the fiberendoscopic passage through the S type loop of the sigmoid colon. *Endoscopy*, **4**, 102-104.
- ³⁰Sakai, Y. (1972). The technic of colonofiberscopy. *Dis. Colon Rect.*, **15**, 403-412.
- ³¹Deyhle, P., and Demling, L. (1971). Colonoscopy: technique, results and indications. *Endoscopy*, **3**, 143-151.
- ³²Deyhle, P. (1972). A plastic tube for the maintenance of the straightening of the sigmoid colon during colonoscopy. *Endoscopy*, **4**, 224-226.
- ³³Deyhle, P. (1972). Flexible steel wire for the maintenance of the straightening of the sigmoid and transverse colon during colonoscopy. *Endoscopy*, **4**, 36-38.
- ³⁴Gabrielsson, N., Grandqvist, S., and Ohlson, H. (1972). Colonoscopy with the aid of a stiff wire to stiffen the fiberscope. *Endoscopy*, **4**, 217-218.
- ³⁵Salmon, P. R., Branch, R. A., Collins, C., Espiner, H., and Read, A. E. (1971). Clinical evaluation of fiberoptic sigmoidoscopy employing the Olympus CF-SB colonoscope. *Gut*, **12**, 729-735.
- ³⁶Nagasako, K., and Takemoto, T. (1973). Endoscopy of the ileo-caecal area. *Gastroenterology* **65**, 403-411.
- ³⁷Nagasako, K., Nagai, K., Suzuki, H., Yazawa, C., and Takemoto, T. (1972). Fiberscopic diagnosis of early cancer of the colon. *Endoscopy*, **4**, 1-5.
- ³⁸Chabanon, R., and Arnous, J. (1972). La coloscopie dans la rectocolite hémorragique. *Arch. Mal. Appar. dig.*, **61**, 369-372.
- ³⁹Dilawari, J. B., Parkinson, C., Riddell, R. H., Loose, H., and Williams, C. B. (1973). Colonoscopy in the investigation of ulcerative colitis. (Abstr.). *Gut*, **14**, 426.
- ⁴⁰Bartelheimer, W., Remmele, W., and Ottenjahn, R. (1972). Colonoscopic recognition of haemangiomas in the colon ascendens. *Endoscopy*, **4**, 109-114.
- ⁴¹Warwick, R. R. G., Sumerling, M. D., Gilmour, H. M., and Shearman, D. J. C. (1973). Colonoscopy and double contrast barium enema examination in chronic ulcerative colitis. *Amer. J. Roentgenol.*, **117**, 292-296.
- ⁴²Curtiss, L. E. (1973). High frequency currents in endoscopy: a review of principles and precautions. Gastrointestinal endoscopy.
- ⁴³Williams, C. B. (1973). Diathermy-biopsy: a technique for the endoscopic management of small polyps. *Endoscopy*, in press.
- ⁴⁴Seifert, E. (1972). A new flexible forceps for the removal of polyps from the gastrointestinal tract after successful endoscopic polypectomy. *Endoscopy*, **4**, 226-227.
- ⁴⁵Williams, C. B., Muto, T., Rutter, K. R. P., Swarbrick, E. T. S., Riddell, R., and Loose, H. (1973). In preparation.
- ⁴⁶Kleinfeld, G., and Gump, F. R. (1960). Complications of colotomy and polypectomy. *Surg. Gynec. Obstet.*, **III**, 726-728.
- ⁴⁷Meyers, D. S. (1973). Colonoscopy (letter). *New Engl. J. Med.*, **288**, 974.
- ⁴⁸Williams, C. B., Lane, R., Sakai, Y., and Hanwell, A. (1973). Air pressure: a hazard during colonoscopy. *Lancet* **II**, 729.
- ⁴⁹Colcher, H. (1971). Colonoscopie, quo vadis. *Ann. Gastroent. Hepat.*, **7**, 247-250.
- ⁵⁰Welin, S. (1958). Modern trends in diagnostic roentgenology of the colon. *Brit. J. Radiol.*, **31**, 453-464.
- ⁵¹Young, A. C. (1964). The Malmö enema at St Mark's Hospital: a preliminary report. *Proc. roy. Soc. Med.*, **57**, 275-278.
- ⁵²Deddish, M. R., and Hertz, R. E. (1955). Colotomy and coloscopy the management of mucosal polyps and cancer of the colon. *Amer. J. Surg.*, **90**, 846-849.
- ⁵³Cooley, R. N., Agnew, C. H., and Rios, G. (1960). Diagnostic accuracy of the barium enema study in carcinoma of the colon and rectum. *Amer. J. Roentgenol.* **84** 316-331.
- ⁵⁴Bloom, B. S., Goldhaber, S. Z., Sugarbaker, P. H., and O'Connor, N. E. (1973). Fiberoptics: morbidity and cost. *New Engl. J. Med.*, **288**, 368-369.
- ⁵⁵Provenzale, L., and Revignas, A. (1971). Colonic electrical activity recording and total fiberoptic colonoscopy. *Amer. J. Gastroent.*, **56**, 137-148.