

Progress report

Hepatic adenomas and oral contraceptives

Hitherto, hepatic adenoma has been regarded as an extremely rare, benign tumour, which is known to affect largely women of childbearing age. Over the past five years or so there has been a surprising increase in the number of published reports of patients with this lesion, and a close association has been found between it and the taking of oral contraceptives. This relationship was first suggested by Janet Baum and her coworkers¹ from Ann Arbor, Michigan, who collected seven cases of hepatic adenoma, all in women taking oral contraceptives. This publication led to a spate of letters to the journals and to other reports but, up to January 1975, there had been only some 46 patients reported with the association.

There is considerable confusion in the terminology of the lesion. Baum and her coworkers used the term 'benign hepatoma'. This should be avoided as it causes confusion with hepatocellular carcinomas which are frequently termed 'hepatomas'. The tumour may be typically adenomatous with nodules, cords or sheaths of liver cells closely resembling the normal hepatocyte. The tumour is not sharply differentiated from normal liver. There is a prominent vascular component, the sinusoids being focally dilated and the arteries and veins showing thickening of their walls². Sometimes, the blood spaces at the periphery of the tumour are particularly large and without endothelial linings. This is termed 'peliosis hepatis'³. Peliosis has been described in the absence of adenoma in patients taking oral contraceptives⁴. Some of the areas of vascular abnormality are infarcted and thrombosis may be seen⁵. Hamartoma is a tumour-like malformation in which the various tissues are present in improper proportions. In three patients, the presence of bile duct reduplication and fibrous trabeculae, in addition to the vascular lesions, led to the use of this term⁵. Hamartoma is usually regarded as an innocent change and often an incidental necropsy finding. O'Sullivan and Wilding⁵ recognized that the lesion they described as hamartoma was essentially similar to that described by Baum¹. Finally, Mays and his coworkers² used the term 'focal nodular hyperplasia' for the lesion they found in three patients who had been taking oral contraceptives. The term was used because of the bile duct proliferation and the lack of definition of the lesion from surrounding tissues. There is no universally acceptable terminology for these lesions. The terms 'hamartoma' and 'hepatoma' should be avoided but 'adenoma' and 'focal nodular hyperplasia' seem equally appropriate.

Hepatocellular carcinoma has not been reported to date, although one instance of hepatoblastoma has been noted⁶. This is an unexpected tumour in the adult.

The liver lesions have been associated with most of the commonly used oral contraceptives. They include combinations of norethynodrel, mestranoldiethylsterone, ethyloestradiol, norgestrol, norethisterone, and ethinylestradiol.

The patient has usually been on 'the pill' for at least two years and often for more than four years. The shortest time reported is six months¹. In two instances, the adenoma was diagnosed four years² and two years⁷ after stopping 'the pill'.

Patients may present with constant right upper quadrant abdominal pain or they, or their physicians, may feel an abdominal mass. The most dramatic and serious presentation is as an abdominal emergency due to rupture of the tumour with haemorrhage into the peritoneal cavity. The frequency of this association is such that ruptured hepatic adenoma must be considered in any abdominal emergency developing in a woman of childbearing age. This complication may be fatal^{1,3}.

Before rupture, hepatic arteriography is the best diagnostic aid. The hepatic artery is enlarged. The tumour shows as a filling defect in the liver with a clearly defined margin and approximately parallel entering vessels from the periphery¹. Serial films show a persistent tumour blush into the venous phase. Hepatic scanning shows a filling defect if the lesion is more than 2 cm in diameter but is of no value in differential diagnosis. Routine serum biochemical tests are usually normal and these contribute nothing. Serum alpha-fetoprotein values are not increased into the range associated with primary hepatocellular carcinoma. Needle liver biopsy is contraindicated because of the vascularity of the tumour and the risk of complicating haemorrhage.

Because of the danger of intraperitoneal bleeding, which may be fatal, surgical treatment is usually recommended⁵. In an emergency blood loss is controlled by some form of liver resection. In the elective case, local removal is usually possible and this is a relatively easy procedure in experienced hands. The decision to remove an asymptomatic tumour in an otherwise healthy young woman is difficult and in the individual case cannot be given an easy answer. The liver size seems unrelated to the possibility of rupture, although position near the surface is obviously important. If surgery is declined the woman must be warned of the significance of any abdominal symptoms that she may experience. The prognosis seems to be very good if the tumour is resected, although the lesions may be multiple.

Hepatic adenoma may also be expected in postmenopausal women receiving hormone replacement. The author has seen one such case.

In 1972, the Committee on Safety of Drugs of the United Kingdom reported an increase over expected frequency in liver cell tumours in male rats given norethynodrel⁸ and in 1969 female rats had been reported to show variation in liver cell size, cellular swelling and opening up of sinusoids when given norethynodrel⁹. The occurrence of liver tumours in women taking oral contraceptives might, therefore, be expected. In 1971, a relationship between primary hepatocellular carcinoma and androgenic treatment with long-term C₁₇ alkylated anabolic steroids and oxygenated 2 methyl testosterone for the treatment of bone marrow aplasia (Fanconi's anaemia) had already been shown^{10,11}. In one patient the tumour regressed when the hormones were stopped, suggesting that the tumour differed from the usual more serious type of hepatocellular carcinoma. Slow growing primary liver cancer has been reported in three men receiving androgens for treatment of anaemia associated with paroxysmal nocturnal haemoglobinuria or testicular insufficiency due to hypopituitarism or cryptorchidism¹². In two, regression of the tumour followed the withdrawal of androgen therapy. Most oral contra-

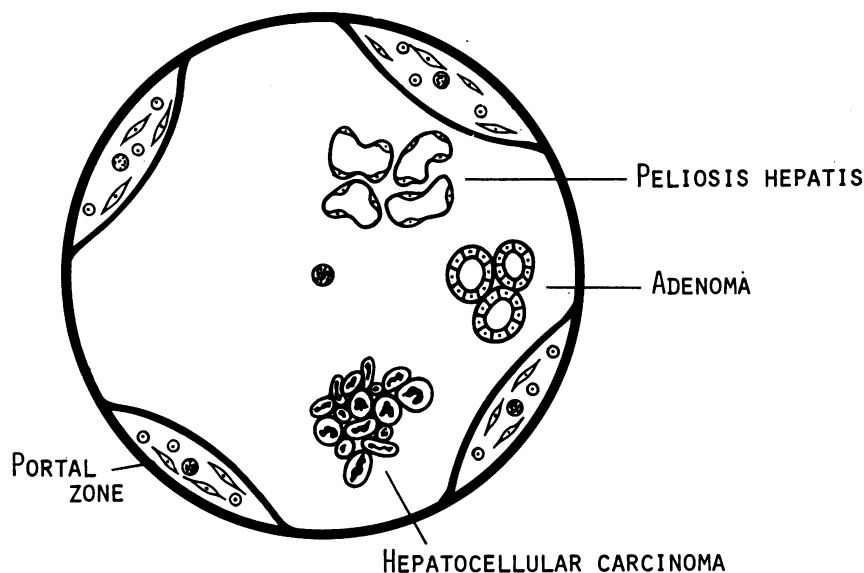
EFFECTS OF SEX-HORMONES ON LIVER

Fig. The hepatic complications of sex-hormone therapy include peliosis hepatis, hepatic carcinoma and hepatocellular carcinoma.

ceptive combinations contain a C₁₇ substituted testosterone derivative, but it is presumably the small amount administered that prevents the development of hepatocellular carcinoma. Peliosis has also been seen in patients treated for aplastic anaemia with long-term, high-dose androgens. It has recently been reported in seven patients treated with androgenic-anabolic steroids for periods from two to 27 months¹³. Two suffered intraperitoneal haemorrhage. The haemorrhagic cysts seemed to develop from foci of hepatocellular necrosis.

It is impossible to be sure whether it is the oestrogen or the progesterone component which is responsible for the hepatic lesion or, indeed, whether it might be both. The progestogens are anabolic steroids, as is oxymethalone. They are also enzyme inducers¹⁴. The oestrogens are carcinogenic in other organs and promote liver regeneration in rats¹⁵. They are not enzyme inducers¹⁴. The mechanism by which the drugs are oncogenic is also uncertain. It could be a direct effect. Alternatively, and perhaps more likely, these steroids, certainly the progestogens, are enzyme inducers. They lead to hypertrophy of the smooth endoplasmic reticulum and mitochondrial abnormalities follow their use¹⁶. Enzyme induction is known to increase the carcinogenicity of certain compounds. The steroids in oral contraceptives are C-substituted testosterone derivatives and so mildly cholestatic, albeit only to a small extent. This property might enhance the potentially carcinogenic action of substances normally excreted in the bile.

The peliosis may be associated or unconnected with the nodular regeneration. It has been described with wasting diseases, such as tuberculosis and also associated with norethandrolone therapy¹⁷. It has been described independently of adenoma in women on oral contraceptives⁴. The vascular changes probably represent part of the general vasodilatation associated with

sex hormones and are analogous both to the vascular spiders developing in the skin and to the corkscrew endometrial arterial hypertrophy found in pregnancy. The pattern of vascular change in some respects resembles that described as a toxic effect of organic arsenicals¹⁸, Thorotrast, or the monomer of polyvinyl chloride¹⁹. In all these conditions, vascular abnormalities, even peliosis, may be seen and the small vessels, both arterial and venous, show hypertrophy of their walls.

The extent of the problem is not known. In the United States, some five million women at least take or have taken oral birth-control pills so that there has been mass exposure of large numbers of women. The small number of recorded cases of adenoma during the 20 years since oral contraceptives were introduced suggests that this complication is a rare one. There has, however, been an increasing number of reports, largely in surgical journals, of hepatic adenomas in young women, although the use of oral contraceptives has not been noted. Some of these reports could have included women taking oral contraceptives. A careful watch on the problem must be kept and all possible cases reported. There is no obvious method of prevention or of early detection. It is not practical to examine the abdomen regularly, throughout her childbearing life, of every woman placed on oral contraceptives. Physicians, however, must be alert to the possibility of hepatic adenoma in any young woman and must regard any abdominal pain, particularly with hepatomegaly, as suspicious. Ruptured hepatic adenoma must be included in the differential diagnosis of an acute abdomen in women of childbearing age, who are taking oral birth-control pills, and in older, postmenopausal women taking hormone replacements. Surgeons should be alert that a bleeding hepatic tumour observed at operation need not necessarily be malignant and might be susceptible to resection.

SHEILA SHERLOCK

Royal Free Hospital, Pond Street, London

References

- ¹Baum, J. K., Holtz, F., Bookstein, J. J., and Klein, E. W. (1973). Possible association between benign hepatomas and oral contraceptives *Lancet*, **2**, 926-929.
- ²Mays, E. T., Christopherson, W. M., and Barrows, G. H. (1974). Focal nodular hyperplasia of the liver: possible relationship to oral contraceptives. *Amer. J. clin. Path.*, **61**, 735-746.
- ³Contostavlos, D. L. (1973). Benign hepatomas and oral contraceptives. *Lancet*, **2**, 1200.
- ⁴Poulsen, H., and Winkler, K. (1973). Liver disease with periportal sinusoidal dilatation. *Digestion*, **8**, 441-442.
- ⁵O'Sullivan, J. P., and Wilding, R. P. (1974). Liver hamartomas in patients on oral contraceptives. *Brit. med. J.*, **3**, 7-10.
- ⁶Meyer, P., LiVolsi, V. A., and Cornog, J. L. (1974). Hepatoblastoma associated with oral contraceptives. *Lancet*, **2**, 1387.
- ⁷Fox, J. A. (1974). Personal communication.
- ⁸Committee on Safety of Medicines (1972). Carcinogenicity tests of oral contraceptives. HMSO, London.
- ⁹Beaconsfield, P. (1974). Liver tumours and steroid hormones. *Lancet*, **1**, 516-517.
- ¹⁰Johnson, F. L., Feagler, J. R., Lerner, K. G., Majerus, P. W., Siegel, M., Hartmann, J. R., and Thomas, E. D. (1972). Association of androgenic-anabolic steroid therapy with development of hepatocellular carcinoma. *Lancet*, **2**, 1273-1276.
- ¹¹Bernstein, M. S., Hunter, R. L., and Yachnin, S. (1971). Hepatoma and peliosis hepatis developing in a patient with Fanconi's anemia. *New Engl. J. Med.*, **284**, 1135-1136.
- ¹²Farrell, G. C., Joshua, D. E., Uren, R. F., Baird, P. J., Perkins, K. W., and Kronenberg, H. (1975). Androgen-induced hepatoma. *Lancet*, **1**, 430-432.
- ¹³Bagheri, S. A., and Boyer, J. L. (1974). Peliosis hepatis associated with androgenic-anabolic steroid therapy. *Ann. intern. Med.*, **81**, 610-618.
- ¹⁴Rifkind, A. B., Gillette, P. N., Song, C. S., and Kappas, A. (1970). Induction of hepatic δ -aminolevulinic acid synthetase by oral contraceptive steroids. *J. clin. Endocr.*, **30**, 330-335.
- ¹⁵Adlercreutz, H. (1974). Hepatic metabolism of estrogens in health and disease. *New Engl. J. Med.*, **290**, 1081-1083.
- ¹⁶Perez, V., Gorodisch, S., De Martire, J., Nicholson, R., Di Paola, G. (1969). Oral contraceptives: long-term use produces fine structural changes in liver mitochondria. *Science*, **165**, 805-807.
- ¹⁷Yanoff, M., and Rawson, A. J. (1964). Peliosis hepatis. *Arch. Path.*, **77**, 159-165.
- ¹⁸Morris, J. S., Schmid, M., Newman, S., Scheuer, P. J., and Sherlock, S. (1974). Arsenic and noncirrhotic portal hypertension. *Gastroenterology*, **66**, 86-94.
- ¹⁹Thomas, L. B., Popper, H., Berk, P. D., Selikoff, I., and Falk, H. (1974). Vinyl-chloride induced liver disease. *New Engl. J. Med.*, **292**, 17-20.