

Case report

Early or pre-coeliac mucosa: development of gluten enteropathy

BRIDIE EGAN-MITCHELL, P F FOTTRELL, AND B McNICHOLL

From the Departments of Paediatrics and Biochemistry University College, Galway

SUMMARY Duodenal mucosa showed normal morphology, interepithelial lymphocytes, alkaline phosphatase, and sucrase in a girl with growth retardation and iron deficiency, but normal absorption of lactose and xylose after two years of abnormal stools. Mucosal lactase was low. Fourteen months later mucosal damage consistent with coeliac disease was evident, and gluten intolerance was subsequently confirmed by gluten challenge. It is probable that, in some children, the mucosal lesion occurs very gradually, so that at an early stage with normal morphology, suppression of lactase activity and possibly interference with iron absorption may be the only abnormalities.

We are not aware of any published description of intestinal mucosa of normal appearance in a patient whose mucosa subsequently showed the characteristic enteropathy of coeliac disease and we therefore record such a case.

Methods

Intestinal biopsies were obtained with 8 mm single-port Crosby-Kugler capsules either in terminal duodenum, at or just beyond the ligament of Treitz. Mucosal grading, interepithelial lymphocyte counts, brush-border enzymes, haemoglobin, serum folate, and serum iron were assessed as previously described.¹ Control values for interepithelial lymphocytes and brush border enzymes are given in Table 1. Mucosal gradings were as follows: O=normal mucosa, I=mild, II=moderate, and III=severe mucosal damage; grade II and III are regarded as consistent with active coeliac disease. Height and weight were plotted on the charts of Tanner, Whitehouse, and Takaishi,² and bone age estimated with the atlas of Greulich and Pyle.³ HLA antigens were detected by the standard NIH Terasaki cytotoxicity method.

Case report

A girl of 8½ years was seen in February 1972 with a history of lethargy and pallor for about two years;

since infancy she had tended to be small in relation to her age compared with her siblings. Stools were said not to exceed one daily, tending to be large and offensive, but of normal colour and consistency and not tending to float. The mid-parental height was 167 cm, but there were some small paternal relatives. Her height was well below the 3rd centile and weight

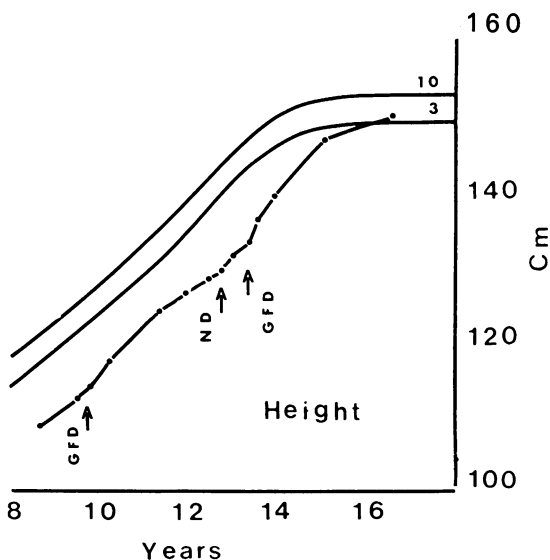


Fig. 1 Height in centimetres plotted on 3rd and 10th centiles on charts of Tanner, Whitehouse, and Takaishi.² GFD: gluten-free diet. ND: normal diet.

*Address for correspondence and reprint requests: B McNicholl, Paediatric Department, Regional Hospital, Galway.

Received for publication 18 August 1980.

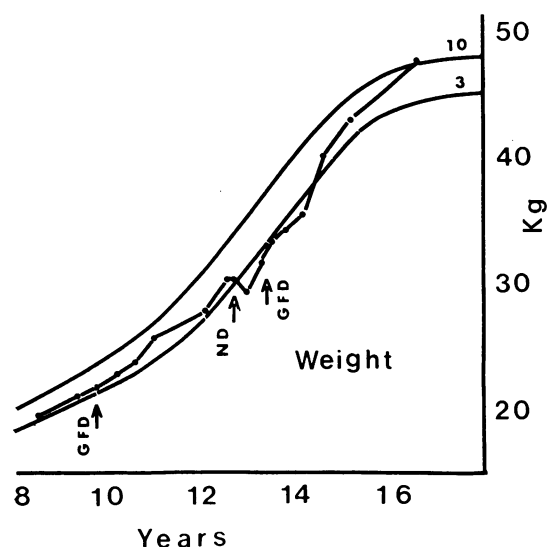


Fig. 2 Weight in kilograms plotted as in Fig. 1. GFD: gluten-free diet. ND: normal diet.

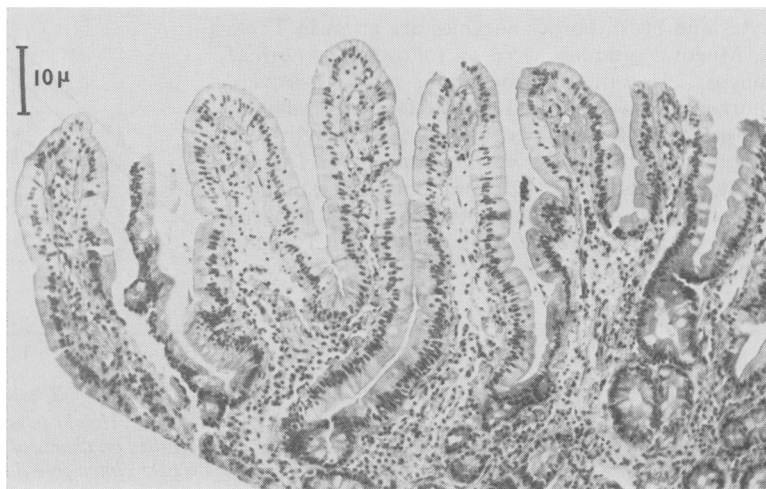was on the 3rd centile (Figs. 1 and 2); bone age was $5\frac{3}{4}$ years. There was much dental caries and she had had occasional dental abscesses. Haemoglobin was 8.0 g/dl, serum iron was $5\ \mu\text{mol/l}$, serum folate $2.8\ \mu\text{g/l}$ (normal range 2.1 to $9.5\ \mu\text{g/l}$). Relevant serum chemistry included calcium 2.9 mmol/l, phosphate 1.7 mmol/l, total protein 67.0 g/l, albumin 36.0 g/l, alkaline phosphatase 16 King Armstrong units (NR 4–17), cholesterol 4.3 mmol/l, and urea 3.4 mmol/l. Sweat chloride was 34 mmol/l. Serum d-xylose rose 2.9 mmol/l and lactose 2.8 mmol/l after oral doses of 10 g xylose and 20 g lactose respectively. Faecal fats were not estimated but

microscopy showed no excess of fat or fatty acid. Serum thyroxine was 92 nmol/l (normal range 55 to 145 n/mol/l). Biopsy from the terminal part of the duodenum showed leaf-like villi on dissecting microscopy and was regarded as normal on histological examination (Fig. 3, Table 2). In addition to the enzymes tabulated, maltase, palatinase, and trehalase were assayed and found normal. Treatment was with oral iron and vitamin supplements without change in diet. Her diet was said to be the same as that of her siblings; although not specifically assessed at the time, it would probably have contained in excess of 10 g gluten daily. Four months later the haemoglobin had risen to 11.0 g/dl, and 14 months later was 11.7 g/dl, serum iron was still low at $4\ \mu\text{mol/l}$, B12 was 739 pmol/l (*B. subtilis* assay) and folate was $4.6\ \mu\text{g/l}$. Failure of full response to iron medication together with persistence of tiredness and poor growth then led to a repeat biopsy which showed grade II changes consistent with coeliac disease both on dissecting microscopy and histological examination. (Fig. 4 and Table 2) and a gluten-free diet was started, with continued iron and vitamin supplementation. Immune globulins at this time

Table 1 Control values, giving mean and one standard deviation for interepithelial lymphocytes (IEL), alkaline phosphatase, lactase, and sucrase

	Site	N	Mean	ISD
IEL/1000 epithelial cells				
Alkaline phosphatase (IU/mg protein)	Duodenum	9	22.2	7.6
	Jejunum	16	28.9	7.4
Lactase (IU/g protein)	Duodenum	9	37.6	19.3
	Jejunum	16	62.8	21.6
Sucrase (IU/g protein)	Duodenum	9	58.0	33.7
	Jejunum	16	86.9	30.1

Fig. 3 Terminal duodenal mucosa, February 1972, slightly tangential and traumatised. Haematoxylin and eosin. $\times 60$ (Original magnification quoted in this and in the following figures).



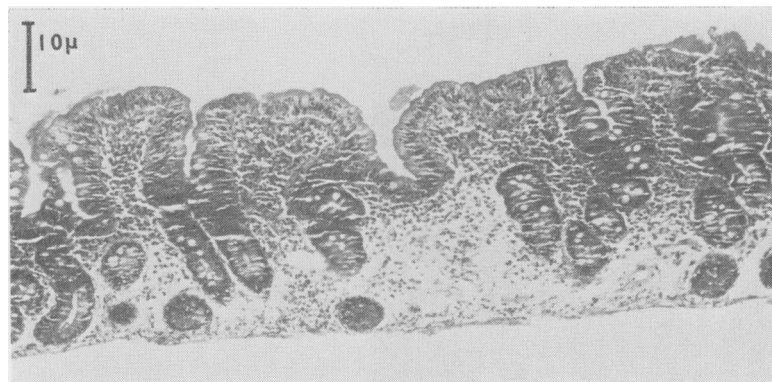


Fig. 4 Proximal jejunal mucosa, April 1973. Haematoxylin and eosin. $\times 60$.

Table 2 Details of biopsy site, mucosal grading, interepithelial lymphocytes, alkaline phosphatase, lactase, and sucrase

Date	Site	Grade	IEL per 1000 enterocytes	Alkaline phosphatase (IU/mg protein)	Lactase (IU/g protein)	Sucrase (IU/g protein)
February 1972	Duodenum	0	260	16.3	12.9	48.0
April 1973	Jejunum	11	782	6.7	2.3	14.3
October 1975	Jejunum	0/1	350	17.9	12.6	81.6
July 1976	Treitz	11	512	8.5	1.3	16.2

were G, 11.5 g/l, A, 1.55 g/l and M, 2.4 g/l; HLA antigens were A1, AW19, B8, B7.

Subsequently, there was gradual clinical improvement with a return of the haemoglobin and serum iron to normal levels, which have since been maintained. Slight initial growth acceleration was not maintained, probably because the diet was not strictly adhered to. A jejunal biopsy at 12½ years showed an almost normal appearance (Fig. 5, Table 2) with some improvement in lactase level,

but not to the normal range. She was challenged with a normal diet at 12¾ years and, although linear growth was unaffected, some weight loss resulted. Biopsy at the ligament of Treitz after four months on the normal diet showed mucosal relapse (Fig. 6, Table 2). After a return to a stricter gluten free diet, there was a better growth response (Figs. 1 and 2) with latest height and weight just above the 10th and 3rd centiles respectively. Some of this growth acceleration may have been due to the normal

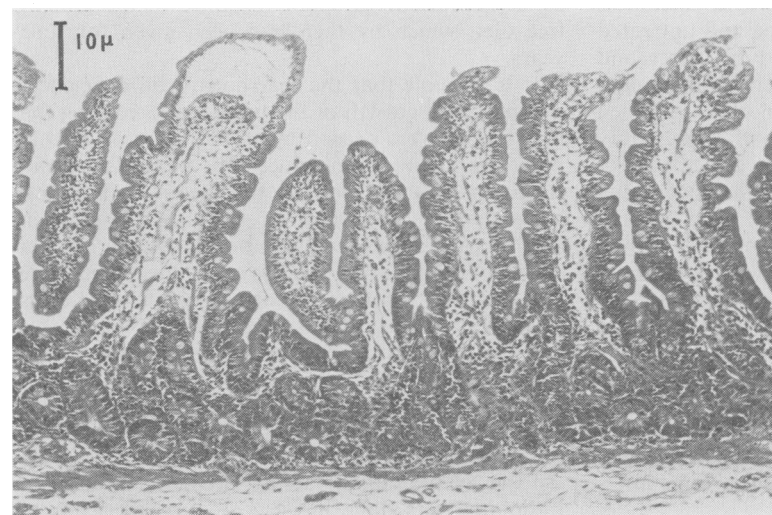


Fig. 5 Proximal jejunal mucosa, October 1975. Haematoxylin and eosin. $\times 60$.

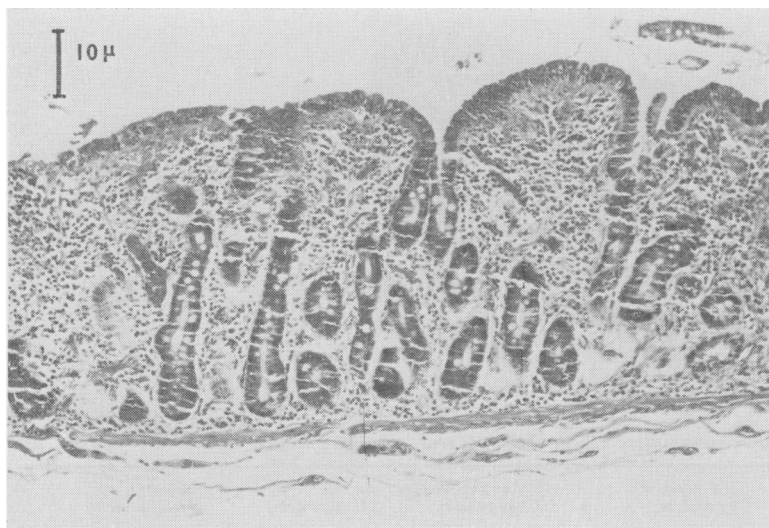


Fig. 6 *Proximal jejunal mucosa, July 1976. Haematoxylin and eosin, $\times 60$.*

pubertal spurt. The menarche occurred at 15½ years, since when menstruation has been regular. Any contributory growth hormone deficiency was ruled out by a normal response to insulin hypoglycaemia at the age of 13 years.

Discussion

Whatever the date of its establishment, gluten intolerance was confirmed in this girl by mucosal remission on a gluten free diet followed by mucosal relapse on gluten challenge. Our presumption, that the intestinal mucosa is of normal appearance before the characteristic mucosal damage of coeliac disease is established, seems to be confirmed by this patient's morphological normality when first sampled, the only abnormality then being a low lactase. Patchiness of the mucosal lesion in both treated and untreated coeliac disease has been described by Scott and Losowsky;⁴ they found it less frequent in duodenum than proximal jejunum. The single normal specimen from our patient is not inconsistent with abnormality of the mucosa in other areas, but Scott and Losowsky did not find complete normality of villi coexisting with moderately damaged mucosa. The normal absorption of lactose and xylose and the normal serum folate would correlate better with a generally normal mucosa than with a damaged one. One can speculate that the moderately low lactase level was insufficient to interfere with lactose digestion or that it was confined to the upper small intestine. We do not know whether the low lactase was due to early gluten toxicity or to inheritance; if the former were true, it is possible that the gluten toxicity could have impaired iron absorption by some interference with cellular metabolism.

With regard to the retarded growth, it is possible that its basis was genetic, at least in part, with associated delay in puberty; the girl's present height may be consistent with her inheritance. If the growth retardation of the years preceding the first biopsy was related to gluten ingestion, we are unable to suggest any satisfactory mechanism; the only possible evidence of malabsorption at the time was iron deficiency. Low plasma growth hormone after insulin hypoglycaemia has been described in untreated coeliac disease with severe mucosal damage;⁵ the mechanism of the impaired response was not understood, although comparison was made with the impaired growth hormone response in marasmus. We did not assay growth hormone until we were concerned about the poor response to the gluten-free diet, which by then had been given for four years.

It is possible that the diarrhoea, iron deficiency, and impaired growth of the two years preceding the first biopsy were caused by some factor or factors other than gluten intolerance. The normal IgA and raised IgM at the time of the second (abnormal) biopsy were the reverse of the usual finding in active coeliac disease and more consistent with a chronic inflammatory process of another sort. There was, however, nothing in our limited investigations to suggest such a process and the girl's subsequent progress makes the presence of any severe underlying illness unlikely. A public health nurse's report on the home made the question of neglect or malnutrition most unlikely. Giardiasis is one possible cause of her symptoms that was not sought with any persistence. Neither faecal fat measurement nor contrast radiology were done in view of our experience of

their unreliability in screening for coeliac disease,⁶ but in this particular case they might have aided diagnosis. We cannot exclude the possibility that gluten, in some subtle manner, contributed to the symptoms and iron deficiency of the two symptomatic years.

The apparent delay in the development of severe mucosal damage is not too surprising in view of our experience of a lapse of five years from the start of a normal diet in a coeliac child until definite mucosal relapse occurred; during this period there was no adverse effect on growth, haemoglobin, or folate levels, but there was a gradual fall in mucosal lactase and rise in interepithelial lymphocytes accompanying gradual mucosal deterioration.⁶ We have seen two other children with initial biopsies regarded as normal who subsequently had severe mucosal damage (later reproduced by gluten challenge); these children also showed growth retardation and iron deficiency. Our conclusion is that the upper intestinal mucosa appears normal before or in the early stages of coeliac disease and that there must be considerable variation in different patients in the interval between the introduction of gluten to the diet and the time of establishment of severe enteropathy. Such variation seems likely when one considers that severe gluten enteropathy may be found as early as 4 months old (in our experience), and yet may not appear until many months or years after the beginning of gluten ingestion, which, in Great Britain, commonly took place before 3 months of age until relatively recently. In the 'pre-coeliac' interval, interference with some mucosal functions may occur when our

present methods of mucosal appraisal find little or no abnormality.

We wish to thank Professor C F McCarthy for the HLA assays, S Baker for interepithelial lymphocyte counts, and Dr H Grimes for the general biochemical investigations. The authors are grateful to the Medical Research Council of Ireland, the Wellcome Trust and the Western Health Board for financial support.

References

- ¹McNicholl B, Egan-Mitchell B, Stevens F, *et al.* Mucosal recovery in treated childhood coeliac disease (gluten-sensitive enteropathy). *J Pediatr* 1976; **89**: 418–24.
- ²Tanner, JM, Whitehouse RH, Takaishi M. Standards from birth to maturity for height, weight, height velocity and weight velocity: British children. *Arch Dis Child* 1966; **41**: 454–71, 613–35.
- ³Greulich W W, Pyle SI. *Radiographic atlas of skeletal development of the hand and wrist*. 2nd ed. California: Stanford University Press, 1959.
- ⁴Scott BB, Losowsky MS. Patchiness and duodenal-jejunal variation of the mucosal abnormality in coeliac disease and dermatitis herpetiformis. *Gut* 1976; **17**: 984–92.
- ⁵Vanderschueren-Lodeweyckx M, Walter R, Molla A, Eggermont E, Eeckels R. Plasma growth hormone in coeliac disease. *Helv. Paediatr Acta* 1973; **28**: 349–57.
- ⁶McNicholl B, Egan B. Jejunal biopsy in coeliac disease. *Clin Pediatr* 1968; **7**: 544–52.
- ⁷McNicholl B, Egan-Mitchell B, Fottrell PF. Variability of gluten intolerance in treated childhood coeliac disease. *Gut*. 1979; **20**: 126–32.