

# Endoscopic features of primary small bowel lymphoma: a proposed endoscopic classification

M H BARAKAT

*From the Gastroenterology Section, Kuwait University Medical Faculty and Al-Sabah Hospital, Kuwait*

**SUMMARY** Primary small bowel lymphoma is relatively common in Middle Eastern countries. Of 29 such cases, proximal small bowel endoscopy was positive in 26 (89.6%) and, on the basis of endoscopy alone, the diagnosis of lymphoma was confidently made in 24 patients (82.7%). The endoscopic biopsy was diagnostic in 19 of the 26 patients with visible mucosal abnormalities (73%). Four types of lesions have been seen on the basis of which an endoscopic classification is being proposed. This classification may be of therapeutic and prognostic value.

Evidence has now accumulated that primary small bowel lymphoma is remarkably prevalent in the countries of the Middle East. Unlike intestinal lymphoma in Europe and North America, this disease is seen in young patients, usually in association with malabsorption and, in a number of them, an abnormal immunoglobulin is detected in the serum. Because of these features and the associated histological changes it has become usual to call this disease immunoproliferative small intestinal disease or IPSID.<sup>1</sup> In all the reported studies the histological diagnosis depended on examination of tissue obtained either at the post-mortem table or during diagnostic laparotomy or by peroral jejunal capsule biopsy. The role of upper gastrointestinal endoscopy and the value of endoscopic biopsy in the diagnosis, management, and follow-up of patients with this disease have not been previously recorded. Over a four year period between 1975 and 1979 these means have been employed in the work-up of patients suspected to have IPSID at the Al-Sabah Hospital, Kuwait. This report describes our experience.

## Methods

### PATIENTS

The endoscopic records of 29 patients seen between October 1975 and October 1979 with a histologically established diagnosis of primary small bowel lymphoma were reviewed. All had been examined in the gastroenterology service of

the Al-Sabah Hospital by one endoscopist (MB). In 25 patients, Olympus JF (duodenscope) and in four patients Olympus SIF (jejunoscope) fiberoptic instruments were used. The premedications included lignocaine 2% as topical anaesthesia and intravenous diazepam as a sedative. Intraoperatively, 1 mg glucagon was given intravenously to test the distensibility of the bowel folds and wall by pumping air through the instrument.

Each examination included evaluation of the mucosal appearance, the mucosal folds, the gross peristaltic activity, and the distensibility of the bowel wall before and after glucagon injection. The endoscope was introduced into the proximal small bowel to a level where a satisfactory endoscopic evaluation of the lesion had been reached, or, when the examination was negative, to the most distal site the instrument could reach without undue discomfort to the patient (25 cm beyond the ligament of Trietz). At least five biopsies were obtained from identifiable abnormalities. When endoscopy was negative, biopsies were taken from different sites of the bowel examined. In patients where the examination was positive but the endoscopic biopsy was negative, re-endoscopy with biopsy was resorted to. Laparotomy with biopsy or resection was also performed whenever intestinal obstruction or perforation was suspected.

## Results

Thirty-three diagnostic endoscopic examinations were performed for the 29 patients during the four year period. Eighteen laparotomies were also per-

### Endoscopic features of primary small bowel lymphoma

formed for diagnostic or therapeutic indications. The endoscopic diagnosis of bowel lymphoma was made in 24 (82.7%) of the 29 patients and was strongly suspected in two. In the remaining three patients no abnormality was visible in the proximal bowel examined.

Endoscopic biopsy was abnormal in 19 of the 29 patients. Eight of these showed a dense infiltrate of mature plasma cells without histological evidence of malignancy; 11 biopsies showed infiltration of the submucosa and lamina propria with malignant pleomorphic lymphoplasmocytic cells. The histological diagnosis in the remaining 10 patients was established by open full-thickness biopsy or by examination of the resected involved bowel. Among these 10 were three patients whose endoscopic examination and biopsies were negative but in whom the clinical and radiological pictures suggested primary bowel lymphoma. At surgery, the involved parts of the bowel were distal to the level reached by the fibroscope. This would raise the diagnostic accuracy of endoscopic biopsy to 19 out of 26 (73%).

Four distinctive types of endoscopic lesions have been encountered in 26 patients with abnormal findings (Table). These types are distinguished by the descriptive classification used here:

#### GRANULOPAPULAR LESION (Fig. 1)

This lesion was seen in seven patients. The small bowel mucosa was coarse, friable, and diffusely granular, much like the picture seen in mild ulcerative proctitis. Tiny papules and superficial erosions punctuated the granular mucosa. The involvement was uniform and extended over variable lengths of bowel. The mucosal folds were grossly thickened but peristalsis and distensibility were normal. In six of the seven patients the endoscopic biopsy was positive. Only one case was malignant.

#### NODULOPOLYPOID LESION (Fig. 2)

This was the picture in six patients where submucosal projections varying in size from 2–10 mm were visibly covered by normal-looking mucosa. The bowel involvement was patchy and irregular. Involved segments were rigid, and peristalsis in these segments was poor. Superficial mucosal biopsy was often negative but, when several bites were obtained from the same spot (caving the submucosa), the chances of positive results became high. Four of our six patients had positive endoscopic biopsies, three of them were benign.

#### ULCERATIVE LESION (Fig. 3)

This lesion was seen in six patients. Deep, irregular, dirty-looking ulcerations involving variable lengths of the bowel both longitudinally and circumferentially were seen. The ulcer size varied between  $\frac{1}{2}$  cm–5 cm. When the duodenal bulb was involved the diagnosis of peptic ulcer disease was excluded by more distal visualisation and biopsy. Distensibility of the wall and peristalsis were poor. In three of the six patients strictures were encountered. Such strictures sometimes made a thorough examination difficult, for forceful advancement of the instrument might cause perforation. Endoscopic biopsy was positive in all six patients and all were malignant.

#### INFILTRATIVE LESION (Fig. 4)

Four patients with this lesion were encountered. Here, the bowel mucosa looked perfectly normal. The major endoscopic abnormalities were very poor peristalsis and limited distensibility of the bowel wall. Endoscopic biopsy was negative in all.

#### MIXED LESION

In three patients two or more different types of lesion were seen to coexist and in one patient different lesions in different bowel segments were

Table Endoscopic features and endoscopic biopsy results in 29 patients of primary small bowel lymphoma

Type of lesion	Peristalsis	Distensibility	Patients (no.)	Positive endoscopic biopsy		
				Benign	Malignant	Total
Granulopapular	Normal	Normal	7	5	1	6
Nodulopolyloid	Fair	Fair	6	3	1	4
Ulcerative	Poor	Rigid	6	0	6	6
Infiltrative	Poor	Rigid	4	0	0	0
Mixed	Variable	Variable	3	0	3	3
Normal	—	—	3	0	0	0
Total			29	8	11	19

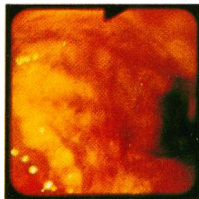


Fig. 1  
Granulopapular lesion.

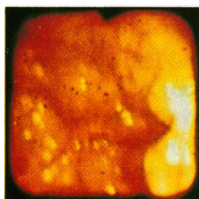


Fig. 2  
Nodulopolypoid lesion.

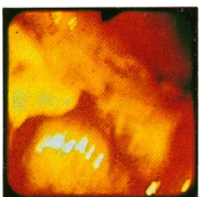


Fig. 3  
Ulcerative lesion.

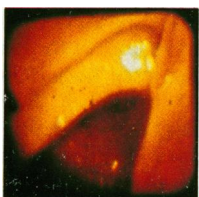


Fig. 4  
Infiltrative lesion.

encountered. This does not seem to be a specific lesion but rather an evolutionary stage of one or more of the types described above.

### Discussion

Immunoproliferative small intestinal disease (IPSID) is reportedly prevalent in several Middle Eastern countries. First observed among Lebanese and Syrian patients seen at the American University Hospital in Beirut<sup>2</sup> the disease was shortly after described in Palestinian Arabs and Israeli Sephardic Jews of North African and Middle Eastern origin.<sup>3</sup> This geographical distribution and the different clinical presentation of the disease were among the reasons for calling it 'Mediterranean' lymphoma.<sup>4</sup> This name, however, does not seem quite appropriate now, as large series of patients had been reported from Iran,<sup>5</sup> Iraq,<sup>6</sup> and Kuwait (personal communication). Furthermore, patients with similar clinical presentation and intestinal pathology have been reported from other parts of the world including South Africa<sup>7</sup> and North America.<sup>8</sup> Sporadic cases have also been seen in Italy, Spain, and the Netherlands but all the cases described so far in Britain came from Middle

Eastern countries.<sup>9</sup> As socioeconomic factors are changing rapidly, especially in the Middle East, producing widespread population movements, more and more patients with this disease are likely to be seen in Western Europe and North America.

Clinically, the victims of IPSID are young adults of both sexes, typically from the unprivileged socioeconomic class, presenting with malabsorption-like syndrome.<sup>1 6 10-14</sup> In a few patients intestinal obstruction or perforation may be the presenting symptom.<sup>6 15</sup> Peripheral adenopathy and abdominal organomegaly are rare findings.<sup>1 12 13</sup> Barium examination of the small bowel is often non-specific, though suggestive in endemic areas.<sup>6 16</sup> In a variable number of patients, an immunoglobulin paraprotein (IgA alpha-heavy chain) may be detected in the serum, the intestinal juice, or the tumour cells.<sup>6 12-14 17 18 20-22</sup> The definitive diagnosis, however, depends upon the demonstration in small intestinal tissue specimens of the histopathological findings characteristic of IPSID. These findings are either in the form of a dense infiltrate of mature (benign) plasma cells or plasmacytoid lymphocytes in the lamina propria without evidence of lymphoma cells elsewhere in the intestine or mesenteric lymph nodes (Fig. 5a and b) or in the form of infiltration of the submucosa with pleomorphic lymphoplasmacytic cells (immunoblasts) with varying degrees of mature plasma cell proliferation (Fig. 6a and b).<sup>8 10 12 13 21-25</sup> It has been accepted that when the only pathological changes are limited to mature plasma cell infiltrate, the disease should be called IPSID 'stage 0'.<sup>1 13 22</sup> Progression of the disease from 'stage 0' to the malignant form of IPSID has been well documented.<sup>21 22 25</sup> This, and the frequent association of the malignant stage of the disease with mature cell infiltration, suggests the possibility that a premalignant phase of the disease may exist. Moreover, complete clinical, immunological, and histological remission has been achieved in a few patients with 'stage 0' disease by prolonged antibiotic and/or antiparasitic therapy.<sup>1 10 18 25</sup> The likelihood that a premalignant phase of the disease may exist and the possibility of a cure make the diagnosis at an early stage and the close follow-up of patients at 'stage 0' very important.

As this type of lymphoma, unlike the 'Western' variety, involves the proximal part of the small bowel more often than the distal parts, peroral jejunal capsule biopsy was used in the diagnostic work-up in many patients in all the reported series with varying degrees of diagnostic success. It is conceivable that the failure had resulted from

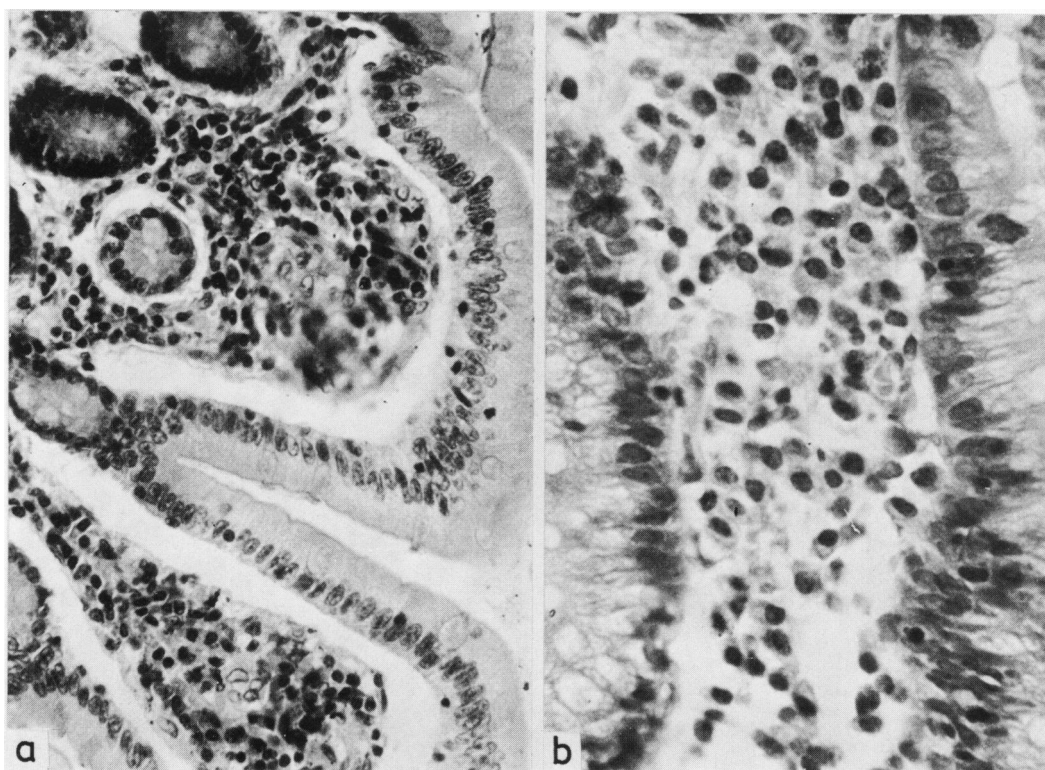


Fig. 5 'Stage O' IPSID. (a) Endoscopic duodenal biopsy from a granulopapular lesion showing mature plasma cell in the lamina propria. H and E stain,  $\times 100$  (original magnification). (b) High power view of Fig. 5a.

obtaining the specimen blindly from a normal distal bowel segment or, when the disease was patchy, it was taken from a healthy 'skipped' area.

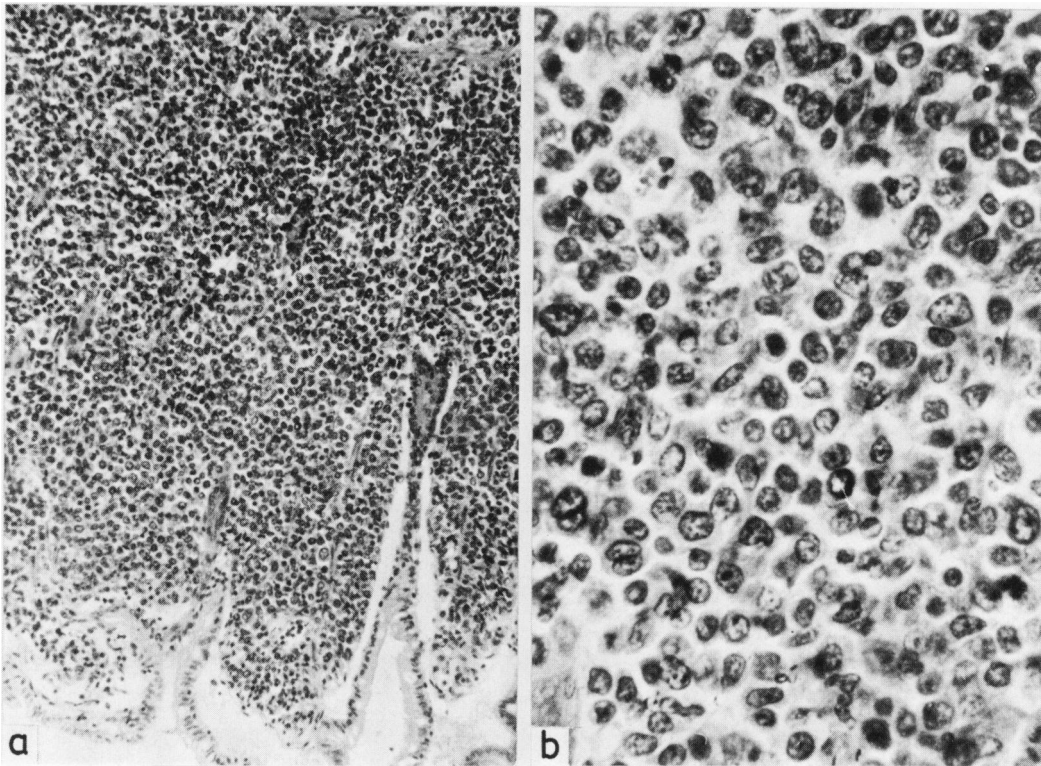
During a period of four years we have used upper gastrointestinal endoscopy and endoscopic biopsy in 29 patients suspected of having IPSID. Four main types of intestinal lesions were encountered in these patients. Though not characteristic of the disease these lesions can be considered pathognomonic, especially in Middle Eastern countries where IPSID is endemic and Crohn's disease is rare. As yet we have not seen such lesions in other diseases of the proximal small bowel except in adenocarcinoma of the duodenum and the periampullary region; but, then, the clinical and the radiological pictures are quite different from those of lymphoma.

Of the 29 patients so examined, only three had no visible endoscopic lesions. At laparotomy the diseased bowel in those three patients was distal to levels reached by the endoscope. Thus, on the

basis of endoscopy alone, lymphoma was diagnosed in 24 of the 26 patients (92%) with visible lesions.

Not only was the morphology of the lesions at endoscopy of value in the diagnosis but other directly obtained information was also equally important. The peristaltic activity of the bowel segments and the degree of distensibility of the bowel wall added new dimensions to the morphological appearance of the mucosal lesion because they reflect changes beyond the surface mucosa—namely, the muscularis mucosae, the submucosa, and probably the nerve plexuses. In our experience, whenever poor peristalsis and rigidity are encountered, a malignant stage of the disease is invariably present.

The greatest value of endoscopy in IPSID depends, perhaps, on obtaining the biopsy under direct endoscopic guidance from the desired site or lesion. As the main pathological changes of IPSID are reflected in the lamina propria, an



**Fig. 6** Malignant IPSID. (a) Endoscopic duodenal biopsy from an ulcerative lesion showing immunoblasts and mature plasma cells in the lamina propria. H and E stain,  $\times 100$  (original magnification). (b) High power view of Fig 6a.

adequate biopsy specimen should contain that portion of the bowel. The endoscopic biopsy forceps that are available at present are fairly good for that purpose, though not ideal. Upper gastrointestinal endoscopy in general is an easy and a safe procedure requiring on the average 7–10 minutes to perform, a much shorter time than peroral capsule biopsy. When skilfully done, it offers a diagnostic method that has a much lower morbidity than laparotomy and with a greater reliability and selectivity than blind peroral capsule biopsy.

Where the biopsy result reveals a malignant stage of the disease the need for a staging or a diagnostic laparotomy is either lessened or totally cancelled, depending on the institution's policy of therapy. Eleven of our 29 patients (38%) fell into this category. In this group of malignant disease the response to therapy is best assessed by comparison of the endoscopic findings and histology before and after treatment. A controversy, how-

ever, arises where the initial bowel histology reveals 'stage 0' IPSID—the so-called premalignant phase of the disease. Some authors stress the need for an immediate laparotomy to exclude the possibility of malignant transformation elsewhere in the small bowel or in the abdominal lymph nodes.<sup>10 12</sup> The total reported number of such patients remains too small to draw hard conclusions. Nevertheless, it is in this particular group of patients with histologically proven 'stage 0' IPSID that repeated upper gastrointestinal endoscopy and endoscopic biopsy are of paramount importance. The objectives of therapy in this group are not only the induction of a clinical remission but also the reversal of the histological changes to the normal or near-normal pattern. Of equal significance is the alertness to the possibility of malignant transformation of the benign process. Perhaps the best possible means towards the fulfilment of these objectives is a periodic endoscopic evaluation of the morphology of the lesion, the peri-

staltic activity, the distensibility of the bowel wall, and the histological picture.

Where the intestinal biopsy reveals a normal histology in spite of visible endoscopic lesions or abnormality, one or two more attempts of the whole procedure may prove fruitful. Should these remain persistently negative, especially in the presence of an infiltrative type of lesion, then capsule biopsy should be tried before a decision for laparotomy is undertaken. In our experience, it is this lesion—and to a lesser extent the nodulopolypoid type—that are least likely to yield positive histological results, yet, they are invariably malignant.

In conclusion, upper gastrointestinal endoscopy and endoscopic biopsy, if used expertly, would greatly help in the initial diagnosis of IPSID, save the majority of patients the risk and morbidity of laparotomy, and offer a good reliable means of follow-up for those with either malignant or benign disease. The classification suggested in this report may be of diagnostic, therapeutic, and prognostic value.

## References

- <sup>1</sup>WHO Report. Alpha heavy chain disease meeting. Geneva: WHO, 1975.
- <sup>2</sup>Azar HA. Cancer in Lebanon and the Near East. *Cancer* 1962; **15**:66–78.
- <sup>3</sup>Frand VI, Ramot B. Malignant lymphomata. An epidemiological study. *Harefuah* 1963; **65**:83–6.
- <sup>4</sup>Seijffers MJ, Levy M, Herman G. Intractable diarrhea, hypokalemia and malabsorption in a patient with Mediterranean type abdominal lymphoma. *Gastroenterology* 1968; **55**:118–24.
- <sup>5</sup>Haghighi P, Nabizadeh I, Asvadi S, Mohallatee EA. Cancer in South Iran. *Cancer* 1971; **27**:965–77.
- <sup>6</sup>Al-Saleem T, Al-Bahrani Z. Malignant lymphoma of the small intestine in Iraq. *Cancer* 1973; **31**:291–4.
- <sup>7</sup>Novis BH, Banks S, Marks IN *et al.* Alpha chain disease in Sub-Saharan Africa. *Am J Dig Dis* 1973; **10**:679–88.
- <sup>8</sup>Lewin KJ, Rauchod M, Dorfman RF. Lymphomas of the gastrointestinal tract. *Cancer* 1978; **42**:693–707.
- <sup>9</sup>Isaacson P, Wright DH. Origins of the intestinal lymphoma. *Lancet* 1978; **1**:984–5.
- <sup>10</sup>Rappaport H, Ramot B, Hulu N, Park JK. The pathology of the so-called Mediterranean abdominal lymphoma with malabsorption. *Cancer* 1972; **29**:1502–11.
- <sup>11</sup>Eidelman S, Parkins RA, Rubin C. Abdominal lymphoma presenting as malabsorption. *Medicine (Balt)* 1966; **45**:11–37.
- <sup>12</sup>Salem PA, Nassar VH, Shahid MJ *et al.* Mediterranean abdominal lymphoma or immunoproliferative small intestinal disease. *Cancer* 1977; **40**:2941–7.
- <sup>13</sup>Al-Bahrani Z, Al-Saleem T, Al-Mondhiry H, *et al.* Alpha heavy chain disease, report on 18 cases from Iraq. *Gut* 1978; **19**:627–31.
- <sup>14</sup>Seligman M, Mihaesco E, Frangioni B. Studies on alpha chain disease. *Ann NY Acad Sci* 1971; **190**:487–500.
- <sup>15</sup>Lessing JB, Merhar A, Baratz M. 'Mediterranean' lymphoma—an unusual course. *Am J Med Sci* 1977; **273**:221–5.
- <sup>16</sup>Nasr K, Haghighi P, Bakhshanedh K *et al.* Primary lymphoma of the upper small intestine. *Gut* 1970; **11**:673–8.
- <sup>17</sup>Seligman M, Danon F, Hurez D, *et al.* Alpha chain disease: a new immunoglobulin abnormality. *Science* 1968; **162**:1396–7.
- <sup>18</sup>Shahid MJ, Alami SY, Nassar VH *et al.* Primary intestinal lymphoma with paraproteinemia. *Cancer* 1975; **35**:848–58.
- <sup>19</sup>Roge J, Druet P, Marche C. Lymphoma Mediterranean avec maladie des chaines alpha. Triple remission clinique, anatomique et immunologique. *Pathol Biol* 1970; **18**:851–6.
- <sup>20</sup>Ramband JC, Bongel C, Prost A *et al.* Clinicopathological study of a patient with 'Mediterranean' type of abdominal lymphoma. *Digestion* 1968; **1**:321–36.
- <sup>21</sup>Bougel C, Ramband JC, Modigliani R *et al.* Etude clinique, anatomopathologique et immuno-clinique d'un nouveau cas de maladie des chaines alpha suivie pendant cinq ans. *Eur J Clin Biol Res* 1972; **4**:362–74.
- <sup>22</sup>Al-Saleem T, Zardawi IM. Primary lymphomas of the small intestine in Iraq. A pathological study of 145 cases. *Histopathology* 1979; **3**:89–106.
- <sup>23</sup>Nassar VH, Salem PA, Shahid MJ *et al.* 'Mediterranean' abdominal lymphoma or immunoproliferative small intestinal disease. *Cancer* 1978; **41**:1340–54.
- <sup>24</sup>Al-Saleem T, Zardawi IM. Pathology of 'Mediterranean' lymphoma. *Lancet* 1978; **1**:775–6.
- <sup>25</sup>Lewin KJ, Kahn LB, Novis BH. Primary intestinal lymphoma of 'Western' and 'Mediterranean' type. *Cancer* 1976; **38**:2511–28.