

*Clinical practice***Management of achalasia of the cardia by forced pneumatic dilatation**

A H LISHMAN* and A W DELLIPIANI

From North Tees General Hospital, Stockton on Tees, Cleveland

SUMMARY Eighteen patients with achalasia of the cardia diagnosed by radiography, endoscopy, and manometry were subjected to forced pneumatic dilatation under fluoroscopic control. The procedure was uneventful in all but one patient who developed a pneumomediastinum which resolved on conservative management. A satisfactory result was obtained in 16 patients (89%), 10 patients remaining asymptomatic and six patients having mild symptoms only in follow-up periods of up to 10 years. Only two patients have unsatisfactory results, one having developed a peptic stricture and one having a fibrosed incompetent lower oesophageal stricture with moderate reflux. The success rate of forced dilatation is similar to that of cardiomyotomy but, as it is a relatively minor procedure with a low incidence of complications and a short hospital stay, we conclude that there is an important place for forced pneumatic dilatation in the first line management of achalasia of the cardia.

While the motility disorder in achalasia of the cardia causes both a loss of the normal peristaltic contractions of the oesophagus and the failure of the normotensive lower oesophageal sphincter to relax, therapeutic measures can, at the present time, be directed only towards the latter defect by attempting to disrupt the fibres of the lower oesophageal sphincter, either by forced dilatation or cardiomyotomy.

After Thomas Willis's first description in 1674 of oesophageal dilatation using a length of whalebone with a sponge tip, the method progressed to the use of mercury-filled bougies, which, because they fail to rupture the lower sphincter, were of temporary benefit only. Further development to the use of expanding bags proved successful by forcefully dilating the lower oesophagus, rupturing the fibres of the sphincter while leaving the mucosa intact. Several types of dilator are available, making use of hydrostatic or pneumatic pressure using one or a series of graduated instruments, introduced over a guide wire or under fluoroscopic control.¹ Cardio-

myotomy, introduced by Heller in 1913, was slow to gain popularity, but its use is now widespread in one of its modifications, with or without an anti-reflux procedure, almost, in Great Britain, to the exclusion of forced dilatation.

This paper describes the experience of a district general hospital in the management of achalasia of the cardia by forced pneumatic dilatation over the past 10 years.

Methods**PATIENTS**

Eighteen consecutive patients presenting with achalasia were studied, nine men and nine women. Their ages ranged from 26 to 78 years, with a mean of 47.8 years. The length of history at the time of presentation is shown in Table 1: 11 of the patients

Table 1 *Duration of symptoms*

	<i>Duration of symptoms (yr)</i>				
	<1	1-2	2-5	5-10	>10
No. of patients	5	6	1	2	3

* Present address and address for correspondence and requests for reprints: Dr A H Lishman, South Shields General Hospital, Harton Lane, South Shields, NE34 0PL.

Received for publication 23 October 1981

had symptoms of less than two years' duration, the shortest being two months. Four of the patients had histories of more than 10 years, the longest being over 22 years.

All but one of the patients complained of dysphagia (Table 2), although in only six of these was this total, the remainder having dysphagia for solids only. Only 11 had significant weight loss (more than 6 kg), while seven complained of pain, ranging from mild retrosternal or epigastric discomfort to severe retrosternal pain, not necessarily related to swallowing. Five patients complained of vomiting or regurgitation, while two other patients complained of nocturnal cough, thought to be due to aspiration.

Two patients had previously had a cardiomyotomy, one 10 years and one 22 years previously, but both had relapsed. Three had been dilated elsewhere, one with Eder Puestow dilators and two with mercury-filled bougies. One patient with a sigmoid oesophagus was diagnosed incidently at mass miniature radiography, having had dysphagia for solids for 11 years, but insufficiently severely for her to seek treatment.

PROCEDURE

Diagnosis was established radiologically, endoscopically, and, where possible, manometrically. A barium swallow examination established the presence of hold-up of the column of barium with the typical tapering appearance of the distal oesophagus seen in achalasia. The maximum diameter of the oesophagus in each case is shown in the Figure; in three patients the oesophagus was of normal diameter – that is, less than 20 mm – while 13 of the patients had a maximum diameter of 40 mm or greater. Three of the patients had sigmoid deformity of the oesophagus, but this was not considered to be a contraindication to forced dilatation, although some workers consider it to be so.²

Manometric studies were performed using a triple lumen tube with three distal orifices 50 mm apart, each perfused with normal saline at a rate of 1

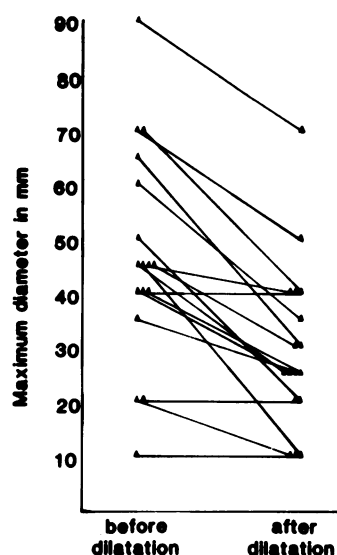


Figure Maximum diameter of oesophagus before and after dilatation in 17 patients with achalasia.

ml/min. Statham transducers and a Devices four-channel recorder converted the pressure into graphic form. Studies were attempted in 14 of the patients, but in three were incomplete because it was not possible to pass the tube through the lower oesophageal sphincter. The eleven successful studies all showed a normal or raised lower oesophageal sphincter pressure with incomplete relaxation in response to swallowing, and a loss of the normal peristaltic contractions of the body of the oesophagus. One patient showed high pressure non-peristaltic contractions and was considered to have 'vigorous' achalasia.

With the use of these methods it was possible to make a confident diagnosis of achalasia in all patients. This included two patients who had previously had a cardiomyotomy, a situation where distinction between stricture and achalasia may be difficult. In these patients the manometric and endoscopic appearances were typical, there being no resistance to the passage of the large endoscope through the sphincter region, at which the macroscopic appearances including those of the mucosa were normal.

The patients were subjected to oesophageal lavage on the day before dilatation, and, after an overnight fast, were premedicated with Omnopon, chlorpromazine, and atropine. With the patient lightly sedated with intravenous diazepam, the oesophagus was first examined using a forward-viewing fibroptic endoscope to assess the adequacy

Table 2 Symptoms at presentation

Symptoms	No.
Dysphagia	
Total	6
Solids only	11
Weight loss	11
Pain	8
Regurgitation	5
Aspiration	2

of preparation and to exclude organic disease. The instrument used for dilatation was a modified Browne McHardy oesophageal dilator (Pilling).³ This consists of a mercury-filled bougie with a radio-opaque hour glass balloon at its distal end, connected to an inflator and a pressure gauge. The instrument was inserted by mouth under fluoroscopic control until the waist of the balloon was seen to be at the gastro-oesophageal junction. The balloon was then inflated to a pressure of 15 psi and maintained for 15 seconds, observing by fluoroscopy that the waist of the balloon remained in the correct position while the narrow segment was obliterated, and the pressure then released. The balloon was then reinflated for a further 15 seconds. The patients clearly experienced discomfort at the time of maximum dilatation, this being relieved when the pressure was released.

After the procedure, the patients were returned to the ward for observation, and food and water were withheld until a chest radiograph performed later that day had excluded the presence of mediastinal air.

Results

The results of forced dilatation on these patients have been assessed for periods ranging from six months to 10 years, with a mean follow-up period of 4.2 years. Ten of the patients have remained asymptomatic (two for over 10 years) in that they eat an unrestricted diet without apparent hold-up or reflux, although one 79-year-old lady died after 10 months of unrelated disease. Six other patients (Table 3) have minimal symptoms only; four of these have occasional episodes of heartburn (less than one per week) but only one has radiological evidence of reflux. Two patients have rare episodes of dysphagia (less than once per month) but, on closer questioning, these patients were found to restrict their diet slightly by avoiding large boluses of meat, but were otherwise able to eat their meals at a normal rate. In one patient, dysphagia recurred after 14 months and, in the absence of organic stricture on endoscopy, the patient underwent

repeat pneumatic dilatation, but this patient is now well with only occasional episodes of reflux.

Of the remaining two patients, one has significant symptoms due to acid reflux associated with a fibrosed incompetent lower oesophageal sphincter, but these are well controlled by conventional medical therapy. The other patient developed recurrent dysphagia after six months and barium swallow and endoscopy revealed a benign stricture; the latter examination showed an abnormal mucosal appearance and narrowing of the lower oesophagus obstructing the passage of the endoscope. This required Eder Puestow dilatation and a good end result was obtained.

Radiological improvement was assessed by barium swallow at least six months after dilatation. The maximum diameter of the oesophagus was compared with that before dilatation (Figure). Apart from the three patients whose oesophagus was not significantly dilated originally, all showed a decrease in diameter, all but two having a diameter of 40 mm or less. The elderly patient who died did not have a barium swallow after dilatation. Abolition of hold-up of the column of barium was achieved in all but one patient, this being the patient who had required repeat forced dilatation. Only four of the patients have shown radiological evidence of reflux, three of these being asymptomatic.

Complications immediately following the procedure occurred in two patients, one of whom developed a pneumomediastinum which was managed conservatively, and one having a mild pyrexia associated with basal atelectasis. The mean length of stay in hospital after the procedure was 2.8 days, most of the younger patients being discharged on the day after the procedure. Only the two patients who developed complications remained in hospital for more than five days postoperatively.

Discussion

While forced dilatation in the management of achalasia is now an established method of treatment, its place compared with surgery is still the subject of some debate. Some feel that, because of the complications associated with forced dilatation and the decreasing possibility of successful surgery after repeated dilatations, surgical intervention should be the first line of treatment. Others feel that forced dilatation should be considered first in all but a few cases, in view of the large number who will obtain satisfactory relief without the need to subject the patient to time-consuming and potentially dangerous surgery.

There has been no controlled comparison of

Table 3 Results of forced dilatation

	Forced dilatation	
	No. of patients	%
Asymptomatic	10	55.5
Mild symptoms	6	33.3
Severe symptoms	2	11.2

forced dilatation with cardiomyotomy, and individual series are difficult to compare because of the variety of methods available for forced dilatation and the different criteria used to assess the success of a particular method. The overall results for the two methods would appear to be very similar, ranging between 80% and 89% for cardiomyotomy⁴⁻⁹ and 65% and 90% for dilatation,^{1 4 9-11} the better results occurring where dilatation was performed under fluoroscopic control, which we feel is important for ensuring good results.

Those in favour of early surgery cite the high incidence of complications associated with forced dilatation as a contraindication, but, in fact, these occur in fewer than 6% of cases.^{1 4 9-11} Perforation of the oesophagus occurs in approximately 4% of cases, and can usually be managed conservatively, particularly if oesophageal toilet precedes dilatation and if perforation is sought early in the procedure. The incidence of radiological reflux is variably reported in 3% to 20% of patients, but many of these are asymptomatic and develop no further complications. When severe, reflux oesophagitis may cause fibrosis with stricture formation, making subsequent surgery difficult, although the stricture may be successfully treated by conservative methods, as in our patient. After cardiomyotomy, reflux may be demonstrated in up to 50% of cases¹² unless an anti-reflux procedure is included in the operation.^{13 14} The recurrence of dysphagia varies from 3% to 20% but this can be treated by repeated forced dilatation. If dysphagia recurs after three pneumatic dilatations, however, surgery would appear to be indicated, as further dilatation increases fibrosis and makes the possibility of successful surgery less likely.^{2 15}

Forced dilatation has several advantages over cardiomyotomy: it is a short, relatively atraumatic procedure which can be performed under sedation, avoiding the morbidity and mortality associated with thoracotomy. This makes it particularly suitable for the older patient, even where a previous cardiomyotomy has been performed, providing fibrosis is excluded by prior endoscopy. The outcome of the procedure may be assessed immediately, as the patient may take a normal diet on the day after the procedure, and indeed, most patients can be discharged home within 24 hours.

In conclusion, it would seem that the management of achalasia will remain controversial, the method used depending on the expertise of the medical

attendant and the facilities available. However, our experience, while admittedly working with small numbers, suggests that there is an important place for forced pneumatic dilatation under fluoroscopic control as the first-line management of achalasia of the cardia, offering as it does a relatively minor procedure with a short hospital stay, a low incidence of complications, and ease of repetition in the event of inadequate results.

References

- 1 Bennett JR, Hendrix TR. Treatment of achalasia with pneumatic dilatation. *Mod Treatment* 1970; **7**: 1217-28.
- 2 Nanson EM. Treatment of achalasia of the cardia. *Gastroenterology* 1966; **51**: 236-41.
- 3 Browne DC, McHardy G. A new instrument for use in esophagospasm. *JAMA* 1939; **113**: 1963-4.
- 4 Benedict EB. Bouginage, forceful dilatation and surgery in the management of achalasia. *JAMA* 1964; **188**: 355-7.
- 5 Ellis FH, Kiser JC, Schlegel JF, Earlam RJ, McVey JL, Olsen AM. Esophagomyotomy of esophageal achalasia: experimental, clinical and manometric aspects. *Ann Surg* 1968; **166**: 640-56.
- 6 Ferguson TB, Burford TH. An evaluation of the modified Hellers operation in the treatment of achalasia of the esophagus. *Ann Surg* 1960; **152**: 1-9.
- 7 Jekler J, Lhotka J, Berek Z. Surgery for achalasia of the esophagus. *Ann Surg* 1964; **160**: 793-800.
- 8 Yon J, Christensen J. An uncontrolled comparison of treatments for achalasia. *Ann Surg* 1975; **182**: 672-6.
- 9 Kurlander DJ, Rankin HF, Kirsner JB, Palmer WL. Therapeutic value of the pneumatic dilator in achalasia of the esophagus. *Gastroenterology* 1963; **45**: 604-13.
- 10 Sanderson DR, Ellis FH, Olsen AM. Achalasia of the esophagus: result of therapy by dilatation. *Chest* 1970; **58**: 116-21.
- 11 Vantrappen G, Hellemans J, DeLoof W, Valembois P, Vandenbrouke J. Treatment of achalasia with pneumatic dilatation. *Gut* 1971; **12**: 268-75.
- 12 Hawthorne HR, Froese AS, Nemir P. The surgical management of achalasia of the esophagus. *Ann Surg* 1956; **144**: 653-69.
- 13 Mansour KA, Symbas PN, Jones EL, Hatcher CR. A combined surgical approach in the management of achalasia of the esophagus. *Am Surg* 1976; **42**: 192-5.
- 14 Black J, Vorbach AN, Leigh Collins J. Results of Hellers operation for achalasia of the oesophagus. The importance of hiatal repair. *Br J Surg* 1976; **63**: 949-53.
- 15 Heimlich HJ, O'Connor TW, Flores DC. Cases for pneumatic dilatation in achalasia. *Ann Otol* 1978; **87**: 519-22.