

What is the significance of pancreatic ductal mucinous hyperplasia?

T G ALLEN-MERSH

From the Charing Cross Hospital, London

SUMMARY The prevalence, distribution, and clinical associations of pancreatic ductal mucinous hyperplasia were studied in 102 non-malignant pancreases. Ductal mucinous hyperplasia was found in over 60% of specimens and was frequently associated with increased fibrosis – occasionally resembling pancreatitis. Significantly more ductal mucinous hyperplasia was found in pancreas from patients who were receiving corticosteroid treatment. Neither a history of hypercalcaemia in the three months before death, diabetes mellitus, alcoholism, tobacco smoking, nor the presence of gall stones was associated with an increase in ductal mucinous hyperplasia. The age of maximum prevalence, and the distribution of ductal mucinous hyperplasia in the pancreas were similar to those of pancreatic carcinoma. These similarities may be because both ductal mucinous hyperplasia and pancreatic carcinoma are proliferative responses, rather than because ductal mucinous hyperplasia is a precursor of pancreatic carcinoma.

Alterations in the normal morphology of pancreatic ductal epithelium were first described by Priesel in 1922.¹ In 1954 Sommers *et al*² described two patterns of mucinous epithelial change: papillary change in the mucosal lining of larger pancreatic ducts, and 'adenomatous ductular proliferation' (hereafter referred to as ductular metaplasia, see below) of smaller ducts. In this and subsequent studies (summarised in Table 1) the prevalence of ductal mucinous hyperplasia adjacent to pancreatic carcinoma was compared with that in non-malignant pancreas by histological examination, retrospectively, of blocks of tissue which had previously been taken at routine autopsy. Some of these studies suggested that ductal mucinous hyperplasia, particularly the papillary form, occurred more frequently in association with pancreatic carcinoma. Most, however, were limited by their retrospective design and the small number of tissue blocks examined.

This association with malignancy has also been suggested by organ culture experiments where, after exposure to the carcinogen dimethylnitrosamine, human pancreatic explants develop changes resembling ductal mucinous hyperplasia.⁷ The reason for this possible association with pancreatic carcinoma is not known. It has been suggested that ductal

mucinous hyperplasia might be a precursor of pancreatic carcinoma,² but this malignant association could not be very significant if it is also a common finding in the non-malignant pancreas – as suggested in some of the studies shown in Table 1. An alternative explanation could be that ductal mucinous hyperplasia represents a metaplastic response to a variety of unidentified proliferative stimuli. Thus the increased prevalence of ductal mucinous hyperplasia in association with pancreatic cancer could be the result of incidental damage produced by the expanding tumour on adjacent pancreas.

The view that ductal mucinous hyperplasia could be a metaplastic change is compatible with the changes in mucin chemistry which are associated with ductal mucinous hyperplasia. Mucin in ductal mucinous hyperplasia is not sulphated, unlike in the normal pancreatic duct epithelium.⁸ It resembles mucin found in normal juxta pyloric glands and in metaplastic mucinous glands associated with atrophic gastritis,⁹ chronic cholecystitis,¹⁰ and small bowel Crohn's disease.¹¹

Although attempts have been made to identify ductal mucinous hyperplasia *in vivo* by pancreatography¹² and by pancreatic juice cytology,¹³ these have not provided information about its natural history. Thus estimates of the prevalence of ductal mucinous hyperplasia in the non-malignant pancreas

Address for correspondence: Mr T G Allen-Mersh, MD, FRCS, Senior Surgical Registrar, The London Hospital, Whitechapel, London E1 1BB.

Received for publication 21 September 1984.

Table 1 Prevalence of papillary (papill) ductal mucinous hyperplasia (DMH) and ductular metaplasia (duct met) in pancreas taken from cases of pancreatic cancer and in non-malignant pancreas taken at autopsy.

Cases (no)	Prevalence of DMH %				Ref		
	Pancreatic cancer	No pancreatic cancer	Pancreatic cancer			No pancreatic cancer	
			Papill	Duct met		Papill	Duct met
141	150	41*		9*		2	
227	100	37	35	12	28	3	
27	1053	59.3	81.5	9.9	21.5	4	
21	46	49	58	10	56	5	
—	83	—	—	57	39	6	

* No distinction between papillary DMH and ductular metaplasia was made in this study.

are conflicting (Table 1), and little is known of its distribution within the pancreas, the stimulus to its development, its natural history and the significance of its presence in the non-malignant pancreas.

The present study had two purposes: first to establish the prevalence and distribution of ductal mucinous hyperplasia within the non-malignant pancreas by histological examination of tissue taken from predetermined sites throughout the pancreas. Second, to attempt to identify the stimulus to production of ductal mucinous hyperplasia in the non-malignant pancreas by correlating the amount of ductal mucinous hyperplasia seen with factors which have been reported as affecting the pancreas: diabetes mellitus,¹⁴ gall stones,¹⁵ excess alcohol intake,¹⁶ corticosteroid treatment,¹⁷ hypercalcaemia;¹⁸ and with cigarette smoking which predisposes to pancreatic carcinoma.¹⁹

Methods

SPECIMENS

Pancreas was obtained at necropsy, carried out within 48 hours of death, on patients who had died of non-pancreatic diseases. The pancreas was removed in a block including the pylorus, duodenum, distal bile duct, and spleen. The tip of the tail of the pancreas was incised and a 1.1 mm (outside diameter) 'Medicut' cannula inserted into the pancreatic duct. One millilitre of a solution of 10% formalin, containing 1% crystal violet dye, was then injected to fix the tissue and outline the ducts (required for another study). The pancreas and duodenum were then pinned on cork and immersed in 5 litres of 10% buffered (pH 7.2) formalin for five days. Blocks of tissue were taken from five predetermined sites in the head and neck of the pancreas and five sites in the body and tail, and stained with haematoxylin and eosin. Each section was examined at $\times 25$ magnification under a microscope fitted with

an eyepiece graticule which outlined an area of 21.2 sq mm.

TERMINOLOGY

The term 'adenomatous ductular proliferation'² may be misleading because it implies a neoplastic process. The histological appearances (see Figs. 1 and 2) suggest a metaplasia of acini into ductules. The term 'ductular metaplasia' is a better description and this has been used throughout. The term papillary ductal mucinous hyperplasia² is an accurate morphological description, and this has been adhered to.

The amount of ductal mucinous hyperplasia seen in one area of the graticule was given a score as follows; no ductal mucinous hyperplasia = 0, ductular metaplasia or papillary ductal mucinous hyperplasia = 1, both ductular metaplasia and papillary ductal mucinous hyperplasia = 2. A hyperplasia 'score' for the whole pancreas was obtained by adding the scores for each graticule area and dividing by the number of graticule areas examined. The hyperplasia score for the head and neck or the body and tail only, was similarly calculated for the relevant areas.

Information about all variables was not available in every case, so the number of cases in each analysis varies slightly.

Results

One hundred and two specimens were obtained. In each specimen, one section taken from each of the 10 tissue blocks, containing an average of seven graticule areas (range 1–9) per section, was examined.

APPEARANCE

Ductal mucinous hyperplasia had a focal distribution affecting part or the whole of a pancreatic

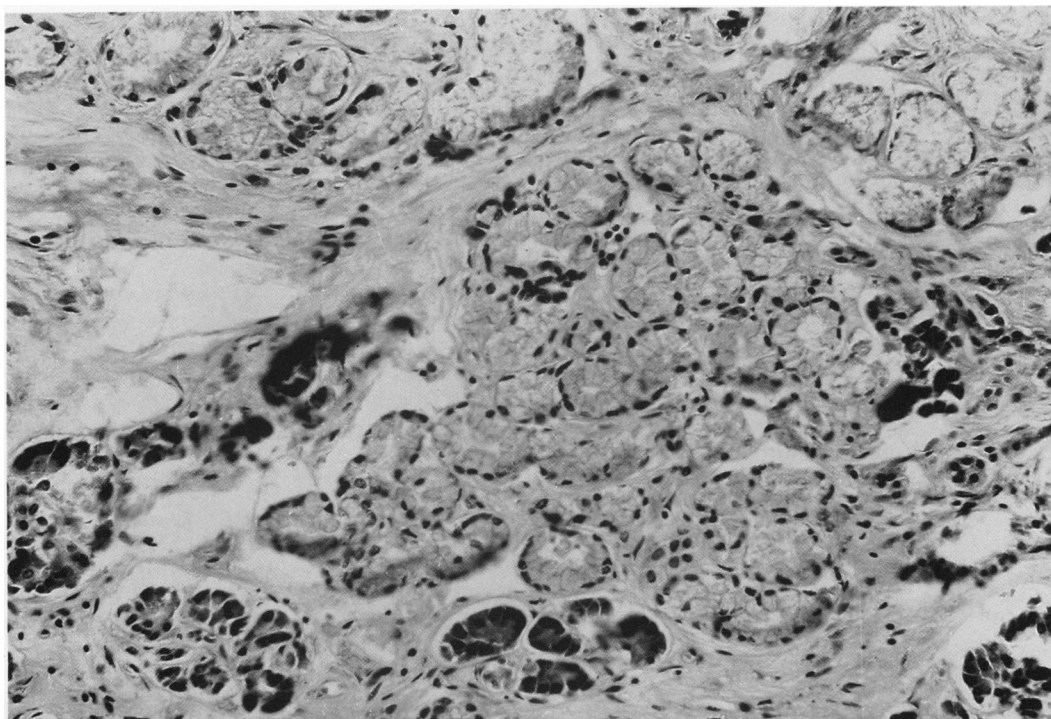


Fig. 1 Ductular metaplasia. (H&E $\times 160$ original magnification).

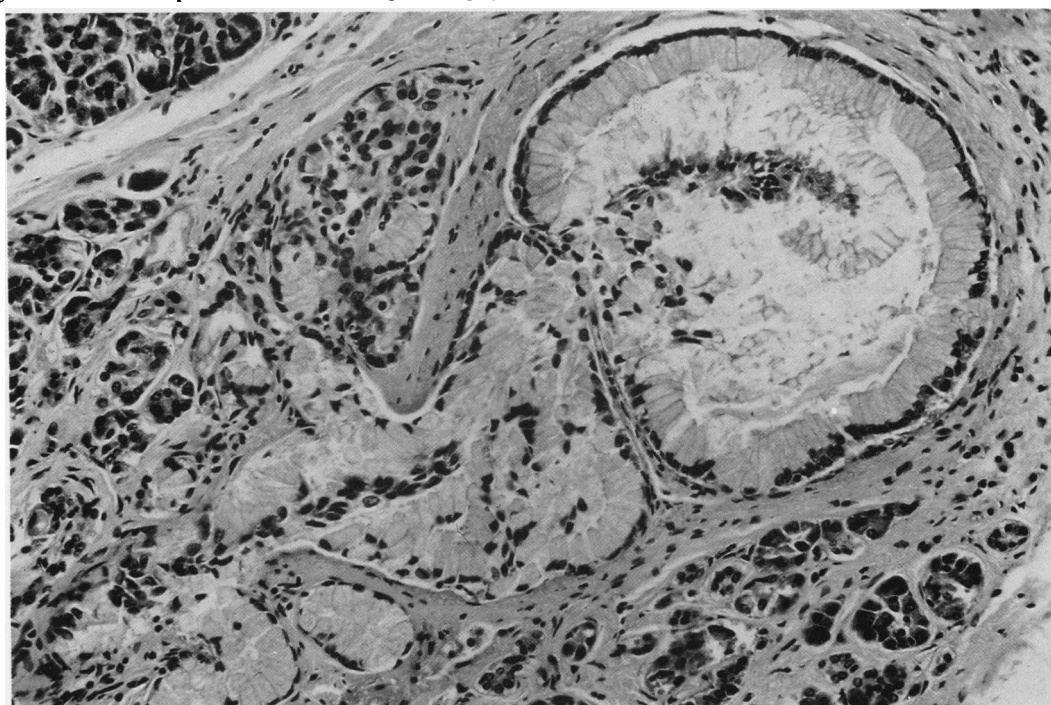


Fig. 2 In the majority of cases both papillary ductal mucinous hyperplasia and ductular metaplasia were found adjacent to each other. (H&E $\times 160$ original magnification).

lobule while surrounding lobules were less affected (Fig. 3). In larger ducts, the mucinous epithelium was arranged either in a papillary pattern (Fig. 4) or in the form of an increase in the number of small pouches which are occasionally found in the lining of a normal pancreatic duct (Figs. 5 and 6). Elsewhere areas of tightly packed ductular metaplasia, lined with mucinous epithelium (Fig. 1), were found. In 51% of cases in which ductal mucinous hyperplasia was seen, both papillary ductal mucinous hyperplasia and ductular metaplasia were found adjacent to each other (Fig. 2). Ductular metaplasia alone (Fig. 1) was seen in 33% of pancreases containing ductal mucinous hyperplasia, and papillary ductal mucinous alone (Fig. 4) was found in 16% of affected cases. In most sections there was an increase in the amount of fibrous tissue seen near areas of ductal mucinous (Fig. 3); occasionally this became so marked as to suggest chronic pancreatitis (Fig. 7).

PREVALENCE

Ductal mucinous hyperplasia was found in 62%

(63/102) of the cases examined. There was no significant difference between the prevalence in men (33/55) and that in women (30/47).

The hyperplasia score in pancreas from patients by age at death is shown in Figure 8. There was a significant increase (Wilcoxon's test $p < 0.05$) in the amount found in pancreas from patients aged more than 60 years at death compared with that found in patients aged less than 60 years at death.

DISTRIBUTION WITHIN THE PANCREAS

The ratio of the mean hyperplasia score for the head and neck of the pancreas compared with the body and tail was 1.4/1. There was a significant increase (paired t test $p < 0.05$) in the amount of ductal mucinous hyperplasia found in the head and neck of the pancreas compared with the body and tail.

ASSOCIATED FACTORS

The amount of ductal mucinous hyperplasia found in pancreas from patients taking corticosteroids was significantly greater (Wilcoxon's test $p < 0.05$) than in patients not taking corticosteroids. The increase

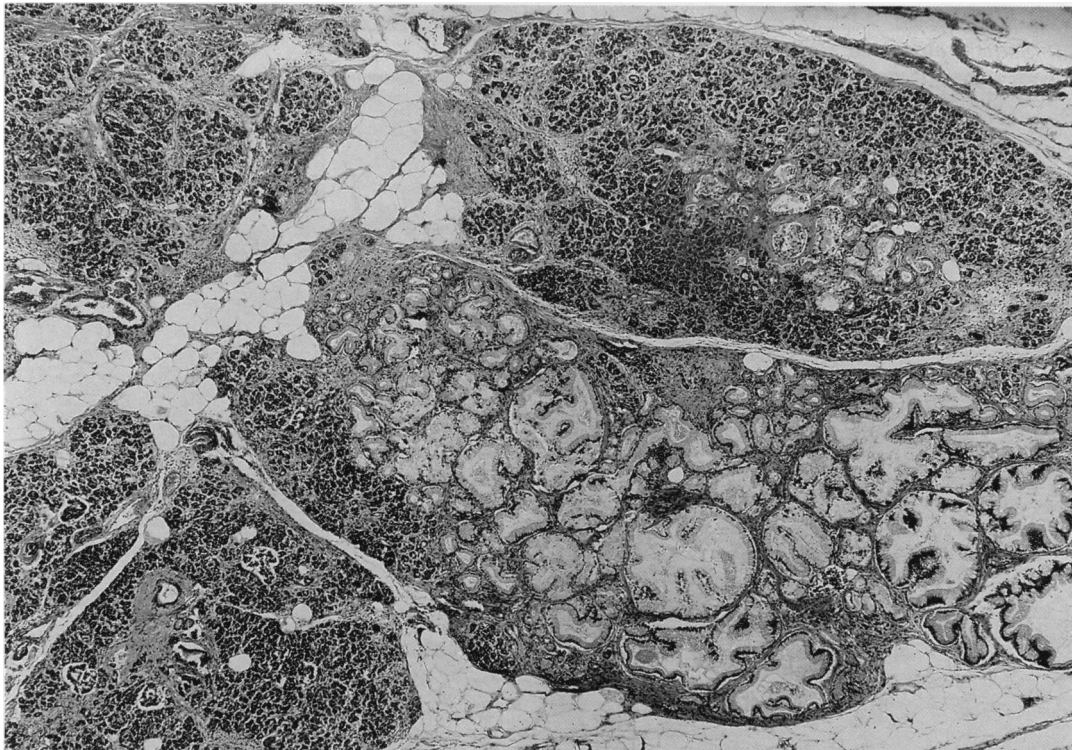


Fig. 3 Entire lobule and part of an adjacent lobule affected by ductal mucinous hyperplasia. There is increased fibrosis in the intralobular septa of adjacent lobules (H&E $\times 25$ original magnification).

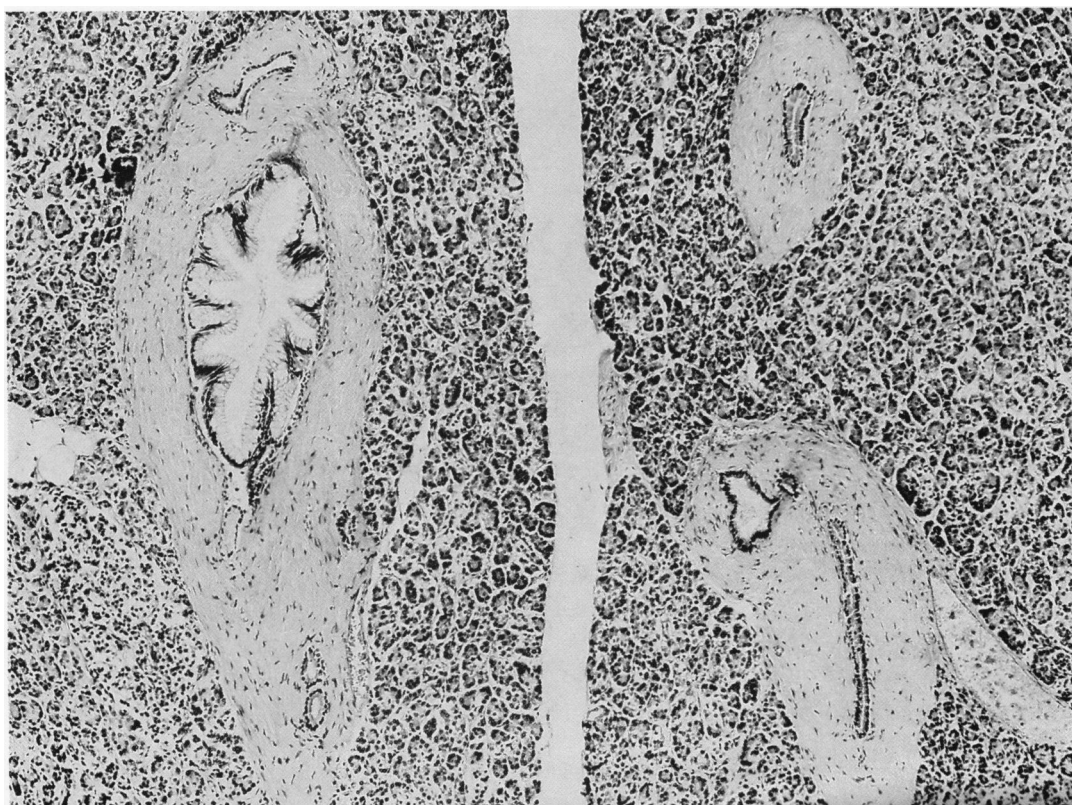


Fig. 4 Papillary ductal mucinous hyperplasia affecting an intralobular duct which is adjacent to normal acinar tissue and ducts. (H&E $\times 63$ original magnification).

appeared to be in patients taking steroids to control symptoms of disseminated cancer (Fig. 9). Overall there was no significant difference in the amount of ductal mucinous hyperplasia found in patients with cancer compared with non-cancer patients.

Neither a history of hypercalcaemia in the three months before death, diabetes mellitus, alcoholism, tobacco smoking, nor the presence of gall stones in the biliary tract were associated with a significant increase in the amount of ductal mucinous hyperplasia (Table 2).

Discussion

There were similarities in the prevalence and distribution of ductal mucinous hyperplasia in the non-malignant pancreas and the incidence and distribution of pancreatic exocrine adenocarcinoma.

Firstly, ductal mucinous hyperplasia was found in significantly greater amounts in the head and neck of the pancreas compared with the body and tail (ratio of 1.4:1). This would be unlikely to be

because of anatomical differences between different areas of the pancreas.²⁰ It has previously been

Table 2 Prevalence and amount of ductal mucinous hyperplasia (DMH) in association with different clinical factors. There was a significant ($p < 0.05$) increase in the amount of DMH found in pancreases from patients taking steroids.

	Prevalence of DMH		Hyperplasia score of pancreas (median)
	Proportion of involved cases	%	
No steroids	41/74	55%	0.017
Steroids	22/28	79%	0.06
No diabetes mellitus	56/92	61%	0.035
Diabetes mellitus	7/10	70%	0.04
No gall stones	48/77	62%	0.036
Gall stones	12/17	71%	0.037
No cancer history	30/53	57%	0.012
Cancer history	32/48	67%	0.048
Non-smokers	28/45	62%	0.043
Smokers	33/54	61%	0.023
No hypercalcaemia	34/58	59%	0.025
Hypercalcaemia	20/30	67%	0.038

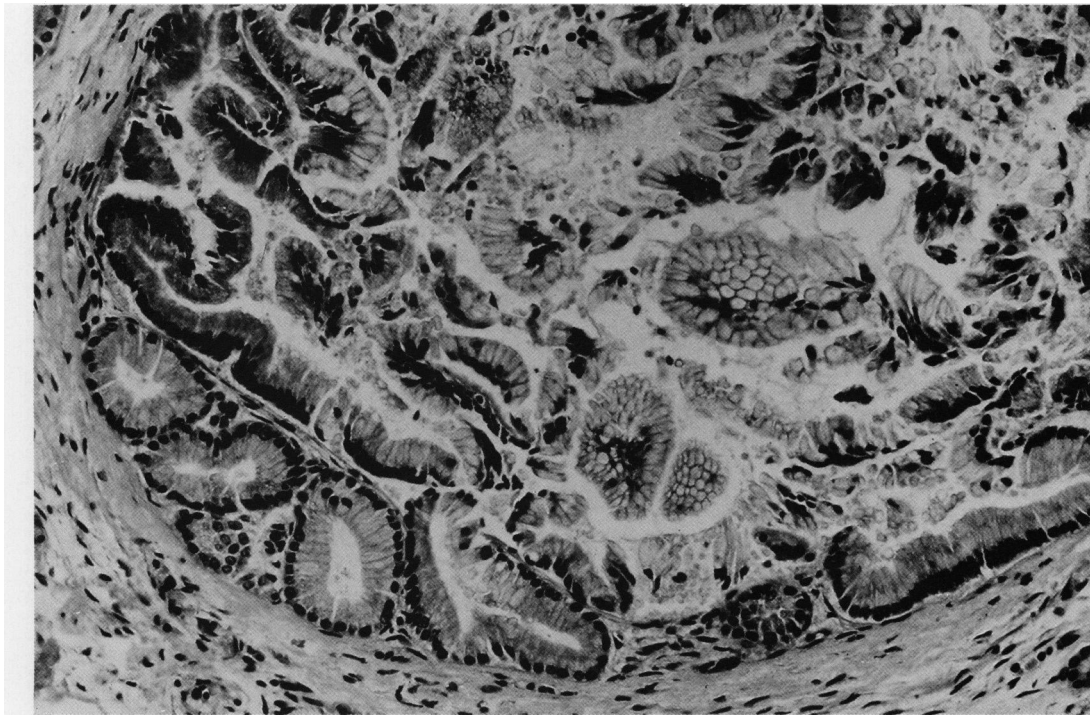
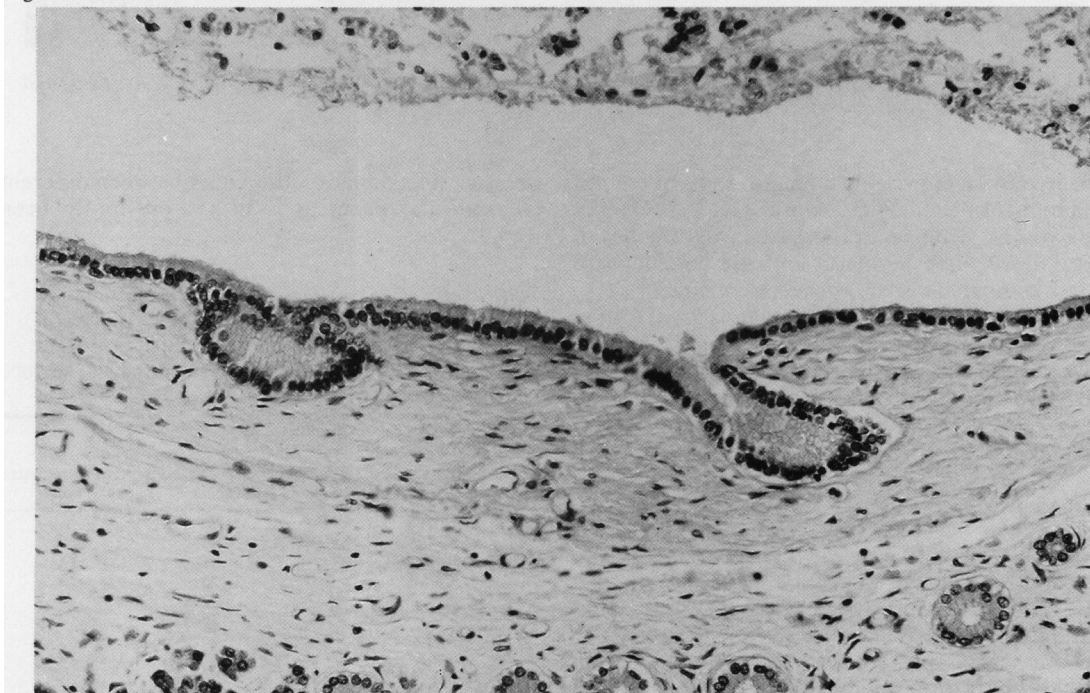


Fig. 5



Figs. 5 and 6 *Papillary ductal mucinous hyperplasia associated with a proliferation of the pouches (Fig. 5) which were occasionally seen in the wall of a normal interlobular duct (Fig. 6). (H&E $\times 160$ original magnification).*

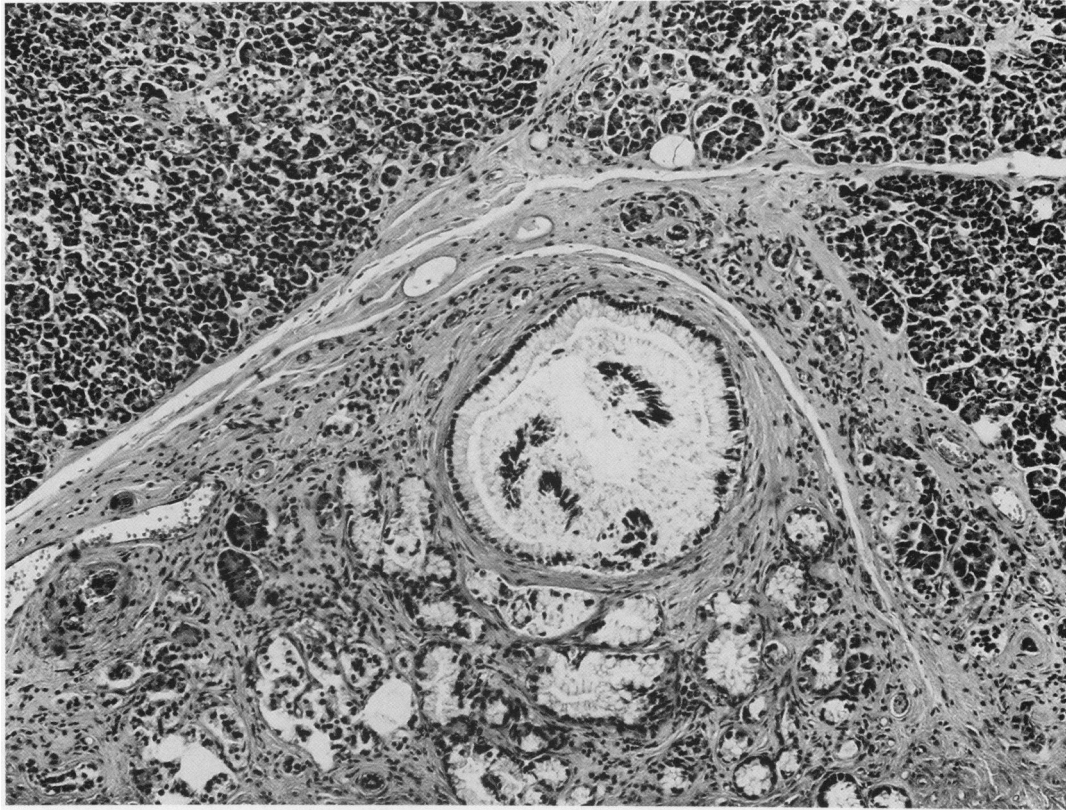


Fig. 7 Interlobular duct showing the changes of ductal mucinous hyperplasia surrounded by fibrosis which has replaced acinar tissue. (H&E $\times 88$ original magnification).

suggested that the incidence of pancreatic carcinoma is 1.8 times as great in the head and neck of the pancreas as in the body and tail.²⁰

Secondly, the increase in the amount of ductal mucinous hyperplasia in patients aged more than 60 years is in keeping with the marked tendency for pancreatic carcinoma to occur in older people.²¹ The similarities between ductal mucinous hyperplasia in the non-malignant pancreas and pancreatic carcinoma in age of onset and distribution are not consistent with the view that the association between ductal mucinous hyperplasia and pancreatic carcinoma is merely the result of local damage produced by the expanding tumour on adjacent pancreas.

Ductal mucinous hyperplasia was, however, found in over 60% of pancreases taken from patients with no history of pancreatic disease. The alternative view, that ductal mucinous hyperplasia may be a precursor of pancreatic carcinoma, would mean that the chance of progression from ductal

mucinous hyperplasia to malignancy is very small. A more likely explanation for these findings is that ductal mucinous hyperplasia and pancreatic carcinoma are unrelated responses to proliferative stimuli.

One stimulus to the development of ductal mucinous hyperplasia which was identified was treatment with corticosteroids. This was not noted in a previous histological study of pancreas from patients with chronic diseases taking long term steroids.²² In the present study, the increase appeared to be mainly in patients receiving high dose steroids as treatment for a variety of malignancies. Steroids are sometimes used in large doses in malignant disease to control hypercalcaemia, which occasionally results in pancreatitis.¹⁸ Neither the presence of malignancy nor hypercalcaemia, however, appeared to be the causative factor because no significant relationship was shown between either of these and ductal mucinous hyperplasia. The stimulus to the development of ductal mucinous hyperplasia exerted by steroids might be damage to the

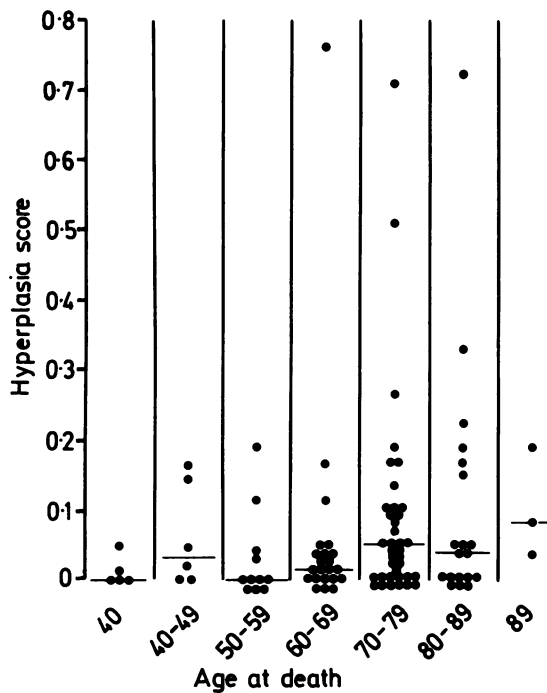


Fig. 8 Amount of ductal mucinous hyperplasia seen by age at death. Horizontal line indicates the median. There was a significant ($p < 0.05$) increase in the amount found in pancreas from patients aged more than 60 years at death compared with those aged less than 60 years at death.

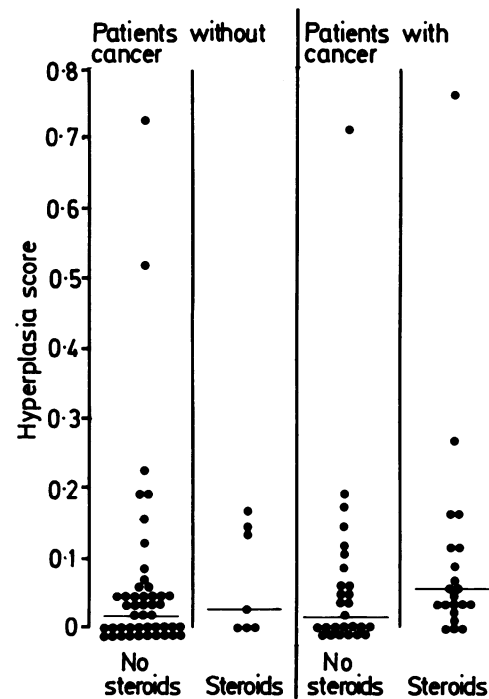


Fig. 9 Amount of ductal mucinous hyperplasia seen in patients with and without cancer by history of steroid intake. Horizontal line indicates the median. There was a significant ($p < 0.05$) increase in the amount of hyperplasia in patients taking steroids. This seemed to be mainly in cancer patients taking steroids.

pancreatic ductal mucosa either because of a steroid-induced increase in pancreatic secretory pressure²³ or because of reduced mucosal resistance to damage, as elsewhere in the gastrointestinal tract.²⁴

Steroids did not appear to be the only cause of ductal mucinous hyperplasia. Although present in smaller amounts (an average of one-third the amount seen in association with steroids, see Table 2), ductal mucinous hyperplasia was found in 55% of patients with no history of steroid ingestion. No cause for this ductal mucinous hyperplasia was identified. The failure to detect an association between ductal mucinous hyperplasia and a history of alcoholism or the presence of gall stones may be because these conditions damage the pancreas in only a small proportion of cases.^{25 26} Ductal mucinous hyperplasia has previously been found in association with chronic pancreatitis.¹⁶ These findings suggest that ductal mucinous hyperplasia is not stimulated primarily by excess alcohol consumption or by the presence of gall stones but is a secondary

non-specific response to damage. Similarly in diabetes mellitus, where no association with ductal mucinous hyperplasia was identified; a prolonged history is associated with a progressive decline in pancreatic exocrine function¹⁴ but not with inflammatory change.²⁷

Ductal mucinous hyperplasia therefore appears to represent a hyperplastic and metaplastic response by pancreatic duct and adjacent acinar cells to a variety of stimuli, including treatment with corticosteroids. These stimuli could act by damaging both the pancreatic duct epithelium and adjacent acini thereby stimulating a proliferative response. The similarities between ductal mucinous hyperplasia in the non-malignant pancreas and pancreatic carcinoma in age of onset and distribution may arise because both are responses to proliferative stimuli rather than because ductal mucinous hyperplasia is a precursor of pancreatic carcinoma.

I am indebted to Dr Bernard Fox, Department of Histopathology, Charing Cross Hospital, for helpful

advice and criticism, to Mrs Maureen Stanford who prepared the histology, and to Miss Marion Hudson for the photomicrographs. This work was supported by a grant from the NW Thames Regional Research Committee.

References

- 1 Priesel A, Beitrage zur Pathologie der Bauchspeicheldruse. *Frankfurt Z Pathol* 1922; **26**: 453–518. [In German].
- 2 Sommers SC, Murphy SA, Shields W. Pancreatic duct hyperplasia and cancer. *Gastroenterology* 1954; **27**: 629–40.
- 3 Cubilla AL, Fitzgerald PJ. Morphological lesions associated with human primary invasive non-endocrine pancreas cancer. *Canc Res* 1976; **36**: 2690–8.
- 4 Koszuka S. Pathogenesis of duct hyperplasia in the pancreas. *Digestion* 1980; **20**: 234–47.
- 5 Kloppel G, Bommer G, Ruckert K, Siefert G. Intraductal proliferation in the pancreas and its relationship to human and experimental carcinogenesis. *Virchows Arch [Pathol Anat]* 1980; **387**: 221–33.
- 6 Pour PM, Sayed S, Sayed G. Hyperplastic, pre-neoplastic and neoplastic lesions found in 83 human pancreases. *Am J Clin Pathol* 1982; **77**: 137–52.
- 7 Parsa I, Marsh WH, Sutton AL. An in vitro model of human pancreas carcinogenesis. *Cancer* 1981; **47**: 1543–51.
- 8 Roberts PF, Burns J. A histochemical study of mucins in normal and neoplastic human pancreatic tissue. *J Pathol* 1972; **107**: 87–94.
- 9 Morson BC. The stomach. In: Symmers W StC, ed. *Systematic pathology*. Vol. 3. London: Churchill Livingstone, 1978: 1039–52.
- 10 Esterly JR, Spicer SS. Mucin histochemistry of human gall bladder. Changes in adenocarcinoma, cystic fibrosis and cholecystitis. *J Natl Canc Inst* 1968; **40**: 1–11.
- 11 Liber AF. Aberrant pyloric glands in regional ileitis. *Arch Pathol* 1951; **51**: 205–212.
- 12 Birnstingl M. A study of pancreatography. *Br J Surg* 1959; **47**: 128–39.
- 13 Butler EB, Smithies A. Pancreatic cytology. In: Howart HT, Sarles H, eds. *The exocrine pancreas*. Philadelphia: Saunders, 1979: 299–309.
- 14 Frier BM, Faber OK, Binder C, Elliott HL. The effect of residual insulin secretion on exocrine pancreatic function in juvenile onset diabetes mellitus. *Diabetologia* 1978; **14**: 301–4.
- 15 MRC Multicentre Trial Study Group. Death from acute pancreatitis. MRC multicentre trial of glucagon and aprotinin. *Lancet* 1977; **2**: 632–5.
- 16 Sarles H. Chronic calcifying pancreatitis-chronic alcoholic pancreatitis. *Gastroenterology* 1974; **66**: 604–18.
- 17 Nakashima Y, Howard JM. Drug-induced acute pancreatitis. *Surg Gynecol Obstet* 1977; **145**: 105–9.
- 18 Goeball H. The role of calcium in pancreatic secretion and disease. *Acta Hepato-Gastroenterol* 1976; **23**: 151–62.
- 19 Hammond EC. Smoking in relation to the death rates of one million men and women. In: Epidemiological approaches to the study of cancer and other chronic diseases. *Natl Cancer Inst Monogr* 1966; **19**: 127–204.
- 20 Allen-Mersh TG. Significance of the site of origin of pancreatic exocrine adenocarcinoma. *J Clin Pathol* 1982; **35**: 544–6.
- 21 Aoki K, Ogawa H. Cancer of the pancreas. International mortality trends. *WHO Stat Rep* 1978; **31L**: 2–27.
- 22 Carone FA, Liebow AA. Acute pancreatic lesions in patients treated with ACTH and adrenal corticoids. *N Engl J Med* 1957; **257**: 690–7.
- 23 Bourry J, Sarles H. Influence de la corticothérapie prolongée sur la sécrétion pancréatique externe de l'homme. *Gastroenterol Clin Biol* 1978; **2**: 139–44. [In French].
- 24 Kowalewski K, Strutz WA. Uptake of radiol sulphate by the gastric tissue and gastric secretion in cortisone-treated Shay rats. *Acta Endocrinol* 1959; **31**: 107–12.
- 25 Sobel HJ, Waye JD. Pancreatic changes in various types of cirrhosis in alcoholics. *Gastroenterology* 1963; **45**: 341–4.
- 26 Erber WF, Lubowski E, Levij IS, Birnbaum D. Validity of the correlation of gall stones and pancreatic pathology. *Gut* 1972; **13**: 996–99.
- 27 Durr GHK. Acute pancreatitis. In: Howart HT, Sarles H, eds. *The exocrine pancreas*. Philadelphia: Saunders, 1979: 364–5.