

Same peculiar subset of HML1+ lymphocytes present within normal intestinal epithelium is associated with tumoral epithelium of gastrointestinal carcinomas

A JARRY, N CERF-BENSUSSAN, N BROUSSE, D GUY-GRAND, F MUZEAU, AND F POTET

From INSERM U239, Faculté de Médecine Xavier Bichat, Paris, France and INSERM U132, Hôpital des Enfants Malades, Paris, France

SUMMARY The present study shows that the distribution of T lymphocytes in gastrointestinal carcinomas and their metastases mimic the distribution of T lymphocytes in normal intestine. The composition of the peritumoral reaction resembled that of normal lamina propria with a predominance of CD3+ CD4+ T cells. In contrast, lymphocytes located between carcinomatous cells showed phenotypical features similar to those of intraepithelial lymphocytes (IEL) in normal intestine; in particular they expressed the antigen defined by HML-1, a monoclonal antibody raised against normal human intestinal IEL which reveals 95% IEL but very few cells in lymphoid organs and blood. As normal intestinal IEL, the majority of intratumoral lymphocytes had the CD3+ CD8+ phenotype. A panel of monoclonal antibodies and double immunostaining techniques permitted a better characterisation of minor subsets of IEL. Two subsets of HML1+ CD3+ CD4- CD8- and of HML1+ CD3- cells, representing 2% and 3% of normal intestinal IEL respectively, did not significantly increase in carcinomatous epithelium. In contrast, in carcinomatous epithelium, but not in normal intestinal epithelium, we observed the appearance of a few lymphocytes displaying the phenotype of activated T cells (CD25+) or of natural killer cells (NKHI+) or of suppressor cells (CD11+). Such cells may participate in antitumoral defence. Although a similar population of HML1+ lymphocytes is associated with normal and carcinomatous intestinal epithelium, some interactions between lymphocytes and epithelial cells may not be maintained in tumoral epithelium. It has previously been shown that HLA-DR expression by enterocytes is modulated by intraepithelial lymphocytes. In our study, no correlation could be shown between the degree of lymphocytic infiltration and the expression of HLA-DR antigens on carcinomatous cells.

Lymphocytes associated with normal human small intestine represent a unique lymphoid population. In contrast with T lymphocytes in peripheral lymphoid organs and in gut lamina propria, most of human gut intraepithelial lymphocytes (IEL) express the cytotoxic/suppressor phenotype of T cells (CD3+ CD8+); approximately 25% of human IEL contain intracytoplasmic granules rich in sulphated muco-

polysaccharides.¹⁻⁴ In addition, it has been recently shown that human normal IEL express a specific membrane antigen defined by the monoclonal antibody HML1.⁵ This antigen is absent on lymphocytes of lymphoid organs and peripheral blood, whereas it is present on over 95% of the IEL in normal human gut, and on a smaller number of lamina propria T lymphocytes.⁵

In this study, using HML1 and a panel of monoclonal antibodies, we compared the phenotype of lymphocytes present in the tumoral epithelium of

Address for correspondence: A Jarry, INSERM U239, Faculté de Médecine Xavier Bichat, 16, rue Henri Huchard, 75018 Paris, France.

Received for publication 1 June 1988.

gastrointestinal carcinomas and their liver metastases with the phenotype of normal intestinal IEL, and with the phenotype of the lymphocytes present in normal lamina propria and in the peritumoral reaction of carcinomas.

The function of IEL is not well understood. Besides their possible role in the defence against intraluminal microorganisms, they may modulate some epithelial functions.^{6,7} Indeed, it has been shown that activated IEL are able to modulate the expression of class II molecules of the major histocompatibility complex on normal epithelial cells.⁶ In this study, we tried to define whether this interaction between IEL and epithelial cells is maintained in the tumoral epithelium.

Methods

TISSUE SPECIMENS

Thirty six surgical specimens of primitive gastrointestinal carcinomas were collected: 17 involved the stomach, 17 the colon, and two the rectum. All were adenocarcinomas, 30 being well differentiated and six poorly differentiated. The majority of all these cases involved all the gut layers, with or without regional lymph node invasion (Table 1).

Five liver metastases of well differentiated colic and rectal carcinomas were also examined.

In the carcinomas and their metastases, the lymphoid T cell and macrophage infiltrate was evaluated inside the carcinoma, between carcinomatous cells, and around the carcinoma, between the carcinomatous lobules.

Biopsies or surgical specimens of histologically normal stomach (five cases), small intestine (10 cases), colon and rectum (seven cases) served as controls.

TISSUE PROCESSING

Tissue samples were fixed in Bouin's solution,

Table 1 Depth of invasion of the 36 gastrointestinal carcinomas

Localisation of carcinoma	Mucosa	Submucosa	Muscularis propria	Serosa
Stomach (17 cases)	1*		5 2†; 3*	11 8†; 3*
Colon (17 cases)		2*	3 2†; 1*	12 4†; 8*
Rectum (2 cases)		1*		1*
Total	1	3	8	24

*: without regional lymph node metastases; †: with regional lymph node metastases.

Table 2 Monoclonal antibodies

Monoclonal antibody	Dilution	Source	Specificity
CD3 (Leu4)	1/100	Becton-Dickinson	T cells
CD4 (Leu3a)	1/100	Becton-Dickinson	Helper T cells; macrophages
CD8 (Leu2a)	1/100	Becton-Dickinson	Cytotoxic/suppressor T cells
CD11 (Leu15)	1/100	Becton-Dickinson	Suppressor T cells; natural killer cells; monocytes; granulocytes
HML1	1/500	(5)	Human intraepithelial lymphocytes
NKHI	1/200	Coultronics	Natural killer cells
LeuM5	1/100	Becton-Dickinson	Macrophages
CD25 (IL2-R)	1/100	Becton-Dickinson	Cells bearing the receptor for interleukin 2: activated T cells, macrophages
Anti-HLA-DR	1/100	Becton-Dickinson	B cells; activated T cells; macrophages; some epithelial cells
CD22 (PanB)	1/25	Dakopatts	B lymphocytes

embedded in paraffin paraplast, and stained according to routine histological procedures.

Small pieces of each specimen were snap frozen in isopentane cooled in liquid nitrogen. Cryostat sections, 5 µm thick, were fixed in acetone and stored at -20°C until use.

IMMUNOHISTOCHEMICAL TECHNIQUES

A three stage indirect immunoperoxidase method was applied on cryostat sections, as previously reported.⁸ The monoclonal antibodies used are listed in Table 2.

A double immunostaining technique, according to that of Mason and Sammons⁹ was carried out in the 22 normal controls and in 21 cases of the primitive carcinomas, in order to identify the different T lymphocyte subsets inside and around the carcinoma, or in the epithelium and in the lamina propria of normal controls. The first monoclonal antibody applied appeared in brown, the second in blue. This technique was used to detect the blue cells stained only with the second monoclonal antibody. The combinations of monoclonal antibodies used in double staining experiments are listed in Table 3.

ESTIMATE OF LABELLED CELLS

The degree of T cell infiltration inside and around the carcinomas was graded as null (-), mild (±), moderate (+), or heavy (++), at a ×100 magnification.

In double stained sections, the ratio of blue cells to

Table 3 Combinations of monoclonal antibodies used in double staining experiments

Monoclonal antibody 1 (brown)	Monoclonal antibody 2 (blue)	Phenotype of the blue cells
CD3	HML1	HML1+ CD3-
CD8	HML1	HML1+ CD8-
CD4	HML1	HML1+ CD4-
(CD4+CD8)	HML1	HML1+ CD4- CD8-
(CD4+CD8)	(CD3+HML1)	CD3+ HML1+ CD4- CD8-
HML1	CD3	CD3+ HML1-
HML1	(CD4+CD8)	CD4+ CD8+ HML1-
NKHI	HML1	HML1+ NKHI-
HML1	NKHI	NKHI+ HML1-
CD25	HML1	HML1+ CD25-

Table 4 Degree of T cell infiltration in the 36 cases of primitive gastrointestinal carcinomas and their metastases

	CD3+ cells inside the carcinoma				CD3+ cells around the carcinoma			
	-	±	+	++	-	±	+	++
Primitive carcinomas (36 cases)								
Gastric (17 cases)	1	12	3	1	0	1	7	9
Colic (17 cases)	1	4	7	5	0	1	2	14
Rectal (2 cases)	0	1	1	0	0	0	1	1
Total	2	17	11	6	0	2	10	24
Carcinoma metastases in the liver (5 cases)								
	0	4	1	0	0	0	1	4

Degree of the CD3+ T cell infiltration: (-): null; (±): mild; (+): moderate; (++) : heavy.

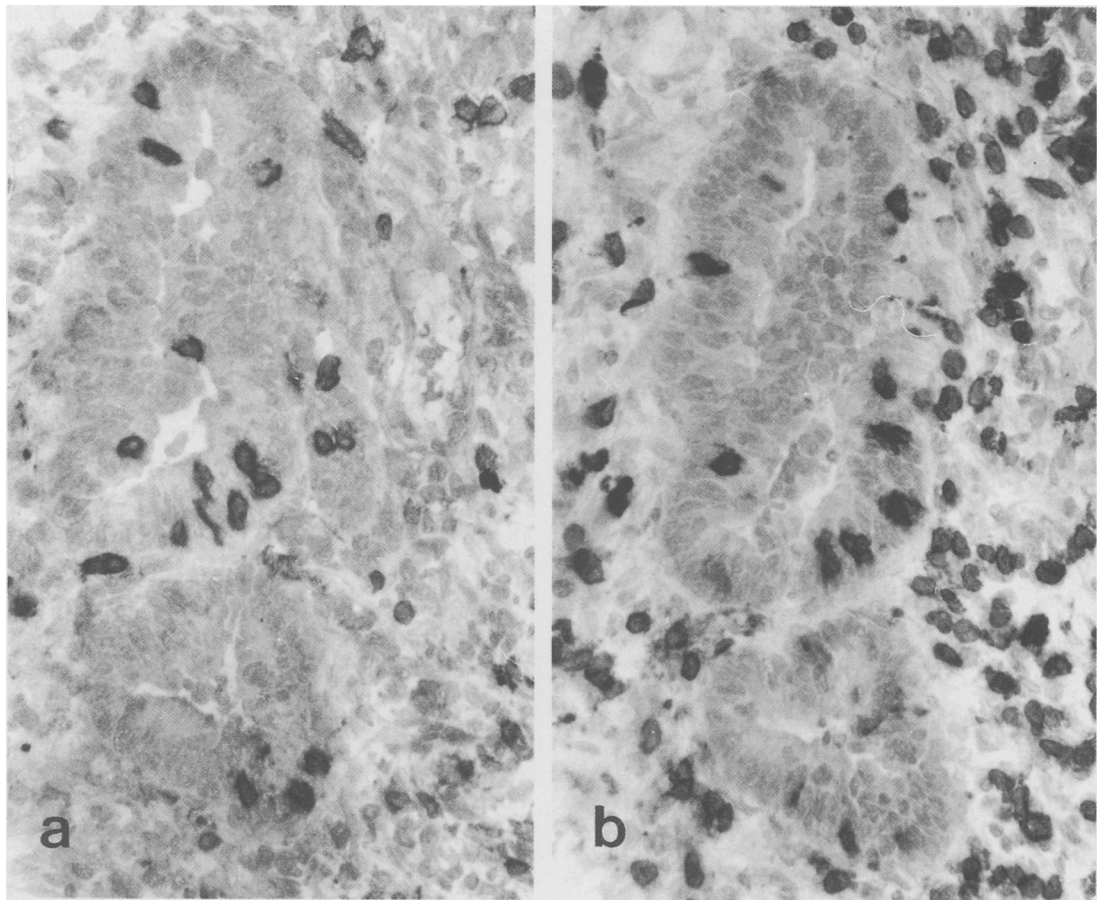


Fig. 1 Adjacent frozen tissue sections of a well differentiated colic adenocarcinoma stained by a three stage indirect immunoperoxidase technique. The intraepithelial lymphocytes present between the carcinomatous cells are labelled with HML1 (a) and anti-CD3 (b) antibodies, with a slight predominance of HML1+ cells. Conversely, only a few HML1+ lymphocytes are observed in the CD3+ lymphoid reaction around the carcinomatous lobules.

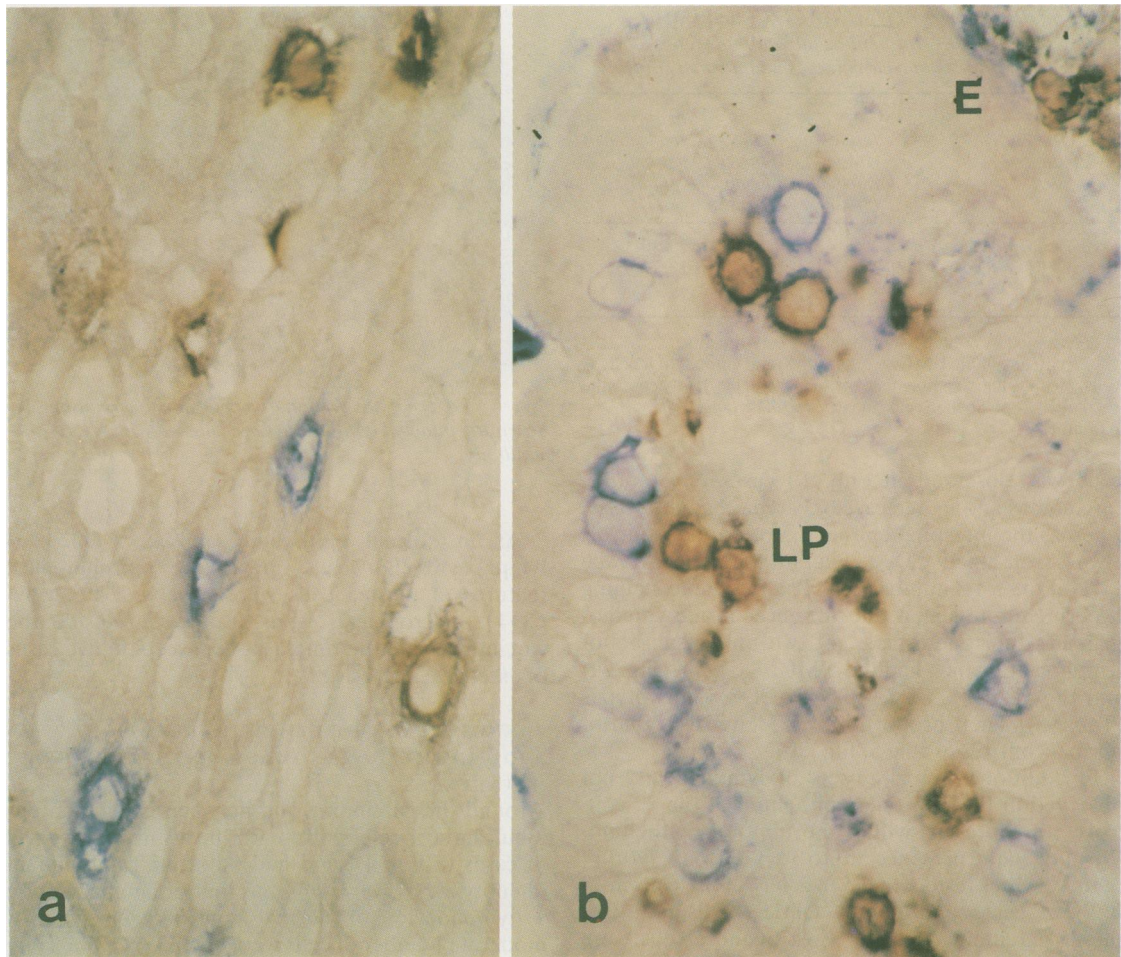


Fig. 2 Double immunostaining performed on frozen tissue sections of a colic adenocarcinoma (a) and of normal small intestine (b) with anti-CD3 (brown) and HML1 (blue). Some HML1+ CD3- cells, stained only in blue, are seen both in the tumoral epithelium and in the normal intestinal epithelium (E). No blue cells are observed in the lamina propria of normal intestine (LP). Some lymphocytes are also stained in brown, both in normal and tumoral tissues. Such cells may be labelled either by anti-CD3 only or by both anti-CD3 and HML1 antibodies.

the total number of labelled cells was estimated at a $\times 400$ magnification.

Results

A lymphoid reaction, composed mainly of T cells, was observed inside and around carcinomas. It was stronger around than inside the tumour, and had a different phenotype. As no difference was observed in the phenotype of the lymphoid reaction in the poorly or well differentiated carcinomas, or in their liver metastases, the results are described together.

PHENOTYPE OF THE LYMPHOID REACTION INSIDE THE CARCINOMAS AND THEIR LIVER METASTASES

The degree of T cell infiltration between carcinomatous cells was mild to moderate in most cases (Table 4), and was more marked in colic than in gastric carcinomas ($p < 0.01$). The majority of intratumoral T lymphocytes had the same phenotype, HML1+ CD3+, as that of normal IEL (Figs 1a, b). As in normal intestinal epithelium, most intratumoral HML1+ CD3+ lymphocytes coexpressed CD8 antigen. A small number of HML1+ CD4+

Table 5 Percentages of HML1+ CD3- and HML1+ CD3+ CD4- CD8- intraepithelial lymphocytes in primitive gastrointestinal carcinomas and normal controls*

	Inside gastric carcinomas (8 cases)	Inside colorectal carcinomas (13 cases)	In the epithelium of normal controls (22 cases)
HML1+ CD3- cells	2% (0-7)†	4% (0-11)†	2% (0-13)†
HML1+ CD3+ CD4- CD8- cells	4% (0-16)‡	5% (0-15)‡	3% (0-7)‡

*: determined by double immunostaining experiments;

†: percentage of blue HML1+ cells to the total number of labelled cells, mean value; ‡: percentage of blue CD3+ HML1+ cells to the total number of labelled cells, mean value. The range is in parentheses.

cells was observed in only 10 cases of primitive carcinomas and in one case of carcinoma metastasis, whereas the intestinal epithelium of normal controls always contained CD4+ lymphocytes (on average 17% of the total number of T IEL). Double staining experiments revealed the presence, inside carcinomas and their metastases, of two minor subsets of lymphocytes which had the HML1+ CD3- (Fig. 2a) and the HML1+ CD3+ CD4- CD8- phenotypes (Table 5). Their proportion was identical to that of normal controls (Table 5; Fig. 2b).

In addition, minor subsets of lymphocytes, not observed in the intestinal epithelium of the 22 controls, were present within the tumoral epithelium. We noticed the presence of 1 to 3% CD25+ cells in 17 of the 22 cases tested, of 0.5 to 2% NKHI+ cells in 13 of the 22 cases, and of a few CD11+ cells in nine of the 28 carcinomas tested. Most of these cells were also HML1+, as indicated by double immunostaining.

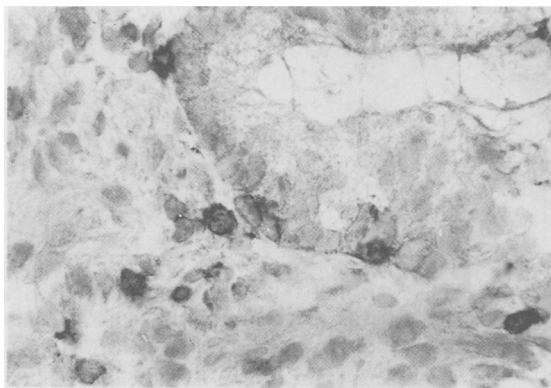


Fig. 3 Frozen tissue section of a colic adenocarcinoma. CD25 antibody, directed to the interleukin 2 receptor of T cells, stains a few lymphocytes, both inside the tumoral epithelium and in the T lymphoid reaction around.

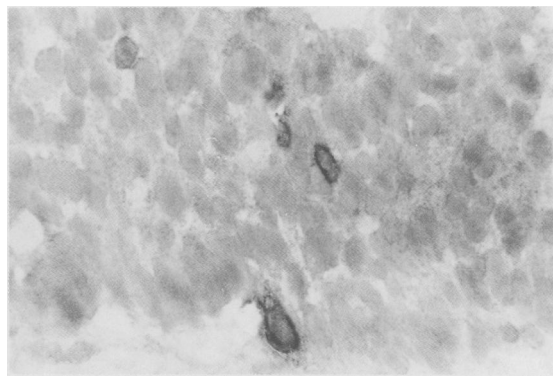


Fig. 4 Frozen tissue section of a colic adenocarcinoma. A few intraepithelial lymphocytes are labelled with NKHI antibody.

As in normal epithelium, neither CD22+ B lymphocytes nor cells having the morphological features of plasma cells were observed. LeuM5+ CD4+ macrophages were also absent inside the carcinomas and their metastases, except in five cases of extensive necrosis.

PHENOTYPE OF THE LYMPHOID REACTION AROUND THE CARCINOMAS AND THEIR LIVER METASTASES

Around the carcinoma and between carcinomatous lobules, the T cell infiltrate was heavy in the majority of cases (Table 4), and had the same predominant phenotype, CD3+ CD4+, as that of lamina propria T lymphocytes of normal controls. A small or moderate number of cells were HML1+ CD8+ (Fig. 1a). The HML1+ CD3- and HML1+ CD3+ CD4- CD8- subsets, less numerous than inside the tumoral epithelium, were similar in number to those observed in the lamina propria of normal controls.

CD25+ cells represented 1 to 5% of the CD3+ cells (Fig. 3), whereas NKHI+ cells represented less than 1% of the total lymphocytes. Most of the NKHI+ cells were also HML1+, but the majority of the CD25+ cells were CD4+ and a smaller number CD8+ or HML1+. In contrast, CD25+ or NKHI+ lymphocytes were not observed in the lamina propria of normal controls. Rather numerous CD11+ cells, most of them resembling macrophages or granulocytes and rarely lymphocytes, were observed in 13 out of the 28 primitive carcinomas tested, but not around the five carcinoma metastases.

Between carcinomatous lobules, as in normal lamina propria, there were CD22+ B lymphocytes, either disseminated or grouped in small follicles, and plasma cells, as well as numerous macrophages, strongly labelled with LeuM5 and weakly with CD4.

Table 6 HLA-DR expression on carcinomatous cells of the 36 gastrointestinal carcinomas compared with the degree of T cell infiltration between the carcinomatous cells

HLA-DR expression on carcinomatous cells	CD3+ lymphocytes				Number of cases
	-	±	+	++	
+	1	8	6	5	20
-	1	9	5	1	16

Degree of the CD3+ T cell infiltration: (-): null; (±): mild; (+) moderate; (++) heavy.

HLA-DR EXPRESSION ON GASTROINTESTINAL TUMORAL EPITHELIAL CELLS

In 20 of 36 primitive carcinomas, carcinomatous cells were stained with anti-HLA-DR antibody. Although HLA-DR antigens were expressed in most cases of primitive carcinomas with a heavy T cell infiltration, we did not observe a statistically significant correlation between the degree of intratumoral T cell infiltration and the expression of HLA-DR antigens on epithelial cells (Table 6).

Discussion

This study shows that the distribution of T lymphocytes in gastrointestinal carcinomas and their metastases mimic the distribution of T lymphocytes in normal intestine. In most cases, there was a lymphoid reaction in which an intratumoral and a peritumoral components could be distinguished. The composition of the peritumoral reaction resembled that of normal lamina propria, with a predominance of CD3+ CD4+ T cells. Except for one case, the proportion of CD8+ and of HML1+ cells did not exceed one third of the CD3+ cells. This pericarcinomatous reaction thus resembled the peritumoral reaction that we had previously seen around gastrointestinal lymphomas.⁸

In contrast, lymphocytes located between the carcinomatous cells show phenotypical features similar to those of IEL in normal intestine; in particular, they express the antigen defined by the antibody HML1. The antibody HML1, raised against normal intestinal IEL, reveals over 95% of normal intestinal IEL, and 40% of lamina propria T lymphocytes, preferentially those that expressed the same CD3+ CD8+ phenotype as that of IEL.⁵ In contrast, it reveals rare cells in the blood and lymphoid organs.⁵ In addition, HML1 stains the majority of IEL in the histologically normal bronchial and mammary epithelium,⁵ and some lymphocytes that infiltrate the epidermis in skin lesions such as parapsoriasis or graft *versus* host disease.¹⁰ Our present results indicate that HML1+ lymphocytes

are also preferentially associated with tumoral intestinal epithelium. Preliminary studies indicate that HML1+ cells are also observed inside carcinomas of non-intestinal origin (bronchus, breast), whereas they are absent inside gastrointestinal B lymphomas.¹⁰ All these results indicate that HML1 defines a population of lymphocytes preferentially associated with the epitheliums, either normal or tumoral. The significance of HML1 expression is not known. It may be induced by the epithelial microenvironment. Alternatively, it may also enable a subset of lymphocytes to interact with epithelial cells.

The various subsets of IEL found in normal intestine were also present within tumoral epithelium. The majority of intratumoral lymphocytes were CD3+ T cells, among which the CD8+ subset remained predominant. The minor subset of CD3+ lymphocytes which express neither CD4 nor CD8 antigens, and which was already observed in normal and coeliac intestinal biopsies by Jenkins *et al.*,¹¹ was also found in tumoral epithelium in proportion identical to that of normal controls. This subset may be similar to the small subset of CD3+ CD4- CD8- peripheral blood lymphocytes that expressed the γ chain but not the α and β chains of the T cell receptor.^{12,13} The fact that a monoclonal antibody (a gift from Dr T Hercend), directed to the product of the V γ 9 gene reveals a few IEL in normal intestine sustains this hypothesis (unpublished observation). Finally, tumoral epithelium also contains the same minor subset of HML1+ CD3- CD4- CD8- cells that we have previously described in IEL isolated from normal small intestine. This subset, which may represent the human equivalent of the thymus-independent granulated subset of rodent IEL,^{14,15} was not significantly modified in carcinomas.

Besides these subsets present either in tumoral or normal epithelium, however, this study shows the appearance of three other minor subsets, present only in tumoral epithelium. The presence of a small number of CD25+ lymphocytes may be indicative of the local activation of some T lymphocytes in close contact with carcinomatous cells. In addition, we noticed a small percentage of lymphocytes expressing the phenotype of natural killer cells (NKHI+) and of suppressor T cells (CD11+). The appearance of these cells within tumoral epithelium may suggest that they participate in antitumoral defence.

The functions of IEL are not yet well understood. It has been suggested that they modulate some functions of epithelial cells. The best shown interaction between IEL and epithelial cells is the role of activated IEL in the induction of class II molecules of the major histocompatibility complex on epithelial

cells through the secretion of a soluble factor, probably gamma interferon.⁶⁷ In our study, and contrary to Allen and Hogg's observations,¹⁶ there was no statistically significant correlation between the degree of the intratumoral lymphocytic infiltration and the expression of HLA-DR antigens by the carcinomatous cells. HLA-DR antigens were observed in carcinomatous cells in the absence of IEL. Although it cannot be excluded that tumoral epithelial cells can spontaneously express HLA-DR antigens, it seems more likely that this was caused by the release of lymphokines by the nearby lymphocytes surrounding carcinomatous cells, some of them being CD25+ activated lymphocytes. Conversely, we noticed the absence of HLA-DR antigens on carcinomatous cells in spite of an intratumoral lymphoid infiltrate. It is possible that some carcinomatous cells may lose their capability of responding to lymphokines when the tumour develops, which is supported by the fact that the carcinomatous cells in the liver metastases were HLA-DR negative or very faintly positive in only one case, whereas the primitive tumour was strongly HLA-DR+.

A Jarry is supported by a scholarship of the Association pour la Recherche sur le Cancer, Villejuif, France. The authors are very grateful to Dr J Barge and Dr G Molas for providing the biopsies and surgical specimens.

References

- 1 Ferguson A. Intraepithelial lymphocytes of the small intestine. *Gut* 1987; **18**: 921–37.
- 2 Cerf-Bensussan N, Schneeberger EE, Bhan AK. Immunohistologic and immunoelectron microscopic characterization of the mucosal lymphocytes of human small intestine by the use of monoclonal antibodies. *J Immunol* 1983; **130**: 2615–22.
- 3 Cerf-Bensussan N, Guy-Grand D, Griscelli C. Intraepithelial lymphocytes of human gut: isolation, characterization and study of natural killer activity. *Gut* 1985; **26**: 81–8.
- 4 Dobbins WO. Human intestinal intraepithelial lymphocytes. *Gut* 1986; **27**: 972–85.
- 5 Cerf-Bensussan N, Jarry A, Brousse N, Lisowska-Groszpiere B, Guy-Grand D, Griscelli C. A monoclonal antibody (HML-1) defining a novel membrane molecule present on human intestinal lymphocytes. *Eur J Immunol* 1987; **17**: 1279–85.
- 6 Cerf-Bensussan N, Quaroni A, Kurnick JT, Bhan AK. Intraepithelial lymphocytes modulate Ia expression by intestinal cells. *J Immunol* 1984; **132**: 2244–52.
- 7 Guy-Grand D, Vassalli P. Gut injury in graft-versus-host reaction. Study of its occurrence and mechanisms. *J Clin Invest* 1986; **77**: 1584–95.
- 8 Jarry A, Brousse N, Souque A, Barge J, Molas G, Potet F. Lymphoid stromal reaction in gastrointestinal lymphomas: immunohistochemical study of 14 cases. *J Clin Pathol* 1987; **40**: 760–5.
- 9 Mason DY, Sammons RE. Alkaline phosphatase and peroxidase for double immunoenzymatic labelling of cellular constituents. *J Clin Pathol* 1978; **31**: 454–60.
- 10 Cerf-Bensussan N, Jarry A, Gneragbe T, *et al.* Monoclonal antibodies specific for intestinal lymphocytes. *Monogr Allergy* 1988; **24**: 167–72.
- 11 Jenkins D, Goodhall A, Scott BB. T lymphocyte populations in normal and coeliac small intestinal mucosa defined by monoclonal antibodies. *Gut* 1986; **27**: 1330–7.
- 12 Lanier LL, Ruitenberg JJ, Philipps LM. Human CD3+ T lymphocytes that express neither CD4 nor CD8 antigens. *J Exp Med* 1986; **164**: 339–44.
- 13 Brenner MB, McLean J, Scheft H, *et al.* Two forms of the T cell receptor γ protein found on peripheral blood cytotoxic T lymphocytes. *Nature* 1987; **325**: 689–94.
- 14 Guy-Grand D, Griscelli C, Vassalli P. The mouse gut T lymphocyte, a novel type of T cell. Nature, origin and traffic in mice in normal and graft-versus-host conditions. *J Exp Med* 1978; **148**: 1661–77.
- 15 Klein JR. Ontogeny of the Thy1–Lyt2+ murine intestinal intraepithelial lymphocytes. Characterization of a unique population of thymus-independent cytotoxic effector cells in the intestinal mucosa. *J Exp Med* 1986; **164**: 309–14.
- 16 Allen C, Hogg N. Association of colorectal tumor epithelium expressing HLA-D/DR with CD8 positive T cells and mononuclear phagocytes. *Cancer Res* 1987; **47**: 2919–23.