

CASE REPORTS

Gastric polyposis caused by multifocal histiocytosis X

R Wada, S Yagihashi, R Konta, T Ueda, T Izumiyama

Abstract

A rare case of gastric polyposis caused by infiltration of Langerhans' cells is reported. A 53 year old Japanese woman complaining of vague abdominal discomfort, was found at endoscopy to have numerous polyps all over the gastric wall. An endoscopic biopsy specimen showed characteristic infiltration of Langerhans' cells in the lamina propria of the mucosa. Functional abnormalities such as impaired gastric acid secretion or malabsorption were not associated with this lesion and the patient was treated conservatively. During follow up over two years, she had a cutaneous eruption with infiltration of histiocytes and osteolytic lesions in the skull. However, no progressive changes occurred in the stomach. This probably benign self-limiting lesion of gastric histiocytosis X may be one of the manifestations of multifocal histiocytosis X, but its aetiology and appropriate treatment have not yet been determined.

Case history

A well-nourished 53 year old Japanese woman complaining of abdominal discomfort attended Hokushu Central Hospital on 3 March 1989. She had been treated with antihypertensive drugs for the previous three years but had no other remarkable personal or family medical history. Physical examination showed no abnormality.

Laboratory data were not relevant, although there was a mild increase in serum cholesterol concentrations. Serological tests for viral, bacterial, or chronic granulomatous diseases were all negative.

Barium x ray series of the upper gastrointestinal tract showed numerous raised lesions all over the gastric wall. Endoscopic examination confirmed the presence of numerous polyps, most of which were hemispherical and approximately 5-7 mm in diameter (Fig 1). Occasional polyps were fused forming larger growths. The surface of these polyps was smooth and slightly yellow and there were no erosions or ulcers. Extension and movement of the gastric wall were good. There seemed to be no abnormalities in the oesophagus or duodenum.

Pathological examination of biopsy specimens taken from several sites on the gastric wall showed conspicuous infiltration of histiocytes with indented nuclei in the lamina propria of the mucosa (Fig 2). Multinucleated giant cells of Langhans' and Touton's types were occasionally observed. Small numbers of eosinophils, neutrophils, and lymphocytes were present. Immunohistochemical examination showed positive reactions for S-100, α_1 antitrypsin and a negative reaction for lysozyme in the infiltrating histiocytes. Ultrastructurally they contained membranous structures similar to Birbeck granules in their cytoplasm (Fig 3).

A diagnosis of gastric histiocytosis X was made and the patient was followed up with conservative management. Two years after the initial diagnosis, brown eczematous eruptions appeared in both axillary and suprapubic regions. Biopsy specimens showed an infiltrate of foamy histiocytes in the upper dermis. Skull x rays showed osteolytic lesions in the parietal and frontal regions (Fig 4). However, no symptoms such as bone pain or complaints suggestive of intracranial lesions were evident. The patient has been treated conservatively and followed up. Repeat examinations showed no evidence of exacerbation.

Discussion

Histiocytosis X is a rare disease characterised by proliferation of Langerhans' cells identical to histiocytes located in normal epidermis or lymph nodes which participate in antigen presentation

Departments of
Pathology and
Dermatology, Hirosaki
University School of
Medicine, Hirosaki,
Japan
R Wada
S Yagihashi
R Konta

Department of Surgery,
Hokushu Central
Hospital, Takanosu,
Japan
T Ueda
T Izumiyama

Correspondence to:
Dr R Wada, Department of
Pathology, Hirosaki
University School of
Medicine, Zaifucho 5,
Hirosaki, 036 Japan

Accepted for publication
21 October 1991

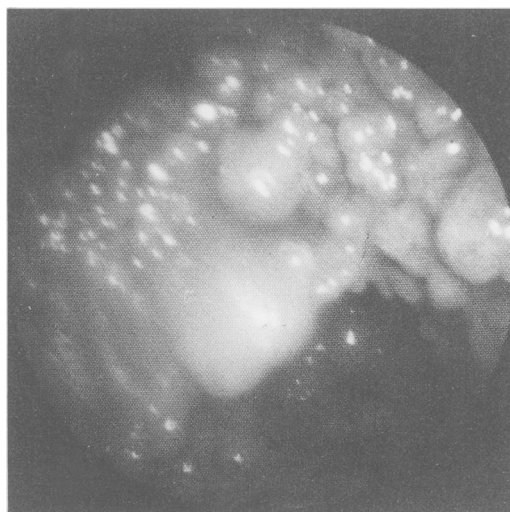


Figure 1: Gastric endoscopy. Numerous polyps cover the entire wall of the stomach.

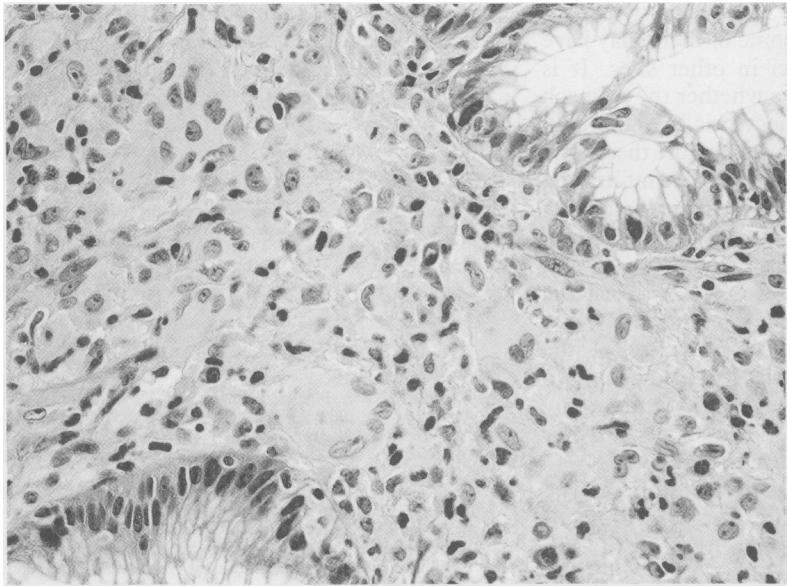


Figure 2: Gastric biopsy specimen. Many histiocytoid cells with indented nuclei and abundant eosinophilic cytoplasm infiltrate in the lamina propria of the mucosa. Large giant cells are frequently encountered (original magnification $\times 200$).

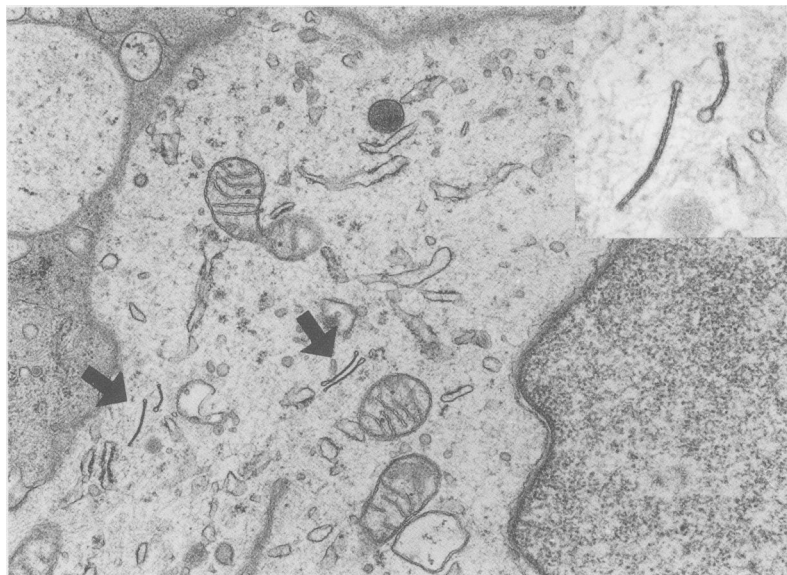


Figure 3: Electron microscopy of the histiocytes (original magnification $\times 15\,000$). Cytoplasmic Birbeck granules in Langerhans' cell (arrowed). Enlarged figure of Birbeck granules (inset) (original magnification $\times 50\,000$).

for immunological purposes.¹⁻³ Histiocytosis X is a continuum of diseases with variable clinical and pathological expression, ranging from unifocal eosinophilic granuloma to multifocal eosinophilic granuloma and diffuse histiocytosis X of Letterer-Siwe type.⁴ The prognosis seems to depend on the age of patient and on the extent

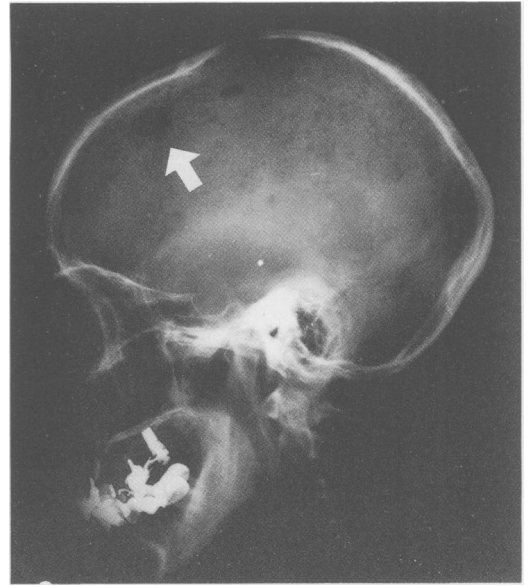


Figure 4: Osteolytic skull lesions (arrowed).

and rate of progression of the disease.¹ In adults, the disease tends to affect one site and follow a favourable course.¹⁵

In cases of histiocytosis X, the lung and liver are the most commonly affected internal organs.⁵ A rare case in which intractable diarrhoea was caused by histiocytic infiltration in the intestinal wall has been reported.⁶ Four cases of gastric histiocytosis X have been recorded in recent published reports all of which followed a benign course with lesions restricted to the stomach (Table).⁷⁻¹⁰ Three of these were treated by gastrectomy since there was a suspicion of malignancy.⁷⁻⁹ A single case reported by Iwafuchi *et al* was diagnosed by biopsy.¹⁰ The macroscopic appearance in this case was that of gastric polyposis which disappeared five and a half years after the initial diagnosis without any treatment. The present case also showed numerous polyps in the stomach and histological examination revealed characteristic infiltration by Langerhans' cells. These appearances were similar to those in the cases reported above. At the time of initial diagnosis, we believed that the lesion was restricted to the stomach and that the disease would follow a self-limiting course. However, the subsequent appearance of cutaneous eruptions due to infiltration by histiocytes and the presence of osteolytic skull lesions indicated that this case could be classified as multifocal histiocytosis X.

There is little reference to systemic involve-

Reported cases of gastric histiocytosis X

Authors	Patient (age/sex)	Location	Macroscopic appearance	Mitotic figures	Nature of histiocytes	Treatment	Prognosis
Vazquez & Ayestaran ⁷	59/F	Lesser curvature	Ulcerated mass	+	Not described	Gastrectomy	Not described
Zeman & Havlik ⁸	56/M	Not described	Ulcerated mass	-	Neoplastic	Gastrectomy	Alive 2 years after operation
Nihei <i>et al</i> ⁹	47/F	Body and fornix	Flat lesion	-	Benign	Gastrectomy	Alive 1 2/3 years after operation
Iwafuchi <i>et al</i> ¹⁰	49/F	Whole stomach	Polyposis	-	Benign	Conservative treatment and follow up	Alive 6 1/2 years after diagnosis
Present case	53/F	Whole stomach	Polyposis	-	Benign	Conservative treatment and follow up	Alive; skin lesion and osteolytic skull lesions

ment in the reported cases of gastric histiocytosis X and it is possible that some of them may have been associated with foci in other sites. It is unclear in the present case whether the stomach is the primary site of histiocytosis X, since skull lesions could have been present before the gastric lesion. One report suggested that the infiltrating histiocytes may be neoplastic. If the histiocytes in the stomach were neoplastic, multifocal involvement might indicate progression and aggressive chemotherapy would have been the choice of treatment. In the present case, however, this was unlikely because most of the gastric polyps did not enlarge during the two and a half year observation period without any treatment. There was no cellular atypism nor mitotic activity in the infiltrating histiocytes.

Previously reported patients with gastric histiocytosis X presented clinically with non-specific abdominal symptoms. Abnormalities in gastric acid secretion or the malabsorption syndrome were not described. Absence of organ dysfunction, lack of progression of the disease, and the age of the patient are factors that indicate that gastric histiocytosis X will follow a benign self limiting course. Cases of this kind may be

mistaken for malignant disease, but accurate pathology will prevent unnecessary gastrectomy. Systemic examination and careful follow up to identify involvement of other organs is required.

- 1 Favara BE, McCarthy RC, Mierau GW. Histiocytosis X. *Hum Pathol* 1983; 14: 663-76.
- 2 Rowden G, Connelly EM, Winkelmann RK. Cutaneous histiocytosis X. The presence of S-100 protein and its use in diagnosis. *Arch Dermatol* 1983; 119: 553-9.
- 3 Terashima K, Matsuda M, Imai Y. Histiocytes and proliferative disorders, rare histiocytic proliferation. *Pathol Clin Med* 1984; 2: 64-72.
- 4 Groopman JE, Golde DW. The histiocytic disorders: A pathophysiologic analysis. *Ann Intern Med* 1981; 94: 95-107.
- 5 Berry DH, Becton DL. Natural history of histiocytosis X. In: Osband ME, Pochedly C, eds. *Hematology/Oncology Clinics of North America. Histiocytosis X*. Philadelphia: WB Saunders Co, 1987: 23-34.
- 6 Deprettere A, Aelvoet G, Acker KJV, Dockx P. Intractable diarrhea in histiocytosis X. *Helv Paediat Acta* 1983; 38: 291-4.
- 7 Vazquez JJ, Ayestran JR. Eosinophilic granuloma of the stomach similar to that of bone, light and electron microscopic study. *Virchows Arch [A]* 1975; 366: 107-11.
- 8 Zeman V, Havlik J. Histiocytosis X: Izolovany extraosalni eozinofilni retikulom zaludku. *Cesk Gastroenterol Vyz* 1980; 34: 255-8.
- 9 Nihei K, Terashima K, Aoyama K, Imai Y, Sato H. Benign histiocytosis X of the stomach, previously undescribed lesion. *Acta Pathol Jpn* 1983; 33: 577-88.
- 10 Iwafuchi M, Watanabe H, Shiratsuka M. Primary benign histiocytosis X of the stomach, a report of a case showing spontaneous remission after 5½ years. *Am J Surg Pathol* 1990; 14: 489-96.