

## LETTERS TO THE EDITOR

### The knee-elbow position relieves distension

EDITOR,—In their article in *Gut* 1993; 34: 1726–7 Panos *et al* described colon decompression after assuming a knee-chest position and state they are ‘not aware of any previous reports of its use ... in toxic megacolon’ and suggest that a prospective assessment of outcome is appropriate.

Unfortunately, for the authors, little is new in clinical medicine and a similar technique has already been well described in our paper.<sup>1</sup> We had also cited a previous paper by Kramer and Wittenberg<sup>2</sup> describing redistribution of gas in toxic megacolon by changing the anatomical position. Kramer and Wittenberg did not clinically apply this technique to their patients.

Panos *et al* also requested longterm follow up, which was presented in our paper in 19 patients in which 13 (68%) treated with this technique did well and did not require surgery (mean follow up 6.5 years). Since this report we have treated at least 15 more patients with this technique and have never had to perform emergency surgery for persistent colonic dilatation, although some patients require surgery for persistent activity after decompression.

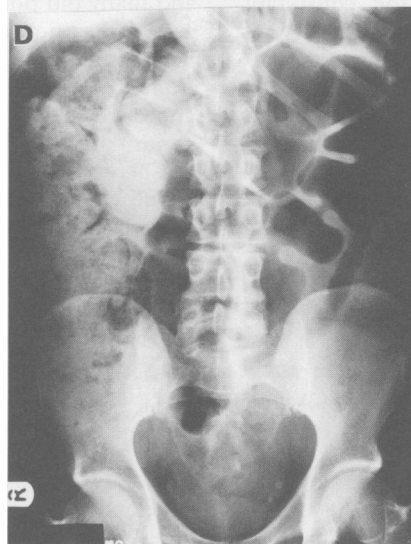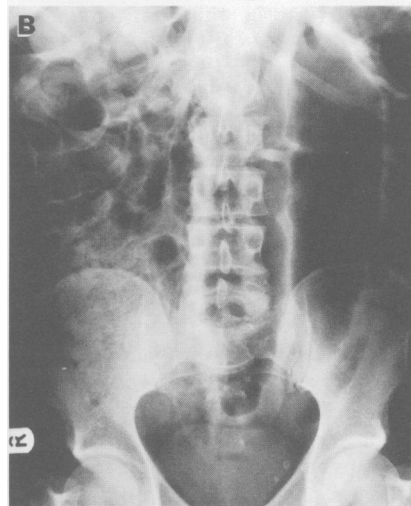
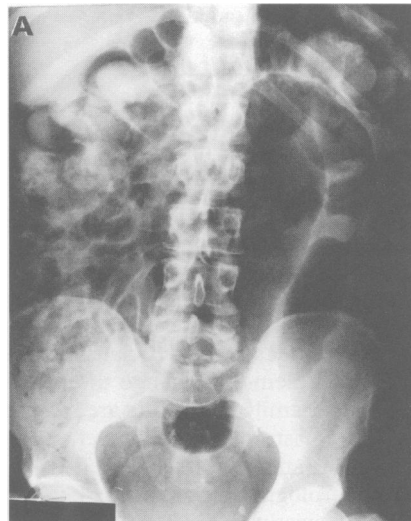
Fortunately for inflammatory bowel disease patients, this article hopefully will reawaken interest in the comprehensive medical treatment programme required to treat fulminant colitis and toxic megacolon. Many patients will respond to intensive medical treatment and thus avoid emergency surgery. This comprehensive programme including the rolling technique is detailed in a more recent publication.<sup>3</sup>

D H PRESENT  
Mount Sinai Medical Center,  
12 East 86th Street,  
New York, NY 10028, USA

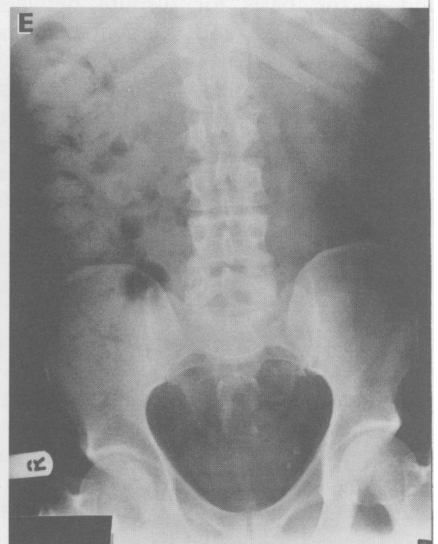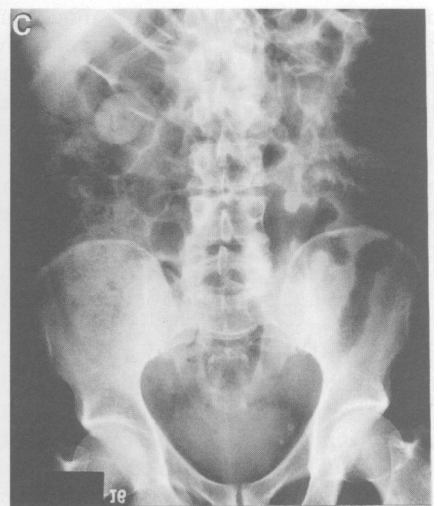- 1 Present DH, Wolfson D, Gelernt IM, Rubin PH, Bauer J, Chapman ML. Medical decompression of toxic megacolon by rolling. A new technique of decompression with favourable long-term follow-up. *J Clin Gastroenterol* 1988; 10: 485–90.
- 2 Kramer P, Wittenberg J. Colonic gas distribution in toxic megacolon. *Gastroenterology* 1981; 80: 433–7.
- 3 Present DH. Toxic megacolon. *Med Clin North Am* 1993; 77: 1129–48.

EDITOR,—We have recently used the intriguing knee-elbow position described by Dr Panos (*Gut* 1993; 34: 1726–7) in a 45 year old man with acute colitis and progressive dilatation of the sigmoid colon.

He presented with a seven week history of worsening diarrhoea. Over the preceding week he had passed 10 stools a day containing blood and pus. On examination, he was afebrile, with no tachycardia and his abdomen was soft with normal bowel sounds. Sigmoidoscopy showed a granular friable mucosa with spontaneous haemorrhage ahead of the instrument. Histological tests were consistent with active ulcerative colitis. Haemoglobin was 13.1 g/dl, platelets



Abdominal x rays of the patient showing response to the adoption of the knee-elbow position



$509 \times 10^9/l$ , C reactive protein 207 mg/l,  $\alpha$ -1 acid glycoprotein 2275 (normal range <1150) and albumin 36 g/l. No pathogens were identified on stool culture. Plain abdominal x ray showed a 8.5 cm dilated sigmoid loop (Fig (A)). He was treated with bed rest and intravenous hydrocortisone 100 mg 6 hourly with metronidazole 500 mg 8 hourly.

Two days after admission he developed abdominal discomfort and distension. Abdominal x ray confirmed persisting sigmoid dilatation (Fig (B)). He was

instructed to adopt the knee-elbow position for five minutes every half hour. In this position he passed large quantities of flatus often triggered by coughing. Four hours later he felt more comfortable with a soft abdomen. A repeat x ray showed decompression of the sigmoid loop (Fig (C)).

Six days after admission his abdomen again became distended and again responded to adoption of the knee-elbow position (Fig (D) and (E)). After nine days his bowel had returned to normal and he was discharged with a reducing course of oral prednisolone.

Surgery was considered on days two and six. The knee-elbow position reversed the radiographic appearances, however, and changed the treatment of our patient's colitis. The use of this simple and safe manoeuvre probably spared our patient from surgical intervention.

J FLETCHER  
A J LOBO  
R F HARVEY  
Frenchay Hospital,  
Bristol BS16 1LE

EDITOR.—Panos *et al* (*Gut* 1993; 34: 1726–7) describe the knee-elbow position for the relief of bowel distension in patients with toxic megacolon. They suggest that their use of this therapeutic manoeuvre is new.

In 1988 Present *et al*<sup>1</sup> published their experience with 'rolling' 19 patients with toxic megacolon into the prone position every two to three hours for 10 to 15 minutes. They concluded this was a helpful addition to the standard treatment for this serious condition.

Both groups are describing the same phenomenon – the prone position redistributes colonic gas and fluid into the lower bowel leading to easier evacuation. We have been using this technique for several years at the Stanford Medical Center.

R R BABB  
Palo Alto Medical Clinic,  
300 Homer Ave,  
Palo Alto,  
CA 94301, USA

1 Present DH, Wolfson D, Gelernt IM, Rubin PH, Bauer J, Chapman ML. Medical decompression of toxic megacolon by 'rolling'. A new technique of decompression with favourable long-term follow-up. *J Clin Gastroenterol* 1988; 10: 485–90.

### Reply

We welcome the correspondence on our case report, which gives us the opportunity of further discussion of the use of postural manoeuvres for bowel decompression. 'Rolling', as described by Dr Present *et al*, entails turning the patient to the prone position, on a flat bed.<sup>1</sup> This position is clearly different from the knee-elbow position we have reported in which the patient is positioned head down with hips, knees, and elbows flexed.<sup>2</sup>

A crucial point needs to be made with respect to the 'rolling' regimen, as described by Present *et al* in their series of 19 patients: in addition to turning the patient prone, a long enteral tube was passed for aspiration of gas and enteral fluid.<sup>1</sup> Consequently it is difficult to discern what the individual contribution of the intubation-aspiration versus the postural manoeuvre was, in decompressing the bowel. We also note that in five of their 19 cases, a rectal catheter was required to facilitate evacuation of gas that had not been forthcoming.<sup>1</sup> The uppermost position of the rectum and anus in the knee-elbow position permits easy passage of flatus and could obviate the need for rectal catheterisation.

The early and longterm follow up results from Dr Present's uncontrolled series are impressive. Nevertheless, the effect of bowel decompression by postural manoeuvres on the outcome of toxic megacolon should be confirmed by prospective, randomised, controlled trials.

We remain unaware of any previous reports

of the use of the knee-elbow position to decompress the bowel in toxic megacolon.

M Z PANOS  
M J WOOD  
P ASQUITH  
Department of Medicine,  
University of Birmingham Medical School and East  
Birmingham Hospital,  
Birmingham

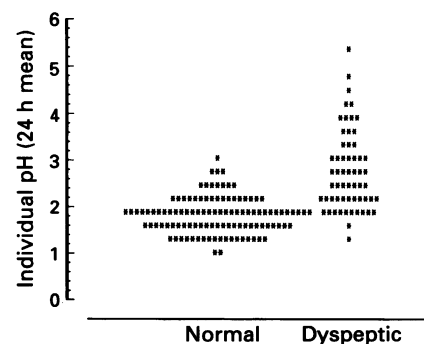
1 Present DH, Wolfson D, Gelernt IM, Rubin PH, Bauer J, Chapman ML. Medical decompression of toxic megacolon by rolling. A new technique of decompression with favourable long-term follow-up. *J Clin Gastroenterol* 1988; 10: 485–90.

2 Hamilton Bailey. *Physical signs in clinical surgery*. 11th Ed. Bristol: J Wright, 1949: 229.

### Acid and gastric metaplasia in the duodenum

EDITOR.—We read with great interest the paper by Noach *et al* (*Gut* 1993; 34: 1510–4) on the relation between duodenal gastric metaplasia and *Helicobacter pylori* infection. Two findings deserve particular attention in this study. Firstly, the presence and extent of gastric metaplasia in the duodenum was not significantly associated with *H pylori* infection, because it was found in 78% of *H pylori* positive and in 85% of *H pylori* negative patients with dyspeptic complaints. Secondly, there was no reduction in the extent and prevalence of gastric metaplasia after 12 months of eradication of *H pylori*.

The first finding obviously excludes the responsibility of *H pylori* in the formation of gastric metaplasia in the duodenum, but raises serious questions on the role of acid in this process.<sup>1</sup> In fact, a study has already shown that patients with functional dyspepsia have a basal acid output that is comparable with that of normal subjects.<sup>2</sup> Using ambulatory pHmetry<sup>3</sup> we have even found that the circadian gastric acidity in *H pylori* negative dyspeptic patients is significantly lower (24 hour mean (SEM) pH 2.8 (0.8) v 1.8 (0.4),  $p < 0.001$ ) than normal (Figure). In addition, although *H pylori* infection results in an increase in gastrin release, this hypergastrinaemia does not induce an increase in acid secretion. There is no difference, indeed, in basal and maximal acid output<sup>4</sup> and in 24 hour intragastric acidity<sup>5</sup> between *H pylori* positive and negative patients. Finally, it is well known that only some patients with duodenal ulcer disease secrete an amount of gastric acid higher than normal<sup>6</sup> and only a subgroup of them shows a rapid gastric emptying,<sup>7</sup> which could result in an increased



Distribution of individual pH (24 h mean) in normal subjects and patients with functional dyspepsia. Recordings made for the 24 hour period from 1700 to 1659.

acid load to the duodenum with subsequent mucosal injury.

On the basis of these findings, the common belief that gastric metaplasia in the duodenum is induced by hypersecretion of gastric acid<sup>8,9</sup> is questionable.

The finding of the lack of regression of gastric metaplasia in the bulb after 12 months of eradication of *H pylori* has been explained by the authors by the fact that gastric acid secretion is not changed by treatment of the infection<sup>10</sup> and therefore, the persistent high production of acid helps to maintain the histological duodenal alteration. As acid hypersecretion is not the rule in duodenal ulcer, however, and is not present in functional dyspepsia, it is again difficult to claim this physiological abnormality as the main cause of maintenance of gastric metaplasia in the long term.

Thus, it seems that the presence of *H pylori*, by itself, is the main factor in the development of duodenal ulcer, although the mechanisms of this action are far from clear. As suggested by the authors, the mucosal production of cytokines and specific toxins released by the bacterium might be possible ulcerogenetic factors, independent of gastric metaplasia. The persistence of this epithelial change in patients where *H pylori* has been eradicated who show a dramatic reduction in ulcer relapse, seems to diminish further its pathogenetic relevance.

V SAVARINO  
G MELA  
G CELLE  
Department of Internal Medicine,  
University of Genova, Italy  
S VIGNERI  
Institute of Internal Medicine and Geriatrics,  
University of Palermo, Italy

- Wyatt JL, Rathbone BJ, Dixon MF, Heatley RV, Axon ATR. Campylobacter pylori and development of duodenal ulcer [Letter]. *Lancet* 1988; i: 118–9.
- Collen MJ. Gastric analysis (basal acid output) in nonulcer dyspepsia. *Dig Dis Sci* 1990; 35: 540–1.
- Savarino V, Mela GS, Zentilin P, Magnolia MR, Scalabrini P, Valle F, *et al*. Gastric aspiration versus antimony and glass electrodes. A simultaneous comparative in vivo study. *Scand J Gastroenterol* 1989; 24: 434–9.
- Brady III CE, Hadfield TL, Hyatt JR, Utts SJ. Acid secretion and serum gastrin levels in individuals with Campylobacter pylori. *Gastroenterology* 1988; 94: 923–7.
- Wagner S, Gladziwa U, Haruma K, Varrentrapp M, Gebel M. Effect of Helicobacter pylori infection on 24 hour intragastric acidity in patients with gastritis and duodenal ulcer. *Gut* 1992; 33: 1024–7.
- Baron JH. The relationship between basal and maximum acid output in normal subjects and patients with duodenal ulcer. *Clin Sci* 1963; 24: 357–70.
- Lam SK. Pathogenesis and pathophysiology of duodenal ulcer. *Clin Gastroenterol* 1984; 13: 447–72.
- Wyatt JL, Rathbone BJ, Dixon MF, Heatley RV. Campylobacter pyloridis and acid-induced gastric metaplasia in the pathogenesis of duodenitis. *J Clin Pathol* 1987; 40: 841–8.
- Carrick J, Lee A, Hazell S, Ralston M, Daskalopoulos G. Campylobacter pylori, duodenal ulcer, and gastric metaplasia: possible role of functional heterotopic tissue in ulcerogenesis. *Gut* 1989; 30: 790–7.
- Montbriand JR, Appelman HD, Cotner EK, Nostrant TT, Elta GH. Treatment of Campylobacter pylori does not alter gastric acid secretion. *Am J Gastroenterol* 1989; 84: 1513–6.

### Reply

EDITOR.—We thank Savarino *et al* for their interest in our study on *Helicobacter pylori* and gastric metaplasia in the duodenum.