

CASE REPORTS

Monozygotic twins with Crohn's disease and ulcerative colitis: a unique case report

N P Breslin, A Todd, C Kilgallen, C O'Morain

Abstract

Background—A large number of monozygotic and dizygotic twin pairs with inflammatory bowel disease have been reported. To date no twin pair has developed phenotypically discordant inflammatory bowel disease. This case report is the first documented occurrence of discordant inflammatory bowel disease occurring in monozygotic twins.

Case report—Twenty two year old identical male twins presented within three months of each other with inflammatory bowel disease that proved to be discordant in overall disease type, disease distribution, clinical course, and histopathological findings. Twin 1 developed a severe pancolitis necessitating total colectomy while twin 2 developed a predominantly distal patchy colitis with frequent granulomas, controlled by aminosalicylates. Twin 1 was antineutrophil cytoplasmic antibody (ANCA) negative at the time of testing while twin 2 (Crohn's disease) was ANCA positive. Significantly, the twins possessed the HLA type DR3-DR52-DQ2 previously associated with extensive colitis.

Conclusion—This case report confirms the important role played by genetic factors in the development of inflammatory bowel disease. It also highlights the crucial role of undetermined environmental agents in dictating disease expression and phenotype.

(Gut 1997; 41: 557-560)

Keywords: monozygotic twins; ulcerative colitis; Crohn's disease; inflammatory bowel disease

The aetiology of chronic idiopathic inflammatory bowel disease is multifactorial and appears to combine both genetic and environmental factors. Studies consistently show an increased prevalence of inflammatory bowel disease among first degree relatives of an affected individual.¹⁻³ The affected relative is more likely to develop a phenotype of inflammatory bowel disease that is similar to the index case both in disease type and distribution.⁴ This familial association is strongest in twins and in particular in monozygotic twins. There are

numerous case reports where one or both twins are affected by either ulcerative colitis or Crohn's disease.⁵⁻⁸ In addition, two large twin studies have been reported in the literature.^{9,10} These include both monozygotic and same sex dizygotic twins with inflammatory bowel disease; if both are affected there is concordance in the disease type. This case report is the first documented occurrence of mixed inflammatory bowel disease in a pair of monozygotic twins.

Case reports

Twin 1, a twenty two year old white male, presented to the gastroenterology outpatient department with a three week episode of bloody mucous diarrhoea occurring seven to eight times per day and associated with crampy lower abdominal pain. He was generally unwell and anorexic. He gave a two year history of episodic bloody diarrhoea, occasional dry eyes, and painful large joints. These symptoms had not been previously investigated.

Physical examination was unremarkable and laboratory investigations revealed a haemoglobin of 12.8 g/dl, an erythrocyte sedimentation rate of 30 mm/h, and normal liver profile. Stool culture and microscopy for ova and parasites were negative. Colonoscopy was performed which revealed a total colitis with inflamed granular mucosa, continuous ulceration, and excess mucus. Serial colonic biopsy specimens revealed florid architectural changes with abnormal bifid glands and the absence of granulomas consistent with a diagnosis of ulcerative colitis (fig 1). Barium meal and follow through was normal. Over the following four months outpatient management with sulphasalazine in combination with topical/oral steroids and with the subsequent addition of azathioprine failed to control his colitis. Repeat endoscopy confirmed severe total colitis necessitating hospital admission for intravenous steroid therapy. Severe colitis persisted and intravenous cyclosporin was instituted to which he remained refractory. His condition deteriorated and he underwent total colectomy with ileostomy. At laparotomy the small bowel was noted to be normal. Histology confirmed an acute on chronic pancolitis with normal terminal ileum. His postoperative recovery was complicated by bilateral pneumonia,

Department of
Gastroenterology,
Meath/Adelaide
Hospitals, Dublin,
Ireland

N P Breslin
A Todd
C O'Morain

Department of
Pathology, St James
Hospital, Dublin,
Ireland
C Kilgallen

Correspondence to:
Dr N Breslin, Registrar in
Gastroenterology, Endoscopy
Office, Meath Hospital,
Heytesbury Street, Dublin 8,
Ireland.

Accepted for publication
25 March 1997

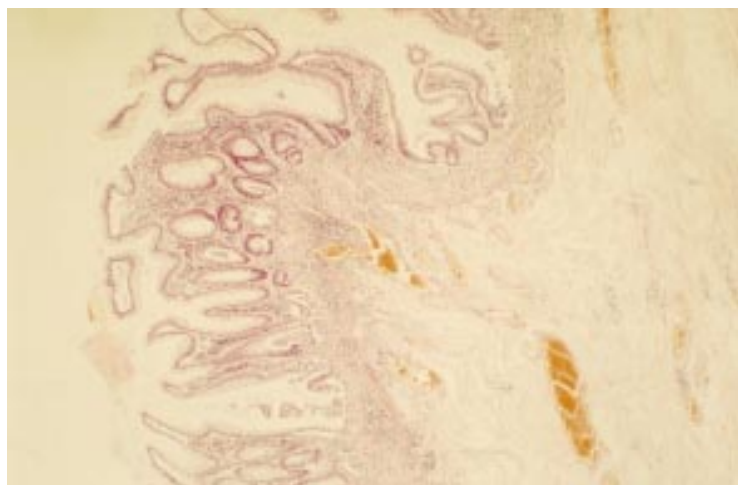


Figure 1: Low power photomicrograph of mucosal biopsy specimen (twin 1) stained with haematoxylin and eosin showing superficial inflammation limited to the muscularis mucosae and underlying submucosal oedema without inflammation.

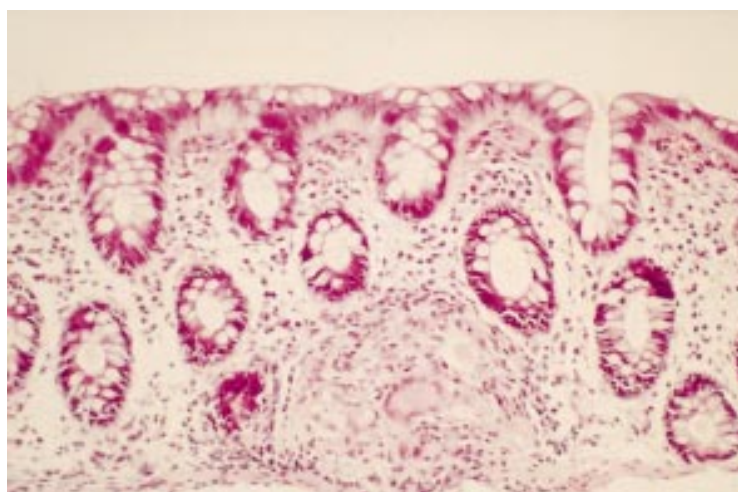


Figure 2: High power photomicrograph of mucosal biopsy specimen (twin 2) stained with haematoxylin and eosin showing a granuloma and giant cell.

methicillin resistant staphylococcal septicaemia, wound dehiscence, and pulmonary embolism. He was however discharged on day 39. Over the subsequent 18 months he had persisting blood stained discharge from his rectal stump despite medical therapy and he subsequently underwent elective proctectomy. He has since remained well.

Twin 2's referral for investigation of a five year history of episodic blood stained diarrhoea was prompted by the diagnosis of ulcerative colitis in his identical twin brother two months previously. At this time he was otherwise well

TABLE 1 Genetic typing

Blood typing	Twin 1	Twin 2
ABO group	O positive	O positive
Rhesus type	R1 R2	R1 R2
Duffy	Fy (A negative/B positive)	Fy (A negative/B positive)
Kidd	JK (A positive/B negative)	JK (A positive/B negative)
Lewis	Le (A negative/B positive)	Le (A negative/B positive)
MNSs	M positive N positive S positive s positive	M positive N positive S positive s positive
HLA typing	A1-B8-DR3-DR52-DQ2	A1-B8-DR3-DR52-DQ2

and denied symptoms of current or previous extraintestinal disease.

Physical examination was unremarkable. Laboratory investigations including full blood count, erythrocyte sedimentation rate, and liver profile were normal. Colonoscopy showed patchy inflammation to 20 cm with aphthoid ulcers. Serial colonic biopsy specimens from the hepatic flexure and distally confirmed patchy inflammation with acute cryptitis. Non-caseating granulomata were found in biopsy specimens from four out of six sites (fig 2). Barium meal and follow through examination was normal. A diagnosis of colonic Crohn's disease was made. He was treated with sulphasalazine and latterly olsalazine to control his symptoms.

Both twins were born as full term normal deliveries and pregnancy was uncomplicated. Both received standard childhood vaccinations available at the time which did not include the measles vaccine. However, both developed measles at around eight years of age, although this is not documented in their family practitioner's records. Both underwent tonsillectomy aged four and both developed a transient febrile icteric illness associated with elevated aminotransferases at 12 years of age and attributed to hepatitis A without serological confirmation. Both are non-smokers, although three regular household members were smokers at the time of disease onset. They have five older siblings all of whom are healthy. The twins' father died aged 53 years as a result of carcinoma of the oral cavity. Their mother is alive and well.

Twins 1 and 2 are identical in appearance and their monozygosity was assessed by detailed genetic typing including rhesus type, ABO blood group, and other red cell antigens. HLA typing confirmed monozygosity with both twins expressing the haplotype HLA A1-B8-DR3-DR52-DQ2 (table 1). Class I and II antigens were determined by lymphocytotoxicity methods.

Perinuclear antineutrophil cytoplasmic antibodies were negative in twin 1 and positive in twin 2 with a titre of 1/40 using an indirect immunofluorescence technique (Inova). However, sampling in twin 1 was performed after he underwent total colectomy but before his subsequent proctectomy.

Discussion

This is the first documented case report where monozygotic twins have developed inflammatory bowel disease that is discordant in overall type, disease distribution, clinical course, response to therapy, and extraintestinal manifestations. It underlines the long held belief that common inherited factors predispose to the development of inflammatory bowel disease and on which environmental factors act to determine disease expression and phenotype.

The strongest risk factor for developing inflammatory bowel disease is a positive family history. Crude and age adjusted empirical risks for developing inflammatory bowel disease in relatives of affected individuals are at least ten-fold greater than the community wide

prevalence.¹¹⁻¹² Recent large familial studies in Crohn's disease have found a higher concordance for age at diagnosis,¹¹ disease location,^{4, 11, 13} disease extent,¹³ disease pattern,^{4, 13} and operative requirements⁴ in patients with a family history of Crohn's disease than in sporadic cases. Although the overall type of inflammatory bowel disease usually breeds true in familial cases, mixed families in which some members are affected with Crohn's disease and others with ulcerative colitis are not uncommon.²

Twin case reports in the literature are manifold and describe both monozygotic and dizygotic twin pairs. In all of these one or both twins are affected by the same type of inflammatory bowel disease.⁹ Tysk *et al* used the Swedish twin registry and inpatient hospital records to identify twins affected by inflammatory bowel disease.⁹ Monozygotic twins with ulcerative colitis had a proband concordance of 6.3%. None of the dizygotic twins with ulcerative colitis were concordant. Monozygotic twins with Crohn's disease had proband concordance of 58.3% while dizygotic twins had proband concordance of 3.9%. A total of 80 twin pairs were considered (34 monozygotic) and despite discordance for presence or absence of inflammatory bowel disease no pair was affected by both ulcerative colitis and Crohn's disease. The authors calculated the heritability of liability for ulcerative colitis to be 0.53 and that for Crohn's disease to be 1.0 suggesting a much larger genetic influence in Crohn's disease. They also considered a further 19 monozygotic twins with ulcerative colitis reported in the literature and found concordance in nine, and 27 monozygotic twins with Crohn's disease of whom 24 were concordant. There were no cases of mixed inflammatory bowel disease.

Thomson *et al* traced 144 twin pairs with inflammatory bowel disease from 16 000 members of the National Association for Colitis and Crohn's Disease.¹⁰ Six of 38 monozygotic twins with ulcerative colitis and five of 25 with Crohn's disease were concordant for the disease. The relative risk for an unaffected identical twin developing inflammatory bowel disease compared with that for a non-identical twin was 3.49 ($p=0.03$). Once again, in the majority of cases only one twin had developed overt inflammatory bowel disease; however, there was no pair of twins with mixed inflammatory bowel disease. These studies and case reports all indicate a higher concordance for inflammatory bowel disease in monozygotic than dizygotic twins suggesting that genetic factors rather than environmental factors play the primary role in disease pathogenesis.

Genetic influences in inflammatory bowel disease are complicated and are likely to involve genetic heterogeneity, oligogenic inheritance, and incomplete penetrance.¹⁴ A putative Crohn's susceptibility locus on chromosome 16 has recently been identified in two independent panels of families with multiple affected members.¹⁵ A number of candidate genes with immunoregulatory functions are located in this region.

Antineutrophil cytoplasmic antibodies exhibiting a perinuclear pattern of staining (pANCA) are found with a higher frequency in patients with ulcerative colitis than in Crohn's disease or in the general population.¹⁶ pANCA are also found with increased frequency in relatives of patients with ulcerative colitis although the probands need not necessarily be positive themselves.¹⁷ In our report, twin 1 with ulcerative colitis was ANCA negative while his genetically identical twin with Crohn's disease was pANCA positive. However, twin 1's ANCA analysis was performed three months after he underwent colectomy but before his persistently inflamed rectal stump was excised. Aitola *et al* found that at a mean of 24 months post-proctocolectomy, 10/14 patients positive for ANCA preoperatively had reduced titres and two had become negative.¹⁸ There are no data regarding changes in ANCA status in patients with persistently inflamed rectal stumps. Two studies have localised the production of ANCA to lymphocytes in the lamina propria of the colon in patients with ulcerative colitis.^{19, 20} It is possible therefore that titres could be reduced or indeed negative in patients who have undergone total colectomy. Recent Scandinavian studies have found that patients with colonic Crohn's disease can have a similar ANCA seroprevalence to patients with ulcerative colitis.²¹⁻²³ Therefore, it is not surprising that twin 2 was ANCA positive and we suggest that twin 1's negative ANCA status relates to the timing of sampling. However, it should be noted that in a study of monozygotic twins discordant for ulcerative colitis, Yang *et al* found that only 20% of healthy twin siblings were ANCA positive.²⁴

Associations between inflammatory bowel disease and class I HLA antigens, with the exception of patients with coexistent ankylosing spondylitis or primary sclerosing cholangitis, are weak.^{25, 26} Studies of class II antigens indicate a higher prevalence of HLA DR2 in ulcerative colitis than in controls; this association is most pronounced in patients with total colonic involvement.²⁷⁻²⁹ Interestingly, Satsangi *et al*, in a population based association study, found that the haplotype DR3-DQ2, as expressed by our twins, was associated with extensive ulcerative colitis.³⁰ In Crohn's disease evidence for an HLA association is lacking.³⁰

The role of environmental factors in the pathogenesis of inflammatory bowel disease is a source of ongoing controversy. This case report and the lack of complete concordance in other monozygotic twin studies underlines the crucial role played by external factors in the determination of disease expression in patients with genetic susceptibility to inflammatory bowel disease. Non-smoking or a cessation of smoking is a proven risk factor for developing ulcerative colitis³¹ and patients with Crohn's disease are more likely to be smokers.³² However, at the time of disease onset neither of the twins in this case report had ever smoked themselves, although both were exposed to the effects of passive smoking. It has been suggested that appendectomy offers protection against the development of ulcerative colitis;

however, neither twin had had his appendix removed prior to disease onset.³³

A variety of infectious agents have been implicated in the aetiology of Crohn's disease, most notably *Mycobacterium paratuberculosis*,³⁴ *Listeria monocytogenes*,³⁵ measles vaccine,³⁶ or the early acquisition of measles virus.³⁷ However, both twins have historical evidence of measles infection occurring at around eight years of age and twin 2 has not undergone a surgical resection which might allow documentation of evidence of either of the latter two infections. Alterations in gut flora have been implicated in the pathogenesis of ulcerative colitis.³⁸ However, it would not be possible to assess this in our twin pair, one of whom has already undergone a staged panproctocolectomy. We were unable to elicit any differences in dietary habits or stressful life events between the twins.

Genetic factors have a major influence on susceptibility to develop inflammatory bowel disease as is evidenced by monozygotic and dizygotic twin studies. However, this novel case report, in which we present unequivocal evidence of phenotypically discordant inflammatory bowel disease in identical twins, emphasises the important role played by external factors in determining disease phenotype. In spite of careful case review we were unable to identify the factors which resulted in differential expression of inflammatory bowel disease type. This report adds weight to the view that Crohn's disease and ulcerative colitis share susceptibility genes and that they represent different ends of the spectrum of the same disease.

- 1 Kirsner JB. Genetic aspects of inflammatory bowel disease. *Clin Gastroenterol* 1973; 2: 557-75.
- 2 Orholm M, Munkholm P, Langholz E, Neilsen OH, Sorensen TA, Binder V. Familial occurrence of inflammatory bowel disease. *N Engl J Med* 1991; 324: 84-8.
- 3 Lewkonia RM, McConnell RB. Familial inflammatory bowel disease—heredity or environment? *Gut* 1976; 17: 235-43.
- 4 Bayless TM, Tokayer AZ, Polito II JM, Quaskey SA, Mellits ED, Harris ML. Crohn's disease: concordance for site and clinical type in affected family members—potential hereditary influences. *Gastroenterology* 1996; 111: 573-9.
- 5 Webb LR. The occurrence of chronic ulcerative colitis in twin males. *Gastroenterology* 1950; 15: 523-4.
- 6 Mayberry JF, Dew MJ, Morris JS. Monozygotic twins with ulcerative colitis. *Postgrad Med J* 1982; 58: 112-4.
- 7 Hislop IG, Grant AK. Genetic tendency in Crohn's disease. *Gut* 1969; 10: 994-5.
- 8 Klein GL, Ament ME, Sparks RS. Monozygotic twins with Crohn's disease. A case report. *Gastroenterology* 1980; 79: 931-3.
- 9 Tysk C, Lindberg G, Jarnerot G, Floderus-Myrhed B. Ulcerative colitis and Crohn's disease in an unselected population of monozygotic twins and dizygotic twins. A study of heritability and the influence of smoking. *Gut* 1988; 29: 990-6.
- 10 Thompson NP, Driscoll R, Pounder RE, Wakefield AJ. Genetics versus environment in inflammatory bowel disease: results of a British twin study. *BMJ* 1996; 312: 95-6.
- 11 Peeters M, Nevens H, Baert F, Hiele M, De Meyer A-M, Vlietinck R, Rutgeerts P. Familial aggregation in Crohn's disease: increased age adjusted risk and concordance in clinical characteristics. *Gastroenterology* 1996; 111: 597-603.
- 12 Fielding JF. The relative risk of inflammatory bowel disease in relatives and siblings of Crohn's disease patients. *J Clin Gastroenterol* 1986; 8: 655-7.
- 13 Colombel JF, Grandbastien B, Gower-Rousseau C, Plegat S, Evrard JP, Dupas JL, et al. Clinical characteristics of Crohn's disease in 72 families. *Gastroenterology* 1996; 111: 604-7.
- 14 Duerr RH. Genetics of inflammatory bowel disease. *Inflammatory Bowel Diseases* 1996; 2: 48-60.
- 15 Hugot JP, Laurent-Puig P, Gower-Rousseau C, Olson JM, Lee JC, Beaugier L, et al. Mapping of a susceptibility locus for Crohn's disease on chromosome 16. *Nature* 1996; 379: 821-3.
- 16 Seibold F, Klein R, Slametschka AD, Weber P, Gregor M. Neutrophil autoantibodies: a genetic marker in primary sclerosing cholangitis and ulcerative colitis. *Gastroenterology* 1994; 107: 532-6.
- 17 Shanahan F, Duerr RH, Rotter JJ, Yang Y, Sutherland LR, McElree C, et al. Neutrophil autoantibodies in ulcerative colitis; familial aggregation and genetic heterogeneity. *Gastroenterology* 1992; 103: 456-61.
- 18 Aitola P, Miettinen A, Mattila A, Matikainen A, Soppi E. Effect of proctocolectomy on serum antineutrophil cytoplasmic antibodies in patients with chronic ulcerative colitis. *J Clin Pathol* 1995; 48: 645-7.
- 19 Billing P, Tahir S, Calfin B, Gagne G, Cobb L, Targan S, Vidrich A. Nuclear localisation of the antigen detected by ulcerative colitis associated perinuclear antineutrophil cytoplasmic antibodies. *Am J Pathol* 1995; 147: 979-87.
- 20 Targan SR, Landers CJ, Cobb L, McDermott UP, Vidrich A. perinuclear antineutrophil cytoplasmic antibodies are spontaneously produced by mucosal B cells of ulcerative colitis patients. *J Immunol* 1995; 155: 3262-7.
- 21 Lindgren S, Floren CH, Lindhagen T, Starck M, Stewenius J, Nassberger L. Low prevalence of antineutrophil cytoplasmic antibodies in ulcerative colitis patients with long term remission. *Eur J Gastroenterol Hepatol* 1995; 7: 563-8.
- 22 Schumacher G, Kollberg B, Sansedt B, Ljungh A, Nassberger L. Circulating granulocyte antibodies in first attacks of colitis. *Scand J Gastroenterol* 1995; 30: 157-63.
- 23 Hertevig E, Weislander J, Johansson C, Wiik A, Nilsson A. Circulating antineutrophil cytoplasmic antibodies in chronic inflammatory bowel disease. *Scand J Gastroenterol* 1995; 30: 693-8.
- 24 Yang P, Janerot G, Danielsson D, Tysk C, Lindberg E. p-ANCA in monozygotic twins with inflammatory bowel disease. *Gut* 1995; 36: 887-90.
- 25 Russell AS. Arthritis, inflammatory bowel disease, and histocompatibility antigens. *Ann Intern Med* 1977; 86: 820-1.
- 26 Chapman RW. Aetiology and natural history of primary sclerosing cholangitis: a decade of progress? *Gut* 1991; 32: 1422-5.
- 27 Toyada H, Wang S, Yang H, Redford A, Magalong D, Dyan D, et al. Distinct association of HLA class II genes with inflammatory bowel disease. *Gastroenterology* 1993; 104: 741-8.
- 28 Asakura H, Tsuchiya M, Aiso S, Watanabe M, Kobayashi K, Hibi T, et al. Association of human lymphocyte-DR2 antigen with Japanese ulcerative colitis. *Gastroenterology* 1982; 82: 413-8.
- 29 McConnell RB. Ulcerative colitis—genetics feature. *Scand J Gastroenterol* 1983; 18 (suppl 88): 14-6.
- 30 Satsangi J, Welch KJ, Bunce M, Julier C, Farrant MJ, Bell JI, Jewell DP. Contribution of genes of the major histocompatibility complex to susceptibility and disease phenotype in inflammatory bowel disease. *Lancet* 1996; 347: 1212-7.
- 31 Harries AD, Baird A, Rhodes J. Non-smoking—a feature of ulcerative colitis. *BMJ* 1982; 284: 707.
- 32 Tobin MV, Logan RFA, Langman MJS, McConnell RB, Gilmore IT. Cigarette smoking and inflammatory bowel disease. *Gastroenterology* 1987; 93: 316-21.
- 33 Rutgeerts P, D'Haens G, Hiele M, Geboes K, Vantrappen G. Appendectomy protects against ulcerative colitis. *Gastroenterology* 1994; 106: 1251-3.
- 34 Gitnick G, Collins J, Beaman B, Brooks D, Arthur M, Imaeda T, et al. Preliminary report on isolation of mycobacteria from patients with Crohn's disease. *Dig Dis Sci* 1989; 34: 925-32.
- 35 Liu Y, Kruiningen HJ, West AB, Cartun RW, Cortot A, Colombel JF. Immunocytochemical evidence of *Listeria*, *Escherichia coli* and streptococcal antigens in Crohn's disease. *Gastroenterology* 1995; 108: 1396-404.
- 36 Thompson NP, Montgomery SM, Pounder RE, Wakefield AJ. Is measles vaccination a risk factor for inflammatory bowel disease? *Lancet* 1995; 345: 1071-4.
- 37 Wakefield AJ, Ekbom A, Dhillon AP, Pitillo RM, Pounder RE. Crohn's disease: pathogenesis and persistent measles virus infection. *Gastroenterology* 1995; 108: 911-6.
- 38 Taroug JD, Richardson JA, Croft JT, Simmons WA, Zhou M, Fernandez-Sueiro JL, et al. The germ free state prevents development of gut and joint inflammatory disease in HLA-B27 transgenic rats. *J Exp Med* 1994; 180: 2359-64.

4. Please check page numbers.
5. Authors 5 & 6?