

CASE REPORT

Management of fibrosing pancreatitis in children presenting with obstructive jaundice

F A Sylvester, B Shuckett, E Cutz, P R Durie, M A Marcon

Abstract

Background—Children with fibrosing pancreatitis are conventionally treated surgically to relieve common bile duct (CBD) obstruction caused by pancreatic compression. Residual pancreatic function has not been formally tested in these patients.

Aims—To evaluate the usefulness of non-surgical temporary drainage in children with fibrosing pancreatitis and to assess pancreatic function after resolution of their CBD obstruction.

Patients—Four children (1.5–13 years; three girls).

Methods and results—Abdominal sonography and computed tomography revealed diffuse enlargement of the pancreas, predominantly the head. The CBD was dilated due to compression by the head of the pancreas. Pancreatic biopsy specimens obtained in three patients showed notable acinar cell atrophy and extensive fibrosis. Cystic fibrosis was excluded. No other cause of pancreatitis was identified. Pancreatic tissue from one patient contained viral DNA sequences for parvovirus B19 detected by polymerase chain reaction; serum IgM to parvovirus was positive. Three patients had temporary drainage of the CBD and one patient underwent a choledochojunostomy. Serial imaging studies revealed resolution of the CBD obstruction with reduction in pancreatic size. Exocrine pancreatic function deteriorated. Three patients developed pancreatic insufficiency within two to four months of presentation. The fourth patient has notably diminished pancreatic function, but remains pancreatic sufficient. None has diabetes mellitus.

Conclusions—Temporary drainage of the CBD obstruction is recommended in fibrosing pancreatitis in children along with close monitoring of the clinical course, before considering surgery.

(Gut 1998;43:715–720)

Keywords: pancreatitis; jaundice; common bile duct obstruction; children

has been well documented in adults.¹ In adults, symptoms of chronic pancreatitis are usually associated with excessive alcohol consumption. In children, chronic pancreatitis is rare and an association between CBD obstruction and chronic pancreatitis is even more unusual.^{2,3} In fact, in childhood the combination of CBD obstruction and chronic pancreatitis has only been reported in 32 patients with fibrosing pancreatitis, all of whom were treated surgically.^{4–6} We describe here four patients with no prior history of pancreatic disease who were referred to our hospital with CBD obstruction. These four patients share many common clinical features consistent with previous reports of chronic fibrosing pancreatitis, but all developed notable loss of exocrine pancreatic function. The CBD obstruction was successfully treated with non-surgical methods in three patients.

Methods

Detection of parvovirus B19 genome with in situ polymerase chain reaction (PCR) (Dr M Zielenska, Laboratory of Molecular Pathology, Hospital for Sick Children) was performed on paraffin wax sections from a pancreatic biopsy specimen of patient 2 and a control (a 12 year old male with lymphoma who had a pancreatic biopsy to investigate disease extension, with normal pancreatic histology). The primers were two commercially available oligonucleotides from the NS 1 gene (Dalton Chemical Laboratories Inc., Toronto, Ontario, Canada) as previously described.⁷

Case reports

Four children who presented with rapid onset of cholestasis were found to have CBD obstruction due to extrinsic compression by the head of the pancreas. None had prior history of pancreatic dysfunction or recurring pancreatitis. Imaging studies provided confirmation of notable pancreatic swelling with extrinsic compression of the distal CBD. The pancreas appeared to be diffusely affected, but the head of the pancreas was more prominently enlarged. Serum trypsinogen and amylase were normal or only slightly elevated in all patients, consistent with previous reports of fibrosing pancreatitis.⁵ Three patients required temporary relief of the biliary obstruction, and in the remaining patient a definitive surgical

Division of
Gastroenterology and
Nutrition
F A Sylvester
P R Durie
M A Marcon

Department of
Radiology and Imaging
B Shuckett

Department of
Pathology, The
Hospital for Sick
Children, Department
of Pediatrics,
University of Toronto,
Ontario, Canada
E Cutz

Correspondence to:
Dr M A Marcon, The
Hospital for Sick Children,
Division of Gastroenterology
and Nutrition, 555
University Avenue, Toronto,
Ontario M5G 1X8, Canada.

Accepted for publication
29 April 1998

The association between common bile duct (CBD) obstruction and chronic pancreatitis

Table 1 Laboratory values at presentation and key clinical events

Case	Event	Bilirubin ($<17 \mu\text{mol/l}$)*		Alkaline phosphatase (185–425 U/l)	Amylase (20–40 U/l)	AST ($<45 \text{ U/l}$)	ALT ($<40 \text{ U/l}$)	Cholesterol (3.2–4.4 mmol/l)	GGT ($<45 \text{ U/l}$)	Sweat chloride ($<40 \text{ mmol/l}$)	Trypsinogen (16.9–45.3 $\mu\text{g/l}$)
		Total	Direct								
1	Admission	126	109	663	145	184	306	5.82	ND	<10	14
	Pre-drain placement	144	128	845	124	194	309	ND	683		
	Post-drain placement	47	37	630	<30	43	44	ND	232		
	Pre-stent removal	<18		262	30	ND	48	ND	ND		
2	Admission	16	9	824	38	195	167	ND	891	18	27.9
	ERCP	3	<1	465	52	43	45	ND	282		
	Pre-liver biopsy	1	<1	217	ND	23	26	ND	ND		
3	Admission	39	26	411	<30	121	290	5.88	172	23	ND
	Pre-stent placement	50	32	485	40	70	93	ND	68		
	Pre-stent removal	6	4	190	37	58	64	ND	20		
4	Admission	54	39	2296	46	294	316	ND	713	<10	19.9
	Post-drain placement	12	5	1319	ND	104	159	ND	623		
	Post-drain removal	1	1	240	ND	39	41	ND	15		

Normal reference values are shown in parentheses.

*Total bilirubin.

ND, not done.

procedure was carried out because of histological evidence suggestive of liver damage secondary to persistent biliary obstruction. With time the exocrine pancreas atrophied, coinciding with relief of the CBD obstruction and

deterioration of pancreatic exocrine function. Overt signs and symptoms of pancreatic insufficiency occurred in three patients while the fourth showed a notable reduction in exocrine pancreatic function. Pancreatic biopsy specimens obtained from three patients at presentation confirmed fibrotic pancreatic atrophy.

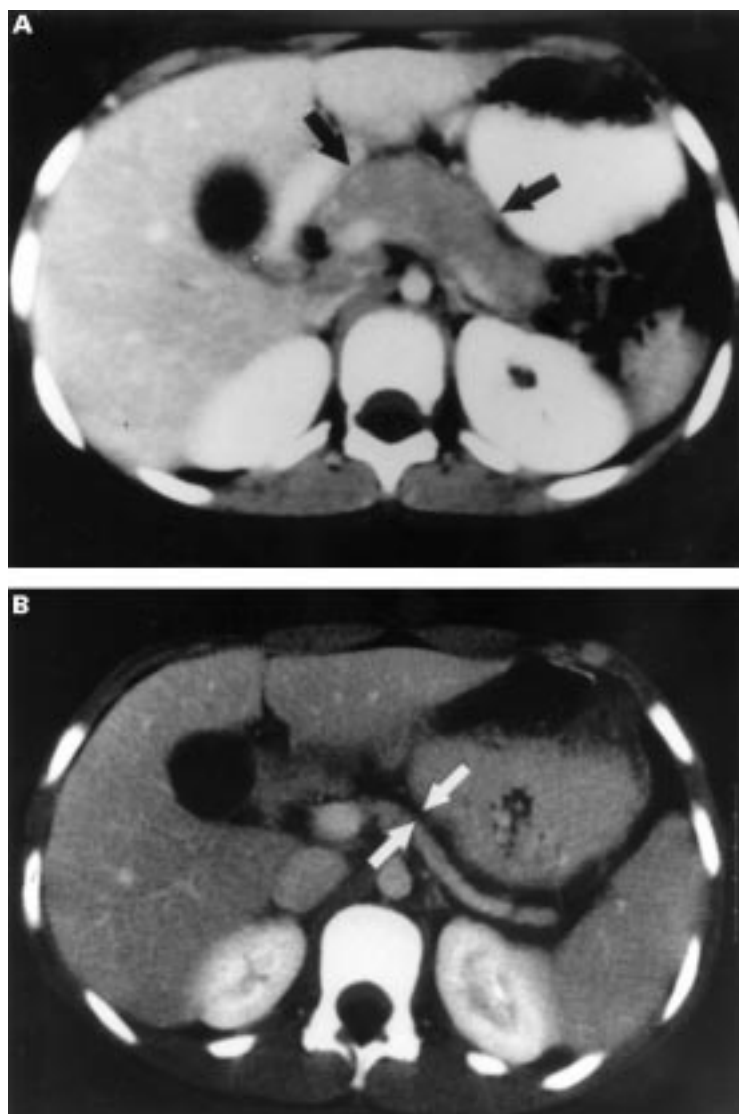


Figure 1 Abdominal CT scan of patient 1 at presentation (A) shows diffuse enlargement of the pancreas (black arrows). A follow up CT 18 months later (B) reveals pancreatic atrophy (space between white arrows).

PATIENT 1

A previously healthy 7.5 year old Caucasian girl was referred with a two week history of postprandial crampy epigastric abdominal pain and a three day history of jaundice. Her past medical history was unremarkable. Her weight was 23.8 kg (50th percentile) and height was 124 cm (50th percentile). On physical examination she was jaundiced. Her liver, palpable just below the right costal margin, was slightly tender. Table 1 shows laboratory results on admission. Serology for viral hepatitis (including hepatitis viruses A, B, and C, herpes simplex, cytomegalovirus (CMV), enterovirus, Epstein-Barr virus (EBV), and adenovirus) and parvovirus was negative. Antinuclear (ANA), antismooth muscle (ASM), and antimitochondrial (AMA) antibodies were also negative. An abdominal ultrasound scan revealed mild dilatation of both the intrahepatic and extrahepatic bile duct systems. An abdominal computed tomography (CT) scan showed a diffusely enlarged pancreas (fig 1). A percutaneous cholangiogram (PTC) revealed a tight stricture of the CBD at the level of the pancreatic head, dilated CBD, and low insertion of the cystic duct (fig 2). A stent was placed percutaneously in the CBD. Endoscopic retrograde cholangiopancreatography (ERCP), performed after three months, showed that the intrapancreatic portion of the CBD was narrowed, but the duct was not dilated. Therefore the stent was removed.

After two months of good health, she complained of loose stools. A 72 hour faecal fat collection showed losses of 28% of dietary intake of fat. A liver biopsy showed portal fibrosis and ductal changes compatible with previous biliary obstruction. Serum immunoreactive trypsinogen was 9.1 $\mu\text{g/l}$ (normal 16.9–45.3 $\mu\text{g/l}$).⁸ A pancreatic stimulation test⁸ confirmed pancreatic insufficiency (table 2). A sweat chloride test was normal (table 1) and

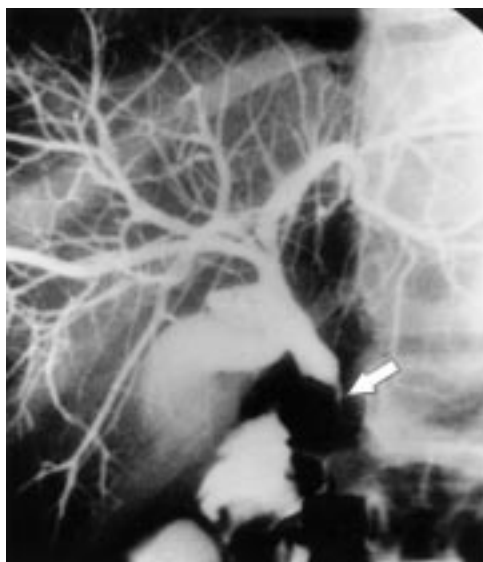


Figure 2 Percutaneous cholangiogram of patient 1 at presentation. The white arrow indicates circumferential compression of the CBD by the head of the pancreas.

extensive screening for cystic fibrosis mutations performed in the laboratory of Dr Peter Ray (Department of Genetics, Hospital for Sick Children) was negative. She was placed on fat soluble vitamins and pancreatic enzyme supplements and her diarrhoea improved. She is presently asymptomatic and growing well after a 3.5 year follow up. She has had one episode of glycosuria, but her haemoglobin A_{1c} remained normal. Follow up CT images of her abdomen reveal persistent diffuse pancreatic atrophy (fig 1).

PATIENT 2

A five year old, previously asymptomatic Caucasian girl was hospitalised following a three week history of nocturnal abdominal pain and a one week history of anorexia, fever, and lethargy. A few days prior to admission she became jaundiced. She had a prior medical history of vesicoureteral reflux requiring prophylactic cotrimoxazole. On physical examination she was jaundiced. She weighed 21 kg (75th percentile). Her liver was palpable 2 cm below the right costal margin. Table 1 shows laboratory results on admission. ANA was positive, 1/640 (fine speckled, chromosome negative), but became negative on follow up. ASM and AMA were negative. Screening for serum antibodies to adenovirus and enterovirus was negative. IgM to parvovirus was positive. Abdominal ultrasound and CT scan showed dilated intrahepatic and extrahepatic bile ducts, an enlarged pancreas (particularly its head), and sludge in the gall bladder. One week later an ERCP showed compression of

the intrapancreatic portion of the CBD with mild proximal dilatation. There was no evidence of intrahepatic or extrahepatic bile duct beading or irregularity. The main pancreatic duct appeared scarred and small, with proximal dilatation, consistent with chronic pancreatitis.

Two months later she began complaining of greasy stools. A 72 hour faecal fat collection confirmed steatorrhoea and a pancreatic stimulation test provided documentation of pancreatic insufficiency (see table 2). Cystic fibrosis was excluded by nasal potential difference measurements,⁹ sweat chloride, and extensive screening for cystic fibrosis mutations. Due to persistent cholestasis, a liver biopsy was performed, which showed portal inflammation, low grade pericholangitis, patchy steatosis, and perilobular fibrosis, consistent with extrahepatic biliary obstruction. A choledochojejunostomy was performed. A wedge liver biopsy obtained at surgery revealed only slight portal fibrosis. A biopsy of the pancreas revealed notable fibrosis, parenchymal atrophy, surviving islets, and a few chronic inflammatory cells (fig 3). Viral sequences for parvovirus B19 were detected by in situ PCR in this particular pancreatic biopsy specimen but not in control tissue. Following recovery from surgery she was placed on pancreatic enzyme replacement. She remains asymptomatic with normal growth 2.5 years after initial presentation. She had a normal liver biopsy at follow up.

PATIENT 3

A 13 year old Caucasian boy presented with a six week history of abdominal pain and non-bilious vomiting. Shortly before admission he became anorexic and developed jaundice, pale stools, and choluria. There was no prior history of pancreatic disease. His father has hyperlipidaemia. His weight was 59.7 kg (90th percentile) and his height 151 cm (25th percentile). He was jaundiced. Abdominal examination revealed right upper quadrant tenderness and mild hepatomegaly. Table 1 shows laboratory findings on admission. Serology was negative for hepatitis viruses A, B, and C, CMV, and EBV. ANA and ASM were negative. Serology for parvovirus revealed the presence of IgG but not IgM antibodies, suggestive of past infection. An abdominal CT scan showed an enlarged pancreatic head with signal characteristics similar to the rest of the pancreas, CBD dilatation, and mild pancreatic duct dilatation. An ERCP identified a distal CBD stricture. A stent was placed to relieve the obstruction. An ultrasound guided percutaneous pancreatic biopsy revealed extensive fibrosis, with some focal areas of inflammation within the parenchyma (fig 3). There was no evidence of malignancy. Two months after the onset of symptoms he developed greasy, bulky stools. Steatorrhoea was documented by 72 hour faecal fat and he was commenced on pancreatic enzyme replacement therapy. A pancreatic stimulation test confirmed the presence of pancreatic insufficiency (table 2). His stent was removed four months after clinical presentation. He remains asymptomatic after 1.5 years

Table 2 Results of pancreatic stimulation tests

Patient	Total water (9.5 (2.7) ml/kg/h)	Trypsin (2437 (887) U/kg/h)	Co-lipase (12810 (6177) U/kg/h)	Total lipase (19744 (8880) U/kg/h)
1	9.72	46	65	122
2	8.37	43	74	91
3	7.4	46	198	239
4	10.3	677	1705	4588

Normal reference values are shown in parentheses.⁸

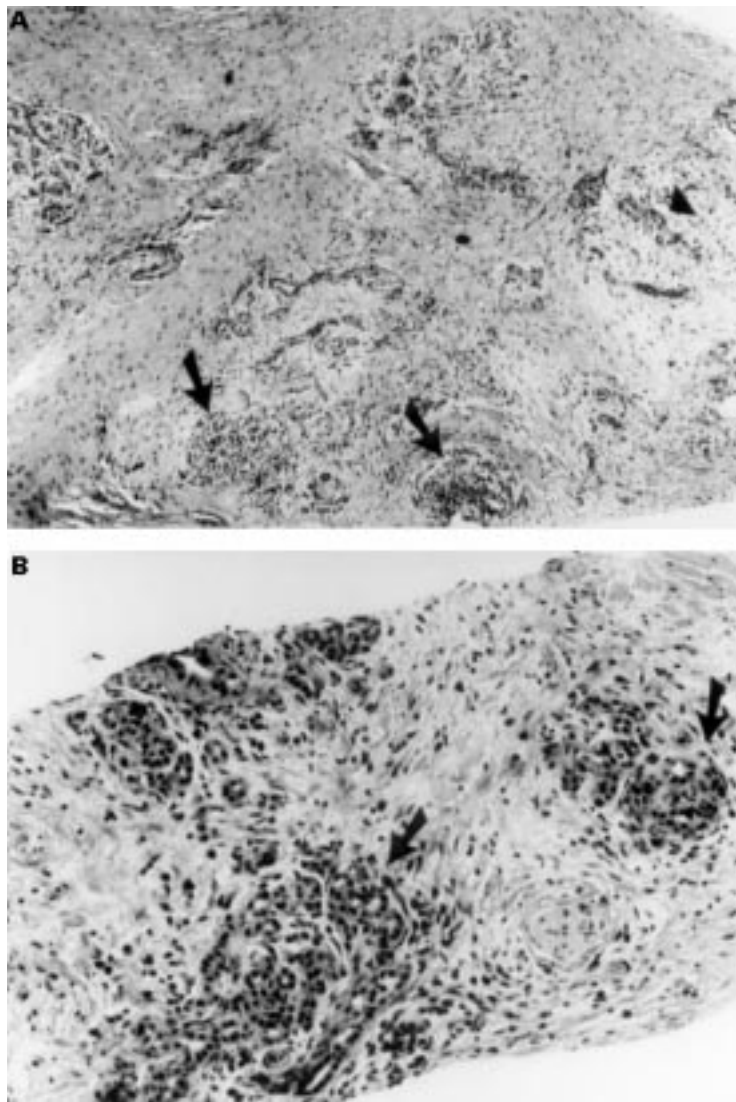


Figure 3 Pancreatic biopsy specimens. Patient 2 (A): arrows show islets of Langerhans and arrowhead a cluster of ductules. Extensive fibrosis is prominent. Patient 3 (B): arrows point to remaining pancreatic ductules surrounded by extensive fibrosis.

but serial abdominal CT scans show evidence of progressive pancreatic atrophy.

PATIENT 4

A 16 month old Caucasian girl was referred with sudden onset of jaundice and ultrasound evidence of CBD dilatation. Her past history was unremarkable. Three weeks prior to admission she had fever and a diffuse rash that subsided after two days. Two weeks later she developed pale stools and jaundice. Her weight was 9.6 kg (10th percentile) and her length 78.5 cm (50th percentile). On physical examination the liver was palpated 5 cm below the right costal margin and the spleen was 4 cm below the left costal margin. Table 1 shows laboratory studies on admission. Screening for hepatitis A, B, and C, CMV, EBV, and for parvovirus was negative. ANA and ASM were negative. An exploratory laparotomy was performed based on a preoperative diagnosis of choledochal cyst. At surgery the pancreas was enlarged, particularly its head, and very hard. An intraoperative cholangiogram revealed that

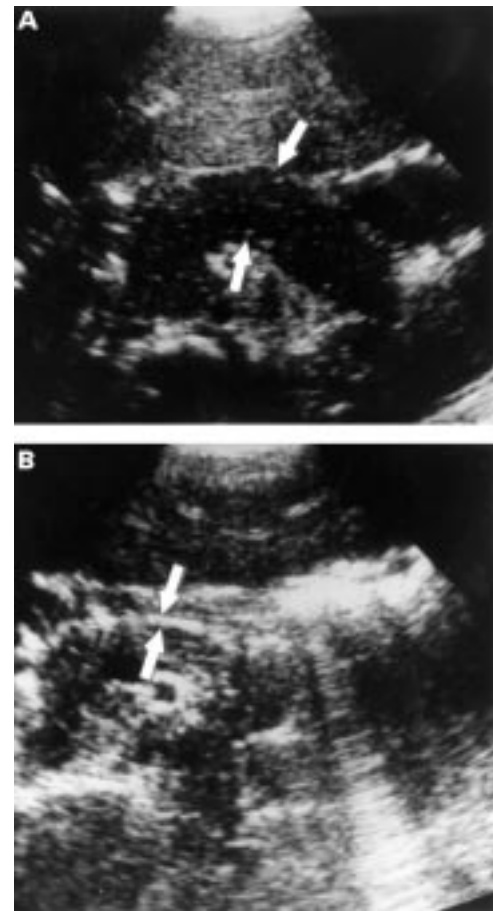


Figure 4 Abdominal sonogram of patient 4. Panel A shows diffuse pancreatic enlargement at presentation (arrows). Panel B reveals pancreatic atrophy 15 months later (space between arrows).

the head of the pancreas was impinging on the outflow of the biliary tree. The CBD was dilated, but there was no evidence of a choledochal cyst. A percutaneous drainage tube was inserted via a cholecystostomy. Transduodenal pancreatic biopsy specimens obtained during laparotomy showed notable fibrosis adjacent to duodenal mucosa, but no identifiable pancreatic tissue was present in the sample. Three months later the drainage tube was clamped and then removed. Her trypsinogen concentration at that time was 2.8 $\mu\text{g/l}$. Faecal fat loss was in the normal range. A pancreatic stimulation test confirmed evidence of notably reduced pancreatic function but she remains pancreatic sufficient (see table 2). After two years she remains well with no evidence of steatorrhoea, although serum immunoreactive trypsinogen concentrations remain low. Follow up ultrasonic images revealed decreased pancreatic size (fig 4).

Discussion

Obstructive jaundice as a consequence of circumferential compression of the intrapancreatic portion of the CBD was first recognised by Riedel in 1896.¹⁰ As more sophisticated imaging tools have been developed, our understanding of this clinical entity has evolved.¹ Since the advent of non-operative cholangiography by PTC or ERCP, gastroenterologists

have recognised a direct association between chronic pancreatitis and CBD stenosis.^{11 12} Most adult patients with this syndrome had developed chronic pancreatitis secondary to alcohol misuse.¹³⁻¹⁵ Based on these and other reports, it has been estimated that about 20% of adult patients with chronic pancreatitis develop CBD stenosis with cholestasis and jaundice.¹⁶

In children, bile duct stricture causing obstructive jaundice is rare, but when it occurs a wide variety of congenital and acquired causes should be considered. One of the most common congenital causes of CBD obstruction is due to an anomalous long common channel of the pancreatic and common bile duct, which is associated with cystic dilatation of the CBD (choledochal cyst).^{17 18} Choledochal cyst is also associated with pancreatitis.^{2 19 20} None of the patients in this report had evidence of a congenital anomaly of the extrahepatic bile ducts or a confirmed choledochal cyst. Compression of the CBD can be due to pancreatic neoplasm, but this is extremely rare.³ Eosinophilic gastroenteritis and duodenal Crohn's disease can cause inflammatory obstruction of the pancreatic and biliary ducts,^{21 22} but there was no evidence of inflammatory bowel disease in these patients. Children with cystic fibrosis and pancreatic sufficiency can have recurrent pancreatitis, not associated with CBD obstruction.²³ Intrapancreatic compression of the common bile duct has been reported in cystic fibrosis patients with pancreatic insufficiency.²⁴⁻²⁶ However, all investigations for cystic fibrosis were negative, including extensive screening for rare cystic fibrosis transmembrane regulator mutations. Two of our patients had transient hypercholesterolaemia but this probably occurred as a secondary consequence of biliary obstruction.²⁷ Patient 2 had a positive ANA on admission, which rapidly became negative without anti-inflammatory therapy, suggesting a false positive result.²⁸ This patient had no radiological or histological evidence of primary sclerosing cholangitis on admission or follow up. This patient was on cotrimoxazole, which has been associated with severe acute pancreatitis, but not with pancreatic inflammation causing CBD obstruction.²⁹ Thus, despite extensive investigations we were unable to identify any other pancreatic disorder which might be responsible for CBD obstruction in these patients. Furthermore, in three of the four patients described in this report, the diagnosis of fibrosing pancreatitis was confirmed by histological examination of pancreatic biopsy specimens.

The distal CBD courses through the pancreatic head in 85% of individuals, and in the remaining 15% it is located retropancreatically.³⁰ Therefore, it is not surprising that the distal CBD can be obstructed extrinsically within the intrapancreatic segment by a congenital anomaly, inflammation (pancreatitis), a tumour, or pancreatic pseudocyst (traumatic or postinflammatory).³¹ In acute pancreatitis mild hyperbilirubinaemia is relatively common.³² However, chronic pancreatitis lead-

ing to CBD obstruction and jaundice, although not unusual in adults, is very rare in children.^{4 33-35} Except for patients with cystic fibrosis, all reported cases of children who presented with jaundice as the initial manifestation of chronic pancreatitis, had fibrosing pancreatitis confirmed by laparotomy and pancreatic biopsy.^{5 6} There are no reports of CBD obstruction associated with other forms of chronic pancreatitis in children. For example, a long term retrospective follow up study of patients younger than 20 years of age with chronic hereditary or idiopathic pancreatitis that included 70 patients did not describe CBD compression as a complication.³⁶ Therefore, presentation with CBD obstruction in children is much more likely to be due to fibrosing pancreatitis than to other causes.

The aetiology of fibrosing pancreatitis is not known. Several indirect observations in this study suggest the possibility of an infectious aetiology. There was a suggestion of seasonality since three of four patients developed symptoms in early spring in different years. Two patients had a febrile illness two months before onset of symptoms. In one patient elevated serum IgM antibodies and viral sequences for parvovirus B19 were detected by PCR in pancreatic biopsy tissue. All other patients had negative IgM titres for parvovirus, although one had positive IgG suggesting a past infection. The transition from notable pancreatic swelling to pancreatic atrophy was dramatic, suggesting an acute infective or inflammatory process. Interestingly parvovirus infection has been associated with the development of hepatic fibrosis,⁷ but in this report the pancreas was not described. Further studies are needed to determine whether fibrosing pancreatitis is caused by a viral infection.

One of the most important aspects of our experience is the success of non-surgical management in these patients. Traditionally surgical decompression has been used to treat the extrinsic compression of the CBD in fibrosing pancreatitis.⁴⁻⁶ The diminution in pancreatic size seemed to relieve the severity of the CBD obstruction and with time normal biliary drainage occurred in three patients. In three of the patients described in this report, extrinsic CBD compression diminished as the pancreas atrophied, and the temporary drainage procedures were successfully discontinued. In retrospect, a similar course of events may have occurred in the fourth patient who underwent permanent surgical drainage of the biliary obstruction. Based on our experience, we recommend temporary drainage of the CBD obstruction and close monitoring of the clinical course, before entertaining surgical intervention. ERCP with stenting could be the preferred approach for drainage of the CBD, when technically feasible. Relatively non-invasive, cross sectional imaging studies, such as sonography and CT, are useful modalities for monitoring for evidence of resolution of CBD obstruction. Thus, once the diagnosis is established, invasive techniques such as PTC or ERCP seem to be unnecessary.

Overt pancreatic insufficiency developed over time in three patients and in the fourth there was evidence of severely impaired pancreatic function. Loss of pancreatic acinar tissue seemed to have occurred at clinical presentation. Loss of pancreatic function was confirmed by quantitative pancreatic function tests. The three children who developed pancreatic insufficiency did so early on. The fourth has remained pancreatic sufficient as determined by faecal fat measurements during the two years of follow up. Previous reports of 32 children with fibrosing pancreatitis in children suggested that steatorrhea due to pancreatic insufficiency was an unusual complication.^{5,6} However, none of these patients had quantitative assessment of exocrine pancreatic function by direct intubation studies. As this condition is characterised by extensive pancreatic fibrosis with loss of acinar tissue, we strongly recommend careful assessment of pancreatic function at initial presentation and serial assessment following diagnosis.

In summary, four previously asymptomatic children presented with fibrosing pancreatitis. All had biliary obstruction and jaundice secondary to pancreatic compression of the CBD. The compression of the CBD subsided with time, but exocrine pancreatic function deteriorated in association with evidence of continuing pancreatic atrophy. Three children developed pancreatic insufficiency within months of presentation. Future studies should determine the potential role of an infectious agent in the aetiology of this condition.

Peter R Durie is supported by operating grants from the Canadian Cystic Fibrosis Foundation.

- 1 Littenberg G, Afroudakis A, Kaplowitz N. Common bile duct stenosis from chronic pancreatitis: a clinical and pathologic spectrum. *Medicine* 1979;58:385-412.
- 2 Alvear DT, Petro J. Recurrent pancreatitis and jaundice. Report of a case in an eleven-year-old girl. *Am Surg* 1976;42:358-60.
- 3 Chapoy P, Lagier P, Ament A, et al. Stenose des voies biliaires chez l'enfant. Problemes diagnostiques a propos de 5 observations. *Chir Pediatr* 1982;23:97-103.
- 4 Stephen TC, Younoszai MK, Tyson RW, et al. Fibrosing pancreatitis associated with pericholangitis and cholangitis in a child. *J Pediatr Gastroenterol Nutr* 1992;15:208-12.
- 5 Barkin JS, Stollman N, Friedman J, et al. Idiopathic fibrosing pancreatitis causing obstructive jaundice in young adults: two case reports and literature review. *Am J Gastroenterol* 1994;89:2063-5.
- 6 Amerson JL, Ricketts RR. Idiopathic fibrosing pancreatitis: a rare cause of obstructive jaundice in children. *Am Surg* 1996;62:295-9.
- 7 Silver MM, Hellmann J, Zielenska M, et al. Anemia, blueberry-muffin rash, and hepatomegaly in a newborn infant. *J Pediatr* 1996;128:579-86.
- 8 Goldberg DM, Durie PR. Biochemical tests in the diagnosis of chronic pancreatitis and in the evaluation of pancreatic insufficiency. *Clin Biochem* 1993;26:253-75.
- 9 Knowles MR, Paradiso AM, Boucher RC. In vivo nasal potential difference: techniques and protocols for assessing efficacy of gene transfer in cystic fibrosis. *Hum Gene Ther* 1995;6:445-55.
- 10 Riedel. Uber Entzündliche der Rückbildung fähige vergrößerung des Pankreaskopfes. *Berl Klin Wochenschr* 1896;33:32.
- 11 Weinstein BR, Korn RJ, Zimmerman HJ. Obstructive jaundice as a complication of pancreatitis. *Ann Intern Med* 1963;58:245.
- 12 Scott J, Summerfield JA, Elias E, et al. Chronic pancreatitis: a cause of cholestasis. *Gut* 1977;18:196-201.
- 13 Yadeger J, Williams RA, Passaro E, et al. Common duct stricture from chronic pancreatitis. *Arch Surg* 1980;115:582-6.
- 14 Lygidakis NJ. Biliary stricture as a complication of chronic relapsing pancreatitis. *Am J Surg* 1983;145:804-6.
- 15 Wilson C, Auld CD, Schlinkert R, et al. Hepatobiliary complications in chronic pancreatitis. *Gut* 1989;30:520-7.
- 16 Deviere J, Cremer M, Baize M, et al. Management of common bile duct stricture caused by chronic pancreatitis with metal mesh self expandable stents. *Gut* 1994;35:122-6.
- 17 Lilly JR, Stellin GP, Karrer FM. Forme fruste choledochal cyst. *J Pediatr Surg* 1985;20:449-51.
- 18 Wood WJ, Trump DS. Pancreatobiliary common channel associated with common duct stricture. *J Pediatr Surg* 1986;21:738-40.
- 19 Raffensperger JG, Given GZ, Warner RA. Fusiform dilatation of the common bile duct with pancreatitis. *J Pediatr Surg* 1973;8:907-10.
- 20 Forbes A, Leung JWC, Cotton PB. Relapsing acute and chronic pancreatitis. *Arch Dis Child* 1984;59:927-34.
- 21 Foutch PG, Ferguson DR. Duodenal Crohn's disease complicated by common bile duct obstruction: report of a case and review of the literature. *Am J Gastroenterol* 1984;79:520-4.
- 22 Mohandas KM, Swaroop VS, Desai DC, et al. Pancreatic and biliary obstruction due to eosinophilic gastroenteritis. *Pediatrics* 1990;85:1540-1.
- 23 Shwachman H, Lebenthal E, Khaw KT. Recurrent acute pancreatitis in patients with cystic fibrosis with normal pancreatic enzymes. *Pediatrics* 1975;55:86-95.
- 24 Vitullo BB, Rochon L, Seemayer TA, et al. Intrapancreatic compression of the common bile duct in cystic fibrosis. *J Pediatr* 1978;93:1060.
- 25 Patrick MK, Howman-Giles R, De Silva M, et al. Common bile duct obstruction causing right upper abdominal pain in cystic fibrosis. *J Pediatr* 1986;108:101-2.
- 26 Lambert JR, Cole M, Crozier DN, et al. Intrapancreatic common bile duct compression causing jaundice in an adult with cystic fibrosis. *Gastroenterology* 1981;80:169-72.
- 27 Weizman Z, Durie PR. Acute pancreatitis in childhood. *J Pediatr* 1988;113:24-9.
- 28 Emlen W, O'Neill L. Clinical significance of antinuclear antibodies: comparison of detection with immunofluorescence and enzyme-linked immunosorbent assays. *Arthritis Rheum* 1997;40:1612-8.
- 29 Bartels RH, van der Spek JA, Oosten HR. Acute pancreatitis due to sulfamethoxazole-trimethoprim. *South Med J* 1992;85:1006-7.
- 30 Hollinshead WH. Lower part of the common bile duct: a review. *Surg Clin North Am* 1957;37:939.
- 31 Kendall RS, Chapoy PR, Busuttill RW, et al. Acquired bile duct stricture in childhood related to blunt trauma. *Am J Dis Child* 1980;134:851-4.
- 32 Jordan SC, Ament ME. Pancreatitis in children and adolescents. *J Pediatr* 1977;91:211.
- 33 Elitsur Y, Siddiqui SY, Sloven D, et al. Chronic pancreatitis with diffuse fibrosis in early childhood. *Pancreas* 1989;4:504-10.
- 34 Atkinson GO, Wyly JB, Gay BB, et al. Idiopathic fibrosing pancreatitis: a cause of obstructive jaundice in childhood. *Pediatr Radiol* 1988;18:28-31.
- 35 Ghishan FK, Greene HL, Avant G, et al. Chronic relapsing pancreatitis in childhood. *J Pediatr* 1983;102:514-18.
- 36 Konzen KM, Perrault J, Moir C, et al. Long-term follow-up of young patients with chronic hereditary or idiopathic pancreatitis. *Mayo Clin Proc* 1993;68:449-53.