

# PostScript

## LETTERS

If you have a burning desire to respond to a paper published in *Gut*, why not make use of our "rapid response" option?

Log onto our website ([www.gutjnl.com](http://www.gutjnl.com)), find the paper that interests you, and send your response via email by clicking on the "eletters" option in the box at the top right hand corner.

Providing it isn't libellous or obscene, it will be posted within seven days. You can retrieve it by clicking on "read eletters" on our homepage.

The editors will decide as before whether to also publish it in a future paper issue.

### Role of multi-detector row CT angiography in the management of gastric fundal varices

We read with great interest the article by Willmann *et al* (*Gut* 2003;52:886-92) regarding the superiority of multi-detector row CT (MDCT) angiography over endoscopic ultrasound for the detection and characterisation of submucosal gastric fundal varices (FV).

We strongly agree that MDCT angiography provides excellent visualisation of FV, as well as afferent and efferent veins, and that it provides valuable anatomical information for deciding the therapeutic strategies for FV (fig 1A, B).<sup>1,2</sup>

Iwase and colleagues<sup>3</sup> divided FV into localised and diffuse types using MDCT angiography. This classification resembles the findings obtained by investigation of resected or autopsied stomachs.<sup>4</sup> According to Iwase and colleagues,<sup>3</sup> diffuse FV are more difficult to obliterate with cyanoacrylate than localised FV. Diffuse FV may be better treated with balloon occluded retrograde transvenous obliteration (B-RTO).<sup>5</sup>

Although FV with a high risk of bleeding have not yet been fully clarified, they are defined according to the criteria proposed by

Kim and colleagues<sup>2</sup> in Japan. Because high risk FV are easily detected endoscopically, it is not necessary to distinguish FV from perigastric collateral veins by MDCT angiography.

MDCT angiography can also provide useful information for evaluation of the effect of treatment of FV.<sup>5,6</sup> Obliteration of the afferent veins as well as the actual varices is important to prevent recurrence.<sup>5</sup> If these vessels are not visualised by MDCT angiography after therapy, FV will rarely recur.<sup>5,6</sup> With regard to the treatment of FV reported by the authors, we also have some comments. Firstly, they treated a patient by transjugular intrahepatic portosystemic shunting (see fig 2 in Willmann *et al*). However, as the patient had a type 2 portal haemodynamic pattern, as classified by Kanagawa and colleagues,<sup>7</sup> B-RTO would have been preferable if his portal pressure gradient was less than 12 mm Hg.<sup>2</sup>

Secondly, we would like to ask the authors how they treated the patient presented in fig 3? As the varices seem to be so-called GOV2, as classified by Sarin and Kumar,<sup>8</sup> they could be treated by endoscopic sclerotherapy with the oesophageal varices.

**A Matsumoto, Y Sugano, M Yasuda, K Takimoto**

Takeda General Hospital, 28-1 Ishida Morimnadi-cho, Fushimi, Kyoto, Japan

Correspondence to: Dr A Matsumoto; marsh@hkg.odn.ne.jp

### References

- 1 Chikamori F, Kuniyoshi N, Shibuya S, *et al*. Correlation between endoscopic and angiographic findings in patients with esophageal and isolated gastric varices. *Dig Surg* 2001;18:176-81.
- 2 Matsumoto A, Yamauchi H, Inokuchi H. Balloon-occluded retrograde transvenous obliteration: a feasible alternative to transjugular intrahepatic portosystemic shunt. *Gut* 2003;52:611-12.
- 3 Iwase H, Maeda O, Shimada M, *et al*. Endoscopic ablation with cyanoacrylate glue for isolated gastric variceal bleeding. *Gastrointest Endosc* 2001;53:585-92.

- 4 Arakawa M, Masuzaki T, Okuda K. Pathology of fundic varices of the stomach and rupture. *J Gastroenterol Hepatol* 2002;17:1064-9.
- 5 Matsumoto A, Matsumoto H, Inokuchi H. Role of cyanoacrylate in the management of bleeding gastric varices. *Hepatology* 2002;36:1298.
- 6 Matsumoto A, Matsumoto H, Hamamoto N, *et al*. Prophylaxis of rebleeding from isolated gastric fundal varices by balloon-occluded retrograde transvenous obliteration. *Abdom Imaging* 2001;26:578-80.
- 7 Kanagawa H, Mima S, Kouyama H, *et al*. Treatment of gastric fundal varices by balloon-occluded retrograde transvenous obliteration. *J Gastroenterol Hepatol* 1996;11:51-8.
- 8 Sarin SK, Kumar A. Gastric varices: profile, classification, and management. *Am J Gastroenterol* 1989;84:1244-9.

### Authors' reply

We thank Dr Matsumoto *et al* for their interest in our work.

Balloon occluded retrograde transvenous obliteration (B-RTO) is a recently described interventional radiology technique which allows effective treatment of gastric varices, similar to but less invasive than transjugular intrahepatic portosystemic shunt (TIPSS).<sup>1</sup> It has recently been shown that B-RTO of gastric varices can even be performed through the left inferior phrenic vein which represents the efferent vein of gastric varices.<sup>2</sup> There is no doubt that B-RTO through the left inferior phrenic vein would have been an option for the treatment of the patient shown in fig 2 of our article (*Gut* 2003;52:886-92). However, since the portal venous pressure gradient in this particular patient was 28 mm Hg, we preferred to place a 10 mm diameter TIPSS in this particular patient.

The patient illustrated by fig 3 in our study (*Gut* 2003;52:886-92) was classified as having gastro-oesophageal varices type 2 (GOV-2), according to the endoscopic classification proposed by Sarin and Kumar.<sup>3</sup> This patient underwent endoscopic sclerotherapy.

**J K Willmann, D Weishaupt, T Böhm, T Pfammatter**

Institute of Diagnostic Radiology, University Hospital, Zurich, Switzerland

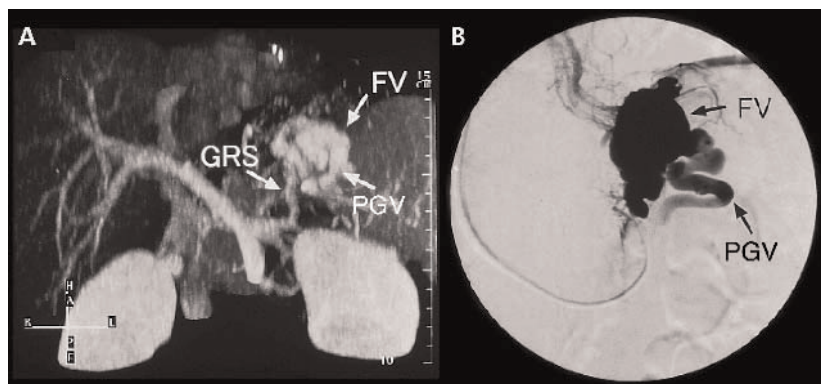
**P Bauerfeind**

Division of Gastroenterology, University Hospital, Zurich, Switzerland

Correspondence to: Dr D Weishaupt, Institute of Diagnostic Radiology, University Hospital, Rämistrasse 100, 8091 Zurich, Switzerland; dominik.weishaupt@dmr.usz.ch

### References

- 1 Kanagawa H, Mima S, Kouyama H, *et al*. Treatment of gastric varices by balloon-occluded retrograde transvenous obliteration (B-RTO). *Kanzo (Acta Hepatology Jpn)* 1991;32:442.
- 2 Ibukuro K, Mori K, Tsukiya T, *et al*. Balloon-occluded retrograde transvenous obliteration of gastric varix draining via the left inferior phrenic vein into the left hepatic vein. *Cardiovasc Intervent Radiol* 1999;22:415-32.
- 3 Sarin SK, Kumar A. Gastric varices: profile, classification, and management. *Am J Gastroenterol* 1989;84:1244-9.



**Figure 1** (A) Multi-detector row CT (MDCT) angiograms before treatment for submucosal gastric fundal varices. (B) Balloon occluded retrograde transcatheter varicealogram during balloon occluded retrograde transvenous obliteration, which agrees with the MDCT angiogram. PGV, posterior gastric vein; FV, submucosal gastric fundal varices; GRS, gastrorenal shunt.

## Primary antiphospholipid syndrome as a new cause of autoimmune pancreatitis

I read with interest the article by Kamisawa *et al* regarding the aetiology of autoimmune pancreatitis (*Gut* 2003;52:683–7). The cause of a significant proportion of cases of acute pancreatitis remains uncertain. I would like to describe a case of acute pancreatitis associated with antiphospholipid syndrome to highlight another potentially important cause of autoimmune pancreatitis which I believe has not been previously described.

### Case report

A 30 year old woman was admitted twice in the space of three months with acute pancreatitis. She had a past medical history of anxiety and occasional migraines, for which she took alprazolam and propranolol, respectively. She had suffered two miscarriages and had one healthy child. She drank 3 units of alcohol per day. She was otherwise well and had no history of musculoskeletal problems.

On both occasions her amylase level was significantly elevated (787 and 364, respectively (normal range 30–154)). Ultrasound and computed tomography of her abdomen were carried out each time and demonstrated a diffusely swollen pancreas consistent with acute pancreatitis, but with no evidence of gall stones or biliary duct dilatation.

Liver function tests were all normal with the exception of a slightly elevated gamma glutamyl transferase level. Glucose, lipids, thyroid stimulating hormone, calcium, and clotting (international normalised ratio and activated partial thromboplastin time) were all normal. Full blood count was normal except for a neutrophilia during her acute illness. Her erythrocyte sedimentation rate was raised at 78. Urine microscopy and urinary protein excretion were both normal.

On her second admission to hospital she had four generalised seizures and magnetic resonance imaging showed cortical vein thrombosis with associated venous infarction. Subsequent investigation revealed a strongly positive antinuclear antibody (1 in 640) but her extractable nuclear antigens and dsDNA were negative, as was her anti-neutrophil cytoplasmic autoantibodies and her antimitochondrial and antismooth muscle antibodies. Her thrombophilia screen was negative but her IgG anticardiolipin antibodies were positive at 22.3 (0–5.5).

A diagnosis of antiphospholipid syndrome was made. She was treated with heparin and warfarin and subsequently made a good recovery.

### Discussion

Primary antiphospholipid syndrome is defined as the presence of antiphospholipid antibodies (lupus anticoagulant or anticardiolipin antibodies) in association with thrombosis or recurrent miscarriage, but in the absence of an associated connective tissue disorder such as systemic lupus erythematosus (SLE).<sup>1</sup>

SLE has previously been described as an unusual cause of acute autoimmune pancreatitis. In the literature there are a small number of cases of pancreatitis in association with SLE and antiphospholipid syndrome.<sup>2,3</sup> A single case of pancreatitis associated with lupus anticoagulant but without

anticardiolipin antibodies has also been described.<sup>4</sup> However, to my knowledge this is the first reported case of primary antiphospholipid syndrome associated with anticardiolipin antibodies causing acute pancreatitis.

In the antiphospholipid syndrome, vascular occlusion is due to thromboembolism whereas in SLE the primary abnormality is vasculitis. In a single post mortem case of pancreatitis due to antiphospholipid syndrome associated with SLE, the pathological abnormality was vascular occlusion due to thromboembolism.<sup>1</sup> Oral anticoagulation rather than steroids is therefore the treatment of choice for antiphospholipid syndrome.<sup>5</sup>

The patient described fulfils the criteria for a diagnosis of primary antiphospholipid syndrome. While there is no histological proof that her pancreatitis was due to vaso-occlusive thromboembolism, several facts make this the likely explanation. The recurrent episodes in the absence of another cause, the proven cerebral thromboembolism at the time of her second attack of pancreatitis, and her positive anticardiolipin antibodies are highly suggestive that thromboembolism of her pancreatic blood vessels was indeed the cause of her pancreatitis.

I suggest that the investigation of patients with idiopathic pancreatitis should include checking their antiphospholipid antibodies.

H L Spencer

Correspondence to: Dr H L Spencer, Sheffield Teaching Hospitals, Herries Rd, Sheffield, UK; happyhal@cheerful.com

### References

- 1 Wilson WA, Ghavari AE, Koike T, *et al*. International consensus statement on preliminary classification criteria for definite antiphospholipid syndrome. *Arthritis Rheum* 1999;42:1309–11.
- 2 Wang CR, Hsieh HC, Lee GL, *et al*. Pancreatitis associated to antiphospholipid antibody syndrome in patient with systemic lupus erythematosus. *J Rheumatol* 1992;19:1123–5.
- 3 Yeh TS, Wang CR, Lee YT, *et al*. Acute pancreatitis related to anticardiolipin antibodies in lupus patients visiting an emergency department. *Am J Emerg Med* 1993;11:230–2.
- 4 Gaspari JC, Sande JR, Thomas CF jr, *et al*. Lupus anticoagulant masquerading as an acute abdomen with multiorgan involvement. *Am J Gastroenterol* 1995;90:825–6.
- 5 Khamashta MA, Cuadrado MJ, Mujic F, *et al*. The management of thrombosis in the antiphospholipid-antibody syndrome. *N Engl J Med* 1995;332:993–7.

### Author's reply

Autoimmune pancreatitis is a recently described clinical entity in which autoimmune mechanisms are involved in the pathogenesis. As Etemad and colleagues<sup>1</sup> described that autoimmunity was one of six risk factors of chronic pancreatitis, autoimmune pancreatitis is not acute but chronic pancreatitis. Patients with autoimmune pancreatitis rarely showed acute attacks of pancreatitis or marked elevation of serum amylase.<sup>2</sup> Although the pancreas of autoimmune pancreatitis is swollen similar to acute pancreatitis on ultrasound and computed tomography, it is induced by dense lymphoplasmacytic infiltration with fibrosis.

Obliterated phlebitis throughout the pancreas is one of the characteristic pathological

findings of autoimmune pancreatitis. The lumen of the vein was filled with prominent cellular infiltrates and fibrosis. Venous occlusion was not due to thromboembolism but to phlebitis. Although the role of obliterated phlebitis is unknown in the pathogenesis of autoimmune pancreatitis, many IgG4 positive plasma cells, which might be closely related to pathogenesis, were observed in the obliterated veins. Signs of thrombosis were not observed in any organs of our patients with autoimmune pancreatitis. We think that autoimmune pancreatitis is quite different from the pancreatitis reported by Spencer.

T Kamisawa, N Funata, A Okamoto

Correspondence to: T Kamisawa, Department of Internal Medicine, Tokyo Metropolitan Komagome Hospital, 3-18-22 Honkomagome, Bunkyo-ku, Tokyo 113-8677, Japan; kamisawa-k@komagome-hospital.bunkyo.tokyo.jp

### References

- 1 Etemad B, Whitcomb DC. Chronic pancreatitis: diagnosis, classification, and new genetic developments. *Gastroenterology* 2001;120:682–707.
- 2 Yoshida K, Toki F, Takeuchi T, *et al*. Chronic pancreatitis caused by an autoimmune abnormality. Proposal of the concept of autoimmune pancreatitis. *Dig Dis Sci* 1995;40:1561–8.

## Treatment of interferon non-responsive chronic hepatitis C with triple therapy with interferon, ribavirin, and amantidine can be encouraging

Patients with hepatitis C virus infection who do not respond to treatment with interferon alone or its combination with ribavirin present a serious clinical challenge and there is no clear choice for treatment in these individuals.<sup>1,2</sup> Earlier studies with antiviral amantidine, which has been used in influenza, had shown promising results.<sup>3</sup> Now, Adinolfi *et al* (*Gut* 2003;52:701–5) have shown 68% end of treatment response with induction therapy using daily interferon for four weeks (and then three injections weekly) in combination with ribavirin and amantidine hydrochloride.

We had used interferon in doses of 3 million units given subcutaneously thrice weekly with ribavirin 800–1200 mg/day and amantidine hydrochloride 100 mg orally twice a day in a small group of chronic hepatitis C patients who had not responded to a combination of interferon and ribavirin. We found a 50% end of treatment response after a treatment period of 12 months (see table 1). Half of the patients showed no effect on alanine aminotransferase or hepatitis C virus RNA, and in these patients treatment was discontinued after three months.

There are reports of good results with the use of amantidine in combination with interferon.<sup>4</sup> Therefore, although the mechanism of action of amantidine in this setting is unclear, it is becoming obvious that there is an encouraging situation for these hard to treat patients and there may be light at the end of the tunnel. Due to lack of major sponsorship for amantidine from a large

**Table 1** Patients treated with interferon, ribavirin, and amantidine

No	Age (y)	Sex	Duration of treatment (months)	HCV RNA level (millions)	HCV serotype	Biopsy grade/stage	End of treatment response
1	42	M	12		3	2/3	Clear*
2	50	F	3	3.0	Untypable	3/4	No response
3	50	M	12			2/1	Clear
4	52	F	3	6.9	3	2/2	No response
5	61	F	3			1/0	No response
6	37	M	12	6.1	3	1/3	Clear
7	36	M	12	2.4	3	1/2	Clear
8	50	F	3	0.2	Untypable	2/2	No response
9	42	M	12	0.48	3	1/1	Clear
10	51	M	3	5.9	3	2/1	No response

\*Normal alanine aminotransferase and undetectable hepatitis C virus (HCV) RNA.

pharmaceutical company however, it may take a while before this happens.

**N Khokhar**

Correspondence to: Professor N Khokhar, Division of Gastroenterology, Department of Medicine, Shifa International Hospital and Shifa College of Medicine, Islamabad, Pakistan; drmkhokhar@yahoo.com

## References

- 1 Lauer GM, Walker BD. Hepatitis C virus infection. *N Engl J Med* 2001;**345**:41–52.
- 2 NIH. Consensus Development Conference Statement: management of hepatitis C: 2002. *Hepatology* 2002;**36**(suppl 1):S3–20.
- 3 Brilliant S, Levantesi F, Masi L, et al. Triple antiviral therapy as a new option for patients with interferon non-responsive chronic hepatitis C. *Hepatology* 2000;**32**:630–4.
- 4 Nakamura H, Uyama H, Enomoto H, et al. The combination therapy of interferon and amantidine hydrochloride for patients with chronic hepatitis C. *Hepatogastroenterology* 2003;**50**:222–6.

## Who should perform endoscopic procedures?

We read with great interest the report of Smale *et al* on upper gastrointestinal endoscopy performed by nurses (*Gut* 2003;**52**:1090–4). This work shows a limited experience with specific endoscopy trained nurses that had no significant effect on diagnostic yield, patient discomfort, or patient satisfaction compared with medical staff. Many experiences, some of them mentioned in this report, have shown that nurses can successfully perform endoscopic procedures.

Of course, nurses require a training programme, similar to the one usually offered to our residents and trainees. We are certain that specifically trained nurses could also perform liver biopsies, abdominal ultrasound examinations, diagnostic laparoscopy, and some surgical procedures, such as appendectomy or elective cholecystectomy. Any manual (surgical or endoscopic) procedure may be learnt by anyone, medical or non-medical, in common with many other forms of manual labour or craftsmanship. Frequently, and not so long ago, GPs performed some surgical procedures, such as caesarean section and appendectomy, and barbers once performed surgery. This could be the first step towards a new perspective for medical practice in which nurses might attend our gastroenterology wards and clinics in some circumstances.

We have no doubt about the accuracy and seriousness of this report but, as the authors explain in the introduction, the main

motivation for the study was economic. Public health systems, such as the British and Spanish systems, have a great deal of sanitary costs. In our day to day clinical practice, many strategies are tried with the aim of reducing costs. But some frequently overlooked ethical, scientific, and philosophical questions are implied. Nowadays, there are more restrictive conditions to teaching endoscopy to young gastroenterologists.<sup>1</sup> Ethical and legal concerns make resident training more expensive and difficult, as our developed societies are increasingly demanding of healthcare quality and safety.<sup>2</sup> Hence should we begin teaching endoscopy to non-medical staff? We do not believe so. We also believe that one essential function of medical practice is to provide investigation (an always limited field in terms of funds and time) in public hospitals' busy endoscopy wards. Then, should nurses have a specific training in investigation? The excellent work of Smale *et al* raises many other simple questions: (1) When to stop? (2) The main goal of this work was to have cheaper endoscopists, so why not try to minimise costs by teaching nurses other physician tasks, such as physical examination or minor surgical procedures? (3) Should we begin training nurses instead of our residents in our endoscopy wards? (4) Why not begin to teach nurses other endoscopic procedures, such as endoscopic retrograde cholangiopancreatography or endoscopic ultrasound and, in this event, what is the future role for physicians?

In summary, we believe our efforts should be directed towards better clinical practice, defining indications for different medical procedures, limiting costs in the many other aspects of endoscopy and gastroenterology, and trying to perform our specific role, nurse or medical, as scientifically based and accurate as possible.

**E Redondo-Cerezo, J García-Cano**

Digestive Service, Unidad de Endoscopias, Hospital General Virgen de la Luz, Cuenca, Spain

Correspondence to: Dr E Redondo-Cerezo, Servicio de Aparato Digestivo, Hospital General Virgen de la Luz, C/Hermanidad de Donantes de Sangre 1 Cuenca 16002, Spain; eredondoc@yahoo.es

## References

- 1 American Association of Gastrointestinal Endoscopy. Principles of training in gastrointestinal endoscopy. *Gastrointest Endosc* 1999;**49**:845–53.
- 2 Axon AT, Aabakken L, Malfentheiner P, et al. Recommendations of the EGSE workshop on ethics in teaching and learning endoscopy. *Endoscopy* 2003;**35**:761–4.

## The diagnostic dilemmas in discrimination between pancreatic carcinoma and chronic pancreatitis

Early diagnosis to distinguish between malignant pancreatic tumours and chronic pancreatitis is still difficult, despite significant progress in imaging techniques. Moreover, patients with chronic pancreatitis have a higher risk of pancreatic cancer development.

The study of Malka *et al* (*Gut* 2002;**51**:849–52) clearly confirms these difficulties, independently of rigorous selection criteria of patients with chronic pancreatitis. To exclude the possibility that chronic pancreatitis may be caused by early potentially premalignant lesions, the authors eliminated from their investigations even patients with chronic pancreatitis in whom pancreatic cancer was recognized during the first two years of follow up.

Several studies indicate the value of circulating tumour marker evaluation as a simple, sensitive, and reliable test facilitating the differential diagnosis between chronic pancreatitis and cancer.<sup>1–7</sup> To improve the effectiveness of serological diagnosis of patients with pancreatic carcinoma, different tumour markers have been assessed, including CEA, CA 242, CA 50, and CA 72-4.<sup>1–4,7</sup> However, the sensitivity and specificity of these markers appeared to be insufficient for differentiation of pancreatic carcinoma from chronic pancreatitis. In 1996, CAM 17-1<sup>5</sup> was described as a new useful diagnostic marker in pancreatic carcinoma. It showed a sensitivity similar to that of CA 19-9 but higher specificity, giving only 10% false positive results in patients with chronic pancreatitis.

Tissue polypeptide specific antigen (TPS) is a different type of antigen that does not correlate with tumour mass but reflects tumour proliferative activity.<sup>8</sup> Our study<sup>6</sup> revealed that elevated levels of TPS detected preoperatively 100% of patients with pancreatic carcinoma. The introduction of 200 U/l as a decision criterion for TPS level allowed an increase in the specificity of this marker to 98% and eliminated all but 2% of the false positive results in patients with chronic pancreatitis. Moreover, TPS is useful for detection of the early stages of clinical advancement of pancreatic carcinoma.

It seems that measurement of TPS, using 200 U/l as the cut off value, should facilitate more precise discrimination between the early stages of pancreatic carcinoma and chronic pancreatitis.

**A Harlozinska-Szmyrka, M Strutynska-Karpinska**

Department of Clinical Immunology, Wrocław Medical University, Mikuliczka-Radeckiego, Street 7, Wrocław 50-368, Poland

Correspondence to: Professor A Harlozinska-Szmyrka; immuno@immuno.am.wroc.pl

## References

- 1 Banfi G, Zerbi A, Pastori S, et al. Behavior of tumor markers CA 19-9, CA 195, CAM 43, CA 242 and TPS in diagnosis and follow-up of pancreatic cancer. *Clin Chem* 1993;**39**:420–3.
- 2 Ventrucci M, Ubalducci GM, Cipolla A, et al. Serum CA 242: the search for a valid marker of pancreatic cancer. *Clin Chem Lab Med* 1998;**36**:179–84.



- 3 Kawa S, Tokoo M, Hasebe O, *et al*. Comparative study of CA 242 and CA 19-9 for the diagnosis of pancreatic cancer. *Br J Cancer* 1994;**70**:481–6.
- 4 Sperti C, Pasquali C, Guolo P, *et al*. Serum tumor markers and cyst fluid analysis are useful for the diagnosis of pancreatic cystic tumors. *Cancer* 1996;**78**:237–43.
- 5 Gansauge F, Gansauge S, Parker N, *et al*. CAM 17-1—A new diagnostic marker in pancreatic cancer. *Br J Cancer* 1996;**74**:1997–2002.
- 6 Slesak B, Harlozinska-Szymrka A, Knast W, *et al*. Tissue polypeptide specific antigen (TPS), a marker for differentiation between pancreatic carcinoma and chronic pancreatitis. A comparative study with CA 19-9. *Cancer* 2000;**89**:83–8.
- 7 Pasanen PA, Eskelinen M, Partanen K, *et al*. Diagnostic value of tissue polypeptide specific antigen in patients with pancreatic carcinoma. *Tumor Biol* 1994;**15**:52–60.
- 8 Rydlander L, Ziegler E, Bergman T, *et al*. Molecular characterization of a tissue-polypeptide-specific-antigen epitope and its relationship to human cytokeratin 18. *Eur J Biochem* 1996;**241**:309–14.

### Small bowel malignancy in coeliac disease

We were interested to read the case report by Rampertab *et al* on small bowel neoplasia in coeliac disease (*Gut* 2003;**52**:1211–14). The findings are very much in accord with ours from the British Society of Gastroenterology (BSG) National UK Survey published earlier this year.<sup>1</sup> Over a two year period (1998–2000), we collected details of 175 cases of primary small intestinal adenocarcinoma, of which 13% were associated with coeliac disease and another 7% with Crohn's disease. With regard to coeliac associated adenocarcinomas, similar to Rampertab *et al*, we found a predominance of males (2:1) and an equal distribution between the duodenum and jejunum. Age range was 47–80 years. Fifty five per cent presented acutely, predominantly with obstruction, and 45% chronically with anaemia, weight loss, or abdominal pain. Mean time of symptoms prior to diagnosis was 14 months, which was reflected in a relatively poor 30 month overall survival of 58%. In 63%, coeliac disease had been diagnosed a mean of 8.2 years prior to the diagnosis of adenocarcinoma; in almost all of these patients there had been a good clinical and mucosal response to a gluten free diet. In 37%, coeliac disease was diagnosed at the same time as adenocarcinoma.

Although 13% of small bowel adenocarcinomas being associated with coeliac disease implies that the risk of these cancers in coeliac disease is very high, such an increase translates into a very small absolute life time risk of less than 1%, as these tumours are rare and coeliac disease is very common. Nevertheless, we agree that coeliac patients require long term follow up for this and other complications. However, the best means of surveillance needs to be determined.

Of most concern is the long delay in the diagnosis of small bowel adenocarcinoma, irrespective of whether or not coeliac disease is present. This leads to poor survival as 40% have metastasised by the time the diagnosis is made. A high index of suspicion is required by all gastroenterologists for this rare, but eminently treatable, type of adenocarcinoma.

P D Howdle, G K T Holmes

Department of Medicine, Clinical Sciences Building, University of Leeds, Leeds LS9 7TF, UK

Correspondence to: Professor P D Howdle; p.d.howdle@leeds.ac.uk

### Reference

- 1 Howdle PD, Jalal PK, Holmes GKT, *et al*. Primary small bowel malignancy in the UK and its association with coeliac disease. *Q J Med* 2003;**96**:345–53.

### Submucosal "dissection" in collagenous colitis

We were fascinated to read the paper by Cruz-Correa *et al* (*Gut* 2002;**51**:600) describing cases of mucosal tearing at colonoscopy in patients subsequently found to have collagenous colitis. We were particularly interested in their postulated mechanism for these tears being a disruption of colonic mural integrity by the submucosal collagen layer. We would like to present two cases which add further weight to this theory as well as possibly providing information as to the pathogenesis of diarrhoea in this condition.

A 60 year old woman presented to her general practitioner with a two month history of profuse watery diarrhoea. A barium enema examination was reported as showing evidence of a mild colitis only. The general practitioner commenced corticosteroids resulting in complete resolution of her symptoms. On referral to our department, a gastrointestinal radiologist reviewed her radiographs. It was noticed that throughout the films there was a radiolucent border outlining the colonic mucosa (see fig 1) suggesting the presence of a submucosal layer of gas for which no explanation could be found. Although endoscopic examination of the colon was macroscopically normal, serial biopsies revealed the presence of a subepithelial collagen band up to 100 µm thick and a diagnosis of collagenous colitis was made. There was no evidence of pneumatosis or of submucosal barium on the small amount of submucosa included. She has since remained well on mesalazine.

The second patient was a 68 year old woman with a four week history of profuse watery diarrhoea. An emergency admission was required as a result of deranged clotting secondary to warfarin, which she was taking for a mechanical aortic valve. Following correction of her coagulopathy she underwent a colonoscopy. The instrument was advanced to the caecum without difficulty by a very experienced endoscopist who had performed in excess of 10 000 procedures. Macroscopically, there was evidence of a mild

colitis. Standard serial biopsies were taken. Shortly following the procedure she complained of right shoulder tip pain. On examination she was neither distressed nor haemodynamically compromised. Her abdomen was soft. Chest and abdominal radiographs showed significant free gas under the diaphragm and in the peritoneum. At laparotomy she was found to have pneumoperitoneum without faecal contamination. No perforation was identified but there was considerable emphysema within the caecal wall extending proximally along the terminal ileum and distally to the mid ascending colon. No further operative procedure was performed. Endoscopic biopsies showed mild active inflammation and a subepithelial collagen band. None of the biopsies was full thickness. A diagnosis of collagenous colitis was made and her symptoms settled on a short course of corticosteroids.

We suggest that the complications seen in the investigation of these two patients result from a weakness within the colonic wall caused by the collagen layer. In the first case it appears that cleavage or dissection of the colonic wall alongside the collagen layer may have occurred. It is unclear whether this happened as a result of air insufflation at the time of examination or whether it was already present. In the second case we postulate that air insufflated at the time of the colonoscopy tracked alongside the collagen layer perforating into the peritoneum remote from its original point of entry; possibly a proximal biopsy site.

If a true weakness in the integrity of adhesion of the elements of the colonic wall does exist and such "dissection" can happen spontaneously, then it may provide some insight into the pathogenesis of the diarrhoea in this condition, especially as there appears to be no correlation between the width of the collagen band and the severity of symptoms.

J D Mitchell, R Teague, R Bolton, J Lowes  
Torbay Hospital, Bessmer Rd, London SE5 9RS, UK

Correspondence to: J D Mitchell; jonmitch@clara.net

### Responses to endothelin-1 in patients with advanced cirrhosis before and after liver transplantation

I read with interest the article of Vaughan *et al* (*Gut* 2003;**52**:1505–10) and was pleased to

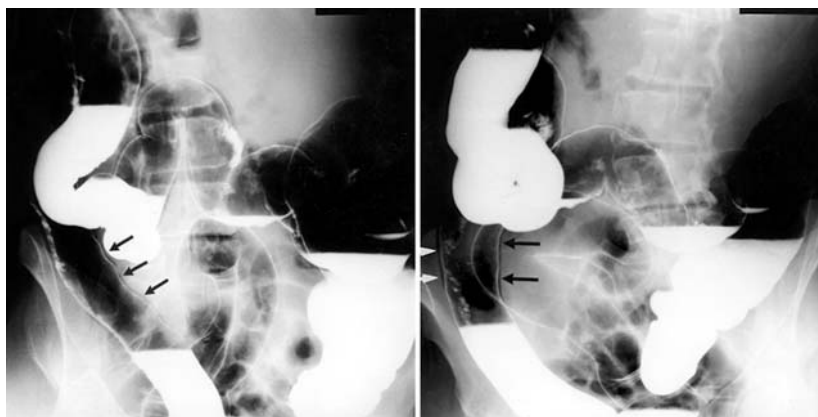


Figure 1 Erect radiographs from a double contrast barium enema series. Submucosal tracking of gas is arrowed.

see my novel studies<sup>1,2</sup> partially reproduced in patients with decompensated cirrhosis. I disagree with some of the results as the study involves substantial design, methodology, and analysis problems.

The authors said that advanced cirrhotic patients have "generalised vasodilatation". Vasodilatation does occur in these patients but only in the splanchnic and pulmonary beds.<sup>3</sup> Indeed, studies by me and others have shown vasoconstriction in the brachial, femoral, cerebral, and renal territories, especially in advanced cirrhosis.<sup>4-6</sup> Therefore, I would like to stress the point that with advancing cirrhosis, further activation of the neurohumoral systems occurs, with consequent peripheral vasoconstriction. However, blood pooling, particularly in the splanchnic bed, lowers systemic vascular resistance.

A major criticism of the study of Vaughan *et al* is that they measured forearm blood flow (FBF) in only one arm. Changing levels of alertness and external stimuli produce similar fluctuations in blood flow of both arms, and lead to significant misleading alterations in the measured responses if unilateral measurements are used. Thus responses to intra-arterial infusions should have been measured in both arms with the results expressed as ratios of concurrent FBF in the infused and non-infused arms, where the latter serves as a contemporaneous control for the drug effects in the former.<sup>7-9</sup> Furthermore, FBF ratios are significantly more reproducible than unilateral FBF measurements both at rest and following infusion of vasoconstrictors.<sup>9</sup>

The authors demonstrated a surprising increase in FBF (~35–40%) in response to infusion of a locally active dose of the potent vasoconstrictor endothelin-1 (ET-1), which reached its maximum within five minutes from the start. They attributed their finding to enhanced ET<sub>B</sub> receptor mediated vasodilatation. This needs to be tested by selectively blocking ET<sub>B</sub> receptors, using BQ-788. To date, upregulation of ET<sub>B</sub> receptors has been reported in the splanchnic and pulmonary vasculature but not in the forearm.<sup>10,11</sup> How can the maximum response to the slowly acting ET-1 be reached within five minutes? Also, dose-response curves of the effects of ET-1 and BQ-123 should have been performed.

According to the authors, ET<sub>A</sub> receptor mediated responses were unaltered while those mediated by the ET<sub>B</sub> receptor were enhanced in patients with decompensated cirrhosis. Thus one would expect that blocking ET<sub>A</sub> receptors with BQ-123 would allow ET-1 to act unopposed on ET<sub>B</sub> receptors and produce enhanced vasodilatation. However, this was not the case (fig 2 in the article). What adds to my surprise here is that BQ-123 infusion also increased FBF by ~35–40%. How can infusion of ET-1 produce the same per cent change in FBF as infusion of its selective ET<sub>A</sub> receptor antagonists?!

Many of the included patients were receiving diuretics,  $\beta$ -blockers, and immunosuppressive medications, which were withheld only on the day of testing. These medications affect circulating volume, vascular tone, and the activity of the neurohumoral systems. To eliminate these effects, drugs need to be stopped for at least five times their half life. Alternatively, control subjects on the same medications should be used (for example, renal transplant recipients with a normal liver).

Vaughan *et al* reported normal plasma ET-1 concentrations in decompensated cirrhosis, without measuring preproendothelin-1 mRNA

or big ET-1, the biological precursor of ET-1. Due to its autocrine, paracrine, and endocrine nature, plasma concentrations of ET-1 alone do not reflect the activity of the endothelin system or the status of ET-1 production.<sup>12</sup> This should have been stated by the authors. I also recommend collecting samples in tubes containing 1000 KIU aprotinin and EDTA.

In conclusion, the scientific contents of this article would have been greater if the authors had: (1) measured FBF in both arms; (2) presented their data as per cent change in the ratio of flows in both arms at every time point; (3) assessed plasma big ET-1 or preproendothelin mRNA concentrations; (4) examined the responses to an ET<sub>B</sub> receptor antagonist; (5) performed a dose-response curve; and (6) selected a comparable control group on similar medications as the patients.

A Helmy

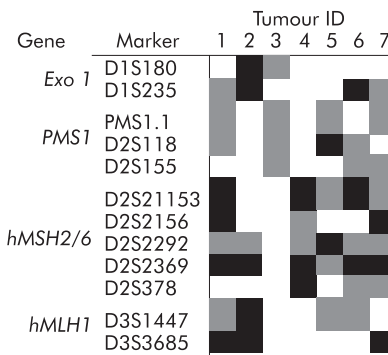
Correspondence to: Dr A Helmy, Gastroenterology and Tropical Medicine Department, 6th Floor, Assiut University Hospital, Assiut 71111, Egypt; ahsalem10@hotmail.com

## References

- 1 Helmy A, Newby DE, Jalan R, *et al*. Enhanced vasodilatation to endothelin antagonism in patients with compensated cirrhosis and the role of nitric oxide. *Gut* 2003;**52**:410–15.
- 2 Helmy A, Jalan R, Newby DE, *et al*. Altered peripheral vascular responses to exogenous and endogenous endothelin-1 in patients with well-compensated cirrhosis. *Hepatology* 2001;**33**:826–31.
- 3 Newby DE, Hayes PC. Hyperdynamic circulation in liver cirrhosis: not peripheral vasodilatation but 'splanchnic steal'. *Q J Med* 2002;**95**:827–30.
- 4 Helmy A, Jalan R, Newby DE, *et al*. Role of angiotensin II in regulation of basal and sympathetically stimulated vascular tone in early and advanced cirrhosis. *Gastroenterology* 2000;**118**:565–72.
- 5 Fernandez-Seara J, Prieto J, Quiroga J, *et al*. Systemic and regional hemodynamics in patients with liver cirrhosis and ascites with and without renal failure. *Gastroenterology* 1989;**97**:1304–12.
- 6 Maroto A, Gines P, Arroyo V, *et al*. Brachial and femoral artery blood flow in cirrhosis: relationship to kidney dysfunction. *Hepatology* 1993;**17**:788–93.
- 7 Benjamin N, Calver A, Collier J, *et al*. Measuring forearm blood flow and interpreting the responses to drugs and mediators. *Hypertension* 1995;**25**:918–23.
- 8 Webb DJ. The pharmacology of human blood vessels in vivo. *J Vasc Res* 1995;**32**:2–15.
- 9 Petrie JR, Ueda S, Morris AD, *et al*. How reproducible is bilateral forearm plethysmography? *Br J Pharmacol* 1998;**45**:131–9.
- 10 Cahill PA, Hou MC, Hendrickson R, *et al*. Increased expression of endothelin receptors in the vasculature of portal hypertensive rats: role in splanchnic hemodynamics. *Hepatology* 1998;**28**:396–403.
- 11 Fallon MB, Abrams GA. Pulmonary dysfunction in chronic liver disease. *Hepatology* 2000;**32**:859–65.
- 12 Frelin C, Guedin D. Why are circulating concentrations of endothelin-1 so low? *Cardiovasc Res* 1994;**28**:1613–22.

## Germline testing of mismatch repair genes is not aided by prescreening tumours for allelic loss

Immunostaining and microsatellite testing of tumours is increasingly being used to guide



**Figure 1** Loss of heterozygosity analysis of four mismatch repair genes tumours from seven individuals with germline mutations in *hMSH2*. White areas, retention of heterozygosity; grey areas, not informative; black areas, loss of heterozygosity.

germline testing in individuals with suspected hereditary non-polyposis colorectal cancer (HNPCC).<sup>1</sup> While the aim of these prescreening tests is to minimise the cost and maximise the chance of identifying a pathogenic germline change, it is clear that neither alone is ideal. In clinical practice, germline testing can often only be justified where an individual has developed a tumour which is microsatellite unstable, and which fails to express a mismatch repair protein. Clearly, this approach is imperfect as not all pathogenic germline mutations are associated with failure of expression of the mismatch repair proteins. The aim of this pilot study was to retrospectively assess the utility of loss of heterozygosity studies in predicting the mutated mismatch repair gene.

Seven individuals with germline mutations in *hMSH2* were identified from the family cancer clinic at St Vincent's Hospital, Sydney. The tumours from each of these individuals were microsatellite unstable and failed to express *hMSH2*, but demonstrated normal expression of *hMLH1*. For loss of heterozygosity (LOH) analysis, we used microsatellite markers D1S180 and D1S235 (for *Exo1*), PMS1.1, D2S118, and D2S155 (for *PMS1*), D2S21153, D2S2156, D2S2292, D2S2369, and D2S378 (for *hMSH2* and *hMSH6*) and D3S1447 and D3S3685 (for *hMLH1*). Only heterozygous loci were regarded as informative and LOH was scored when there was a major reduction (at least 50%) or total loss of one allele in the tumour compared to normal tissues.

Of the seven tumours examined in this study, six showed allelic loss of *hMSH2*, suggesting that the residual normal allele was silenced by LOH (fig 1). In five tumours, allelic loss of *hMSH2* occurred in association with LOH in at least one other mismatch repair gene. Only one tumour had retained heterozygosity at all assessable loci, possibly indicating that a mutation had caused the second hit in this tumour.

Allelic loss of *hMSH2* often occurs in association with germline mutations but it is clear that loss of the other mismatch repair genes is also a frequent finding. Screening tumours for LOH should not be employed to select patients for mutation analysis of mismatch repair genes. The use of immunohistochemistry and microsatellite testing remain the best available prescreening tools.

**R L Ward**

Department of Medical Oncology, St Vincent's Hospital Sydney, Sydney, Australia

**E Mokany**

School of Medicine, University of NSW, NSW, Australia

Correspondence to: Dr R L Ward, Department of Medical Oncology, St Vincent's Hospital, Darlinghurst, Sydney 2010, Australia; r.ward@garvan.unsw.edu.au

**Reference**

- 1 **Wahlberg SS**, Schmeits J, Thomas G, *et al.* Evaluation of microsatellite instability and immunohistochemistry for the prediction of germline MSH2 and MLH1 mutations in hereditary nonpolyposis colon cancer families. *Cancer Res* 2002;**62**:3485–92.

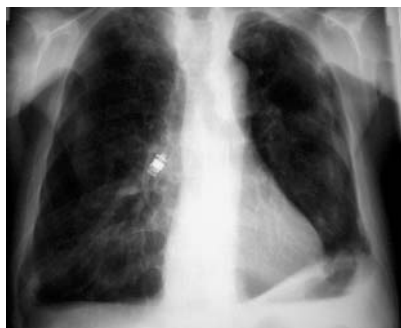**Mild respiratory distress after wireless capsule endoscopy**

A 74 year old male patient was seen in our clinic for chronic diarrhoea. Duodenal biopsies revealed the presence of coeliac disease; upper and lower endoscopies were otherwise unremarkable. As he also presented with marked anaemia and weight loss, he underwent wireless capsule endoscopy (M2A capsule; Given Imaging) in order to exclude additional small bowel pathology.

On the second day after application of the capsule (and before analysis of the pictures), he complained of mild respiratory distress while walking, which had started "right after swallowing the capsule". Physical examination revealed quiet inspiratory and expiratory wheezing, most audible over the central part of the right lung. A chest x ray was obtained (fig 1) which showed aspiration of the video capsule into the right main bronchus. Because of the smooth surface of the capsule, its removal by flexible bronchoscopy proved to be rather difficult, but eventually it was successfully recovered from the bronchial tree. The patient made an uneventful recovery.

He had a history of ankylosing spondylitis with involvement of the cervical spine. Although he reported no symptoms of dysphagia and recalled swallowing the capsule as uneventful, it may be possible that the cervical spine disease contributed to aspiration of the capsule.<sup>1</sup>

To the best of our knowledge, this is the first published case of aspiration of an M2A capsule since this diagnostic method has



**Figure 1** Chest x ray showing aspiration of the video capsule into the right main bronchus (Courtesy of Professor G Kauffmann, Heidelberg, Germany).

become available to general clinical practice. It underlines the recommendations of the manufacturer for cautious use in patients with known or possible swallowing disorders (<http://www.givenimaging.com>).

**F Buchkremer, T Herrmann, W Stremmel**

Medizinische Klinik, Heidelberg, Germany

Correspondence to: Professor W Stremmel, University of Heidelberg, Department of Internal Medicine IV, University Hospital, Bergheimer Str 58, Heidelberg, 69115 Germany; wolfgang\_stremmel@med.uni-heidelberg.de

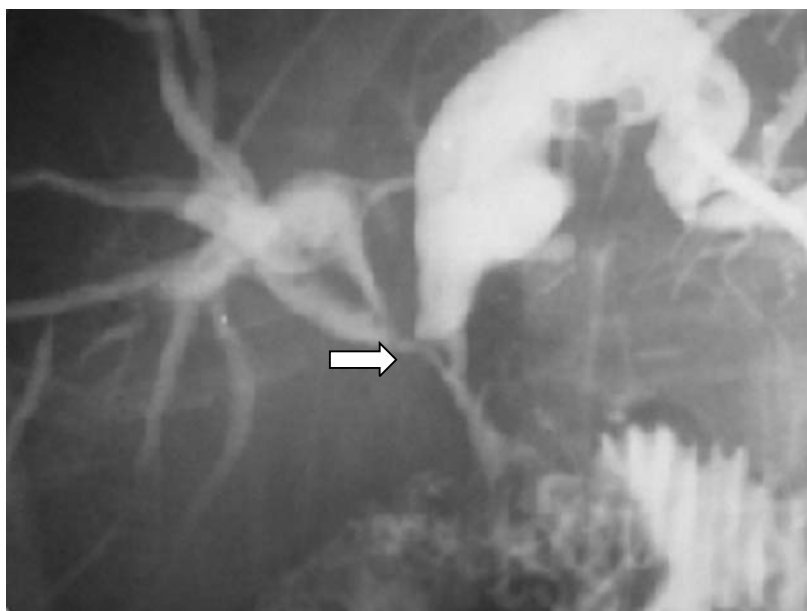**Reference**

- 1 **Di Vito J.** Cervical osteophytic dysphagia: Single and combined mechanisms. *Dysphagia* 1998;**13**:58–61.

**Late development of cholangiocarcinoma after hepaticojejunostomy due to ampullary carcinoma**

We read with great interest the article by Bettschart *et al* (*Gut* 2002;**50**:128–9) which found an increase in cholangiocarcinoma incidence after biliary-enteric drainage for benign disease.

In their hypothesis, changes in biliary epithelium were induced by toxic carcinogenesis due to reflux of intestinal contents and bile stasis. However, this chronic irritation and carcinogenesis of the biliary mucosa after biliary-enteric anastomosis has not been reported after surgery for malignant disease. We present a case of a 65 year old woman who developed a cholangiocarcinoma eight years after duodenopancreatectomy for an ampullary carcinoma, stage I. The patient was referred to our department because of obstructive jaundice and cholangitis. Computed tomography scan showed that the patient was disease free. Percutaneous transhepatic cholangiography showed biliary-enteric anastomosis stricture and a diffuse biliary stenosis.



**Figure 1** Anastomosis stricture and diffuse biliary stenosis. Cholangiocarcinoma (arrow) on the right hepatic duct can be seen.

Percutaneous transhepatic anastomosis dilatation was performed but was ineffective. The patient was operated on and extensive fibrosis and inflammation of the biliary-enteric anastomosis and biliary duct were detected (fig 1). Resection of the stricture and hepatojejunostomy were performed. In addition to fibrotic and inflammatory tissue, histological examination showed a poorly differentiated cholangiocarcinoma with invasion of all levels of the right hepatic duct wall. Surgical margins were free of disease. The patient was discharged on the 10th postoperative day. She died 10 months after surgery.

In common with the authors, we support the hypothesis that reflux of intestinal contents, bacterial translocation, and pancreatic juice can trigger biliary mucosal changes and the carcinogenesis process.<sup>1–3</sup> We believe that apart from those predisposing factors causing chronic cholangitis, there must be susceptibility in these patients due to genetically altered enzymes that are involved in detoxifying carcinogenic products.<sup>4</sup> This is the first case report of malignant transformation in the biliary epithelium after biliary-enteric anastomosis for malignant disease. As there are no markers to identify patients in the early stage of development of malignant transformation, we agree with the authors<sup>1</sup> about monitoring all patients who develop cholangitis after biliary-enteric anastomosis for benign disease and also patients with malignant disease who are in remission.

**D Padilla, T Cubo, R Pardo, J M Molina, J Hernández**

Department of Surgery, Complejo Hospitalario, 13005 Ciudad Real, Spain

Correspondence to: Dr D Padilla; maynona@terra.es

**References**

- 1 **Tocchi A**, Mazzoni G, Liotta G, *et al.* Late development of bile duct cancer in patients who had biliary-enteric drainage for benign disease: A follow-up study of more than 1000 patients. *Ann Surg* 2001;**234**:210–14.



- 2 Perez RL, Gabarrel OA, Vinas SJ, *et al*. Biliary tract cancer following bilioenteric anastomosis. *Rev Esp Enferm Dig* 1994;86:853-5.
- 3 Maeda A, Shumpei Y, Kunou T, *et al*. Bile duct cancer developing 21 years after choledochoduodenostomy. *Dig Surg* 2003;20:331-4.
- 4 Strog RW. Late bile duct cancer complicating biliary-enteric anastomosis for benign disease. *Am J Surg* 1999;177:472-4.

## Adoptive transfer of genetic susceptibility to Crohn's disease

We read with interest the stimulating case report on fulminant Crohn's colitis following allogenic stem cell transplantation by Sonwalkar *et al* (*Gut* 2003;52:1518-21) and the respective editorial.<sup>1</sup> The authors and the editorialists hypothesised on whether the colitis might be ascribed to the adoptive transfer of stem cells displaying genetic alterations which are associated with Crohn's disease. However, the ileal sparing disease localisation and course of the colitis which finally necessitated urgent colectomy is rather unusual for Crohn's colitis. In addition, the genetic mismatch between donor and recipient is hardly compatible with the outlined hypothesis.

According to the cited study by Lesage and colleagues,<sup>2</sup> the allele difference at position -33 of the 5' UTR polymorphism of the NOD2 gene is not regarded as "a disease causing mutation". In line with this concept is the fact that the donor and his first degree relatives did not suffer from Crohn's disease. Apart from this observation, the authors did not describe in detail which particular genetic mutations or polymorphisms differed between the donor and recipient. However, some of the described genes are simply not associated with inflammatory bowel disease. As shown by some of the authors<sup>3</sup> and ourselves,<sup>4</sup> polymorphisms in the MICB gene (which is not situated within the HLA class III but the HLA class I region) are not associated with Crohn's disease. The same holds true for polymorphisms of the HSP70 gene which were weakly associated with a more severe course of Crohn's disease in Japanese patients but not with the disease itself.<sup>5</sup> To the best of our knowledge, data on possible associations between mutations of the LMP2, LMP7, and NOTCH4 gene and Crohn's disease are completely lacking. In conclusion, at best only an extremely weak genetic predisposition can be extracted from the extensive genotyping and thus the postulated transfer of genetic susceptibility remains highly speculative.

The increased incidence of inflammatory bowel disease in patients with congenital immune defects and the recently described increased adherence of bacteria at the intestinal mucosa, which might particularly be facilitated in the presence of mutated NOD2 protein, suggest that the initial event in the complex pathophysiological process in Crohn's disease is compatible with impaired mucosal clearing function which precedes an excessive largely T cell driven immunological activity. This hypothesis is further sustained by various genetically engineered animal models which are protected from the development of enterocolitis under germ free conditions, and therapeutic approaches, such as the use of immunostimulatory substances or antibiotic therapy (for overview see Folwaczny and colleagues<sup>6</sup>). Thus a complementary explanation for the described

phenomenon might be the persistent immunosuppressive therapy the donor had received.

**C Folwaczny, J Glas, T Mussack, H P Török**  
Klinikum Innenstadt, Ludwig-Maximilians University,  
Munich, Germany

Correspondence to: Dr C Folwaczny;  
Christian.Folwaczny@medinn.med.uni-muenchen.de

## References

- 1 Holtmann MH, Neurath MF. Transplanting the genetic susceptibility to Crohn's disease. *Gut* 2003;52:1394-6.
- 2 Lesage S, Zouali H, Cezard JP, *et al*. CARD15/NOD2 mutational analysis and genotype-phenotype correlation in 612 patients with inflammatory bowel disease. *Am J Hum Genet* 2002;70:845-57.
- 3 Ahmad T, Marshall SE, Mulcahy-Hawes K, *et al*. High resolution MIC genotyping: design and application to the investigation of inflammatory bowel disease susceptibility. *Tissue Antigens* 2002;60:164-79.
- 4 Glas J, Martin K, Brunner G, *et al*. MICA, MICB and C1\_4\_1 polymorphism in Crohn's disease and ulcerative colitis. *Tissue Antigens* 2001;58:243-9.
- 5 Esaki M, Furuse M, Matsumoto T, *et al*. Polymorphism of heat-shock protein gene HSP70-2 in Crohn disease: possible genetic marker for two forms of Crohn disease. *Scand J Gastroenterol* 1999;34:703-7.
- 6 Folwaczny C, Glas J, Tarok HP. Crohn's disease: an immunodeficiency? *Eur J Gastroenterol Hepatol* 2003;15:621-6.

## BOOK REVIEWS

### Self Assessment Colour Review of Hepatobiliary Medicine

R Chapman, H C Bodenheimer jr. London: Manson Publishing, 2003, £16.95, pp 192. ISBN 1-874545-48-0

Roger Chapman and Henry Bodenheimer have produced a useful addition to the libraries of gastroenterologists with an interest in liver disease. *Hepatobiliary Medicine* provides 180 questions and answers in 190 pages covering a wide range of hepatobiliary problems. The book will fit in a white coat pocket and is printed on high quality glossy paper. The questions comprise case histories illustrated with laboratory test results and photographs of histology and imaging investigations. Unfortunately, the reproduction does not allow readers to recognise some of the histological and imaging abnormalities referred to in the text, but most can be discerned with the benefit of hindsight (and the answers). The authors have done an excellent job in assembling a diverse collection of cases with relevant images and laboratory data. The questions are presented on one side of the page and the answers are on the reverse, allowing the reader to formulate their own responses without "cheating."

The subject matter of the book encompasses the full range of liver diseases, including a fair smattering of rarities that are only likely to be encountered more than once by specialist hepatologists. Indeed, the content of some of the cases will test experts. *Hepatobiliary Medicine* fulfils the remit of the series, as declared in the book's header, to

help readers "learn, revise, reinforce". Inclusion of a number of paediatric cases will be particularly helpful to adult gastroenterologists/hepatologists who are occasionally asked to see paediatric cases.

The authors have included an index and a list of cases classified by diagnosis. This is extremely useful when using the book for revision or reinforcement. Browsing the classification of cases reveals some surprising choices of emphasis. Eight questions on primary sclerosing cholangitis, seven on Wilson's disease, and one on fatty liver disease hardly reflects the distribution of cases that the general gastroenterologist might encounter but the selection of cases will educate and inform, and the choices reflect the difficulty of diagnostic conundrums rather than disease prevalence.

Publication of this short textbook is timely with the growth of hepatology as a subspeciality and the shortening of training programmes reducing the opportunities for trainees to "learn by osmosis" through case based experience. This book will be particularly useful for trainees in gastroenterology and hepatology.

However, there are a few caveats and some things that could have been done better. *Hepatobiliary Medicine* does not claim to be a textbook but the authoritative voice used in the answers carries an air of certainty. In the vast majority of cases, little fault can be found with the information contained in the answers although the level of knowledge assumed by the authors and that offered to the readers is variable. As a result, some of the information contained in the answers is superficial and some is out of date. Inclusion of key references and a recommended reading list would have been helpful. A compact disc or website presenting the photographic images might enhance the visual aspects of the book.

This book will be useful to trainees in gastroenterology and hepatology, to specialists who are asked to consult on difficult hepatobiliary cases, and even to specialist hepatologists seeking reinforcement of problems they rarely encounter. *Self Assessment Colour Review of Hepatobiliary Medicine* is a useful addition to the gastroenterologist's library.

W Rosenberg

### The Inflammatory Bowel Disease Yearbook 2003

Edited by C Bernstein. London: Remedica Publishing Ltd, 2003, £60.00, pp 179. ISBN 1-901346-57-9

This is the first in a planned yearly series of updates on the latest topics in inflammatory bowel disease clinical practice and research. I was initially sceptical that the hard backed book format could provide a reasonably current overview but was pleasantly surprised that the reviews were topical and cited papers from early 2003 (including for example, the natalizumab trial and wireless endoscopy data). These are aimed at the general gastroenterologist, and those with a more in depth clinical or research interest in inflammatory bowel disease.

Six key current areas are reviewed by experts in the field: conventional drug therapy, the newer biological therapies, serodiagnostics, genetics, imaging developments, and

probiotics. These topics are written by authors expert in the field, and there is little overlap between the chapters—often a problem in the multi-author format. I would have preferred more detail in a few areas (for example, pharmacology/adverse response prediction with azathioprine) and a bit less in others (for example, some of the genetics chapter is too detailed, and it was not easy to differentiate replicated from preliminary findings). All chapters are well referenced, with good tables and figures of key points providing clarity.

The *Yearbook* disappeared once from my shelf while I was trying to review it—to provide preparation for a colleague's brush with the media spotlight—so I would definitely recommend it as a useful update. It might be especially helpful if one had missed out on attending a recent gastroenterology conference. Finally, *Remedica* might be able to further promote the *Yearbook* with a prize for guessing the nature and relevance of the weird industrial plumbing on the cover.

D van Heel

### Fast Facts: Irritable Bowel Syndrome, 2nd edn

W Grant Thompson, K W Heaton. Oxford: Health Press, 2003, £12.00, pp 96. ISBN 1-903734-33-9

Functional gastrointestinal disorders in general, and irritable bowel syndrome in particular, have long been a minefield of misunderstanding and mismanagement which has caused confusion not only to clinicians but also to patients.

In recent years, an international working team have attempted to resolve this babel-like tower of confusion by forming the now famous Rome group and producing Rome criteria which have served to harmonise clinical terms and facilitate trials of therapy. However, in general, ex cathedra statements and weighty tomes from the Vatican have rarely changed the understanding of the gospel for the average cleric or parishioner, and a simpler interpretation is usually required. This little "hymnal" provided by two experienced practitioners with many decades of practical experience and a "cardinal" understanding of the issues of irritable bowel syndrome, now provides just what is necessary to bring the word to the people.

The book's mission is to review in a simple and balanced way what we know (and what we do not know) about the nature of

symptoms, and their causes, and how, in an equally simple and practical way, both the primary care practitioner and patients can help themselves to cope with what is often a disturbing chronic set of problems. Their communication style is clear and concise, and without any tendency to pontificate. While its target readership is stated to be the "family doctor", I am sure that it is equally relevant for the gastroenterologist and for the trainee in gastroenterology for whom the standard textbooks on the subject do not offer much practical guidance in the clinic.

Broadsheet reading patients would also benefit from the balanced view provided by the authors and with luck might in turn reduce their uptake of many of the increasingly bizarre non-orthodox therapies which are now appearing.

The book's first edition appeared in 1999, and has now, by popular demand, been republished in an extensively updated version. It clearly reflects current understanding of the condition and provides a balanced and pragmatic view of its management.

In short, an excellent and up to date pocket psalter for the practitioner.

D Thompson

## NOTICES

### British Society of Gastroenterology Paul Brown Travel Fellowships

The Paul Brown Travel Fellowships are awarded by the Endoscopy Committee of the BSG. They are intended to assist trainee gastroenterologists and established consultants in visits to units outside the United Kingdom for specialist experience and training in endoscopy.

Specialist registrars who have not achieved their CCST are expected to have the approval of their Postgraduate Dean and their Regional Training Director when they apply for a Travel Fellowship. Applicants are expected to provide confirmation that they have been accepted for training in the unit that they wish to visit.

Successful applicants will be expected to provide a brief written report to the Endoscopy Committee of the outcome of their visit.

Application forms are available from the British Society of Gastroenterology Office, 3 St Andrew's Place, London NW1 4LB. Email: bsg@mailbox.ulcc.ac.uk

### PET/CT and SPECT/CT Imaging in Medical, Radiation, Surgical and Nuclear Oncology

This continuing medical education programme will take place on 19–20 March 2004 at Johns Hopkins University School of Medicine, Baltimore, Maryland, USA. Further details: Office of Continuing Medical Education, Johns Hopkins University School of Medicine, Turner 20, 720 Rutland Avenue, Baltimore, Maryland 21205-2195. Tel: +1 410 955 2959; fax: +1 410 955 0807; email: cmenet@jhmi.edu; website: www.hopkinscme.org

### 39<sup>th</sup> Annual Meeting of the European Association for the Study of the Liver

This meeting will be held on 15–19 April 2004 in Berlin, Germany. Further details: Secretariat, c/o Kenes International, 17 rue du Cendrier, PO Box 1726, CH-1211 Geneva, Switzerland. Tel: +41 22 908 0488; fax: +41 22 732 2850; email: info@easl.ch; website: www.easl.ch/easl2004

- Deadline for receipt of abstracts: 16 November 2003
- Deadline for early registration 10 February 2004

### 14<sup>th</sup> International Workshop of Digestive Endoscopy, Ultrasonography and Radiology

The 14<sup>th</sup> International Workshop of Digestive Endoscopy, Ultrasonography and Radiology will be held in Marseille on 27–28 May 2004. For further information, please contact: Nathalie Fontant, Atelier Phenix, 41 rue Docteur Morruci, 13006 — Marseille (tel: (33) 04-91-37-50-83; fax: (33) 04-91-57-15-28; e-mail: nfontant@aphenix.com).

### European Postgraduate Gastro-surgical School (EPGS) Courses 2004

The EPGS at the Academic Medical Center of the University of Amsterdam will be holding the following courses during the year: 'Benign Hepato-Biliary Disorders' will be held on 22 & 23 April 2004, 'Endosonography live in Amsterdam' will be held on 2, 3 & 4 June 2004, and 'Update in Coloproctology' will be held on 28 & 29 October 2004. For further information, please contact: J Goedkoop (tel: (31) 566 3926; fax: (33) 267 5594; e-mail: j.goedkoop@amc.uva.nl; website: www.epgs.nl).