

Radiation enteritis with malabsorption

H. I. TANKEL, D. H. CLARK, AND F. D. LEE

From the Western Infirmary, Glasgow, and the Southern General Hospital, Glasgow

EDITORIAL SYNOPSIS The clinical, biochemical, and radiological features, with the operative findings and relevant histology, in three cases of radiation damage to the small bowel which led to varying degrees of malabsorption, are described. There was no direct correlation between the severity of the mucosal changes and the severity of malabsorption.

Since Walsh first described the condition in 1897, it has been known that irradiation of the pelvis for carcinoma of the uterus or ovaries may be followed by irradiation effects on the bowel. Most reports were of localized stenosis with secondary obstruction usually occurring after an interval of many years. Other reports were of perforation, or of fistulation of small bowel, colon, or rectum into the vagina or bladder (Warren and Friedman, 1942; Mulligan, 1942; Wiley and Sugarbaker, 1950; Colcock and Hume, 1959). Later it was realized that malabsorption occurred in addition to mechanical obstruction, and there were reports of malabsorption of sugar and electrolytes under experimental conditions (Dodds and Webster, 1924; Buchwald, 1931; Moss, 1957) and also of malabsorption of fat (Reeves, Sanders, Isley, Sharpe, and Baylin, 1959). Reeves showed that in about half the patients undergoing a course of irradiation to the lower abdomen there was a transient decrease in fat or fatty acid absorption. Though there is commonly diarrhoea during this phase of treatment the stool does not usually contain an abnormal quantity of fat. Greenberger and Isselbacher (1964) described a patient who had an excessive dose of radiation for a carcinoma of cervix and developed steatorrhoea in addition to proctosigmoiditis, rectal stricture, and intestinal obstruction. They reviewed five other cases in which, however, other causes of malabsorption were not excluded. While the diarrhoea usually clears up shortly after the end of the radiotherapy course, in some cases it continues or recurs, and may then merge into a picture of subacute obstruction or progressively severe steatorrhoea. This may be sufficient to produce malnutrition and lead eventually to death. If resection of bowel is required because of fistulation or obstruction it may fail to heal and result in a serious leakage of intestinal contents.

While many of these early effects were undoubtedly

due to overdosage this was not always the case, and the problem arises even when the dose is undeniably within the therapeutic range. In the following paper, three cases of varying severity illustrating these points will be described. Two of these cases developed steatorrhoea and in one case the excretion of fat was far in excess of the intake.

CASE HISTORIES

CASE 1 On 17 June 1960, a woman, aged 52 years, had a right salpingo-oophorectomy carried out for a lesion which was thought to be an infected dermoid but which proved to be a hypernephroid cystadenocarcinoma of ovary. The excision was considered to be incomplete.

A course of radiotherapy was given, providing a tumour dose of 3,000 r in 20 treatments over a period of four weeks between 5 July and 2 August 1960. Almost from the first day there was an increase in the frequency of the stools. From a normal average of once per day, the motions became frankly watery on the eighth day. Despite treatment with chalk and opium the frequency of her stools rose to 10 per day before the end of the course of radiotherapy (Fig. 1).

The patient remained in reasonably good health, but with continuing diarrhoea till 21 September 1960 when she was readmitted with severe colicky abdominal pain, distension, and loose stools. A straight radiograph of the abdomen showed fluid levels. A laparotomy was performed on 8 October because of continuing severe pain. At operation the omentum was found to be adherent to the abdominal wall and appeared small and shrivelled. The lower half of the small bowel was irregularly dilated with some areas of narrowing and thickening. Some areas were white and others were congested. There were multiple adhesions, portions of small bowel being adherent to one another. During the freeing of the adhesions from the pelvis a hole was made in the small bowel and this portion had to be resected. The wound was closed with drainage.

Histological examination of the resected ileum showed gross submucosal oedema without marked vascular

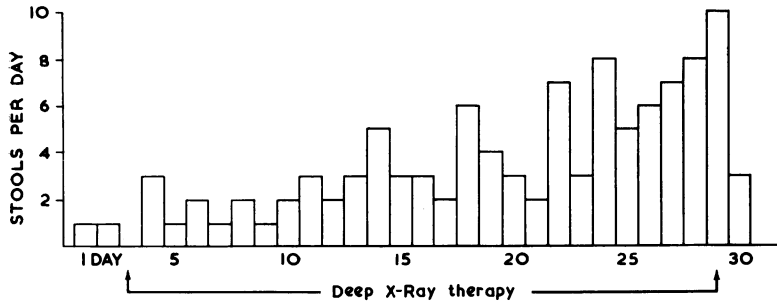


FIG. 1. The increase in the number of stools per day due to deep x-ray therapy in case 1.

alteration. Early fibroblastic proliferation was noted in the submucosa, but was more prominent in the subserous tissues which showed early thickening and some abnormal mesenchymal cell forms. In the mucosa some villi appeared normal but many were shortened, thickened, clubbed, and oedematous; the crypts, although showing a normal number of mitoses, were generally swollen and some showed abnormal branching (Fig. 2). Argentaffin cells appeared to be increased in number.

She made a slow recovery from the operation, her convalescence being delayed by diarrhoea and leakage from the wound.

The faecal fat was estimated on two occasions. On 20 October the average fat excretion was 3 g. per day but 12 days later on 1 November it had risen to 6.5 g. per day. She continued to have loose stools three to four times per day as an out-patient but felt otherwise well until September 1961 when abdominal distension and vomiting recurred. On readmission on 11 September 1961 she was found to have a grossly distended and tympanitic

abdomen with fluid levels again demonstrable radiologically. She was treated initially by drip and suction, and further investigated.

The average faecal fat excretion on 15 September had now reached 31 g. per day. A barium follow through radiograph on 18 September was reported as follows: 'The whole of the small bowel is markedly dilated and transit through it is slow. After 24 hours almost all of the barium is in the large bowel and as far as can be seen it appears normal. The appearances indicate the presence of a subacute obstruction the site of which is in the region of the terminal ileum. The actual obstructive lesion has not been demonstrated' (Fig. 3). Barium enema was negative.

Sigmoidoscopy showed an essentially normal mucosa with a suggestion of thickening higher up but a biopsy at 15 cm. showed normal mucosa, submucosa, and muscularis mucosa.

An attempt was made to reduce the stool frequency by a course of neomycin and nystatin but this tended to

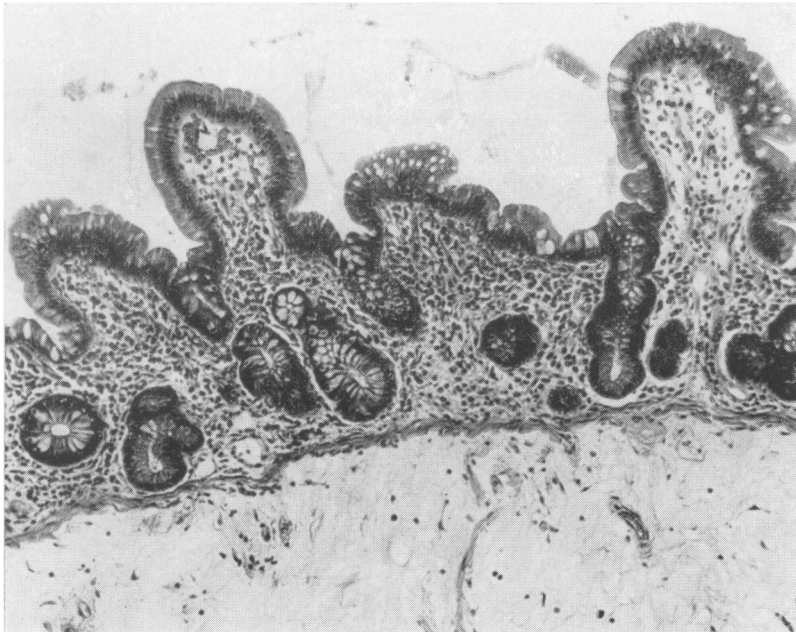


FIG. 2. Shortened, thickened and irregular mucosal villi in the ileum of case 1. The crypt irregularity is suggestive of previous ulceration. Note the intense submucosal oedema. Haemalum-eosin $\times 120$.

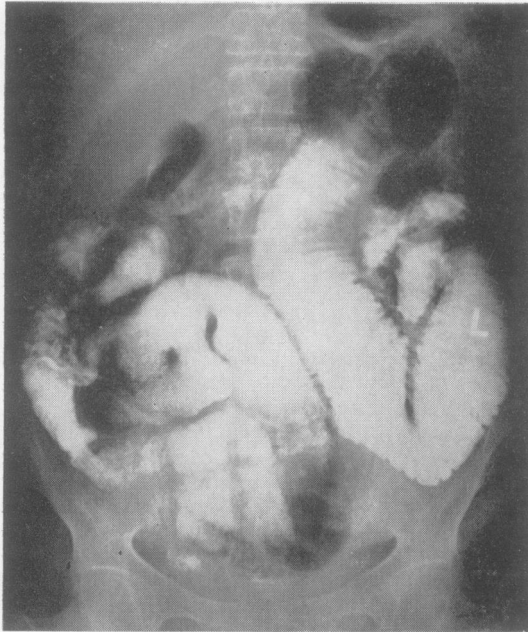


FIG. 3. Barium follow through examination in case 1 showing marked dilatation of small bowel.

aggravate bowel frequency which was in turn uninfluenced by a gluten-free diet (Fig. 4). The faecal fat excretion at the beginning of this period (30 September to 4 October) averaged 129.5 g./day.; by the end (18 October to 21 October) this had risen to 153.3 g./day. This was in excess of the fat intake which, though not measured, was less than that of an average hospital diet (since the patient was eating poorly) and certainly not more than 100 g./day. The progress of the faecal fat excretion can be seen in Table I.

TABLE I

FAECAL FAT EXCRETION

Date	Average Fat Excretion (g./day)
20 Oct. 1960	3.0
1 Nov. 1960	6.5
15 Sept. 1961	31.0
30 Sept. 1961	121.5
18 Oct. 1961	153.3

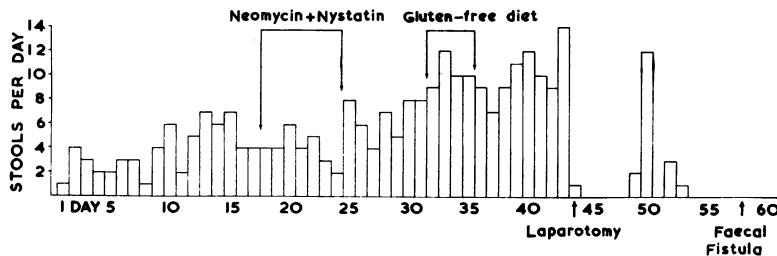


FIG. 4. Stool frequency in case 1 uninfluenced by intestinal antibiotics or gluten-free diet.

Increase in pain and distension again demanded laparotomy on 24 October. Again there were innumerable adhesions and a long time was spent in freeing the bowel so that continuity could be followed from the duodeno-jejunal junction to the caecum. There were many possible points of obstruction, the main one being where the small bowel was adherent to the rectum and the uterus. The omentum was atrophied. The ileum was still rather thick and white but less markedly so than at the first operation. There were two other points at which the bowel was particularly narrowed by adhesion, fibrosis, and kinking. Six inches of bowel at each of these two points was resected with end-to-end anastomosis.

The pathological appearances were similar to the previous specimen. Submucosal oedema was still prominent with lymphangiectasis in some areas, but connective tissue proliferation was more pronounced. The subserosa was thickened with hyalinized connective tissue, but few abnormal cells were seen. Atrophic areas were present in the mucosa but in general the villi appeared normal. Increased leucocytic infiltration in the lamina propria was probably the result of intestinal obstruction.

Operation was followed by ileus which gave way to severe diarrhoea on the sixth day. A faecal fistula developed on the thirteenth day, whereupon the patient went steadily downhill despite all the usual resuscitative measures and died on 19 November 1961.

Post-mortem examination There was no evidence of tumour recurrence. In the peritoneal cavity, loops of small and large bowel were matted together by dense fibrous adhesions, and the faecal fistula in the operation wound communicated with an adherent loop of jejunum. The small intestine was irregularly dilated and extremely friable although the duodenum and colon appeared normal. Histologically numerous sections of ileum and jejunum showed dense subserosal and submucosal thickening with hyalinized connective tissue, but no abnormal cells were detected. The blood vessels were dilated in places, although hyalinization of the vessel wall was not a prominent feature. The mucosa was autolysed.

In summary, this patient showed the development of severe diarrhoea starting during a course of radiotherapy to the pelvis. Steatorrhoea was first noted 13 weeks after the completion of the course and increased in severity until the fat excretion was higher than the intake. Subacute obstruction occurred and laparotomy and resection led to fistulation.

CASE 2 On 8 October 1962 a woman aged 62 had a total hysterectomy and bilateral salpingo-oophorectomy for adenocarcinoma of the uterine body which was found to be infiltrating the peritoneum at the back of the fundus of the uterus. She made an uncomplicated recovery from the operation and then received 6-600 rads in 45 days with the Orbitron cobalt unit between 5 November and 20 December. Intermittent diarrhoea with some nausea and vomiting occurred during treatment and continued afterwards, with occasional abdominal distension beginning in March 1963. On 11 June 1963 she was admitted for investigation with a tentative diagnosis of radiation enteritis. By this time she had lost 2 stones in weight. A straight radiograph of the abdomen showed multiple fluid levels in the small bowel and a barium meal and follow through showed a relatively normal proximal jejunum but some hold-up in the distal jejunum. Distal to this there was gross dilatation and mucosal hypertrophy with a large amount of residue in dilated loops of ileum after six and a half hours. A right staghorn calculus was also noted. The Hb was 7.4 g.%; P.C.V. 25%; M.C.H.C. 29.8%; serum iron 10 μ g.%; total iron-binding capacity 255 μ g./100 ml.; percentage saturation 3.9; serum B₁₂ 120 μ g./ml. Faecal fat excretion averaged 7.2 g./day. Xylose excretion was 3.2 g./5 hours. Sigmoidoscopy on 1 July was normal and a biopsy was microscopically normal. Some improvement in the obstructive symptoms occurred but was followed six weeks later by relapse with abdominal colic, distension, and vomiting. After a further four weeks, in August 1963, a faecal fistula developed, discharging through the vagina. The patient's condition deteriorated rapidly and a defunctioning transverse colostomy was carried out on 16 August.

The small bowel was found to have areas of whitish thickening alternating with reddened areas. There was a general loss of flexibility but no actual dilatation. There were no generalized adhesions but there were localized adhesions in the area of the vault of the vagina which prevented accurate examination. It was thought that fistulation had occurred between the vagina and low colon or rectum and that a transverse colostomy would provide an adequate bypass. A biopsy of small bowel was taken where the bowel appeared thickened and oedematous.

Histological examination of the small bowel showed marked submucosal and subserosal thickening due to oedema and early connective tissue proliferation. Many abnormal mesenchymal cells were seen throughout the bowel wall. The mucosa was atrophic with absent or stunted villi (Fig. 5); cellular infiltration was increased with numerous plasma cells and macrophages laden with haemosiderin, and argentaffin cells were prominent. Arteriolar hyalinization was pronounced in the submucosa (Fig. 6).

Postoperatively the fistula continued to discharge and it was realized that the fistula arose from small bowel and not large bowel. At a further laparotomy on 23 August the fistula was excised with about 8 in. of ileum.

The histological features of this portion of ileum were similar to the biopsy with the addition of extensive mucosal ulceration and inflammatory infiltration close to the fistula. Many abnormal cell forms, with giant nuclei and prominent nucleoli, and occasional multinucleated cells were found in the active granulation tissue in ulcer bases (Fig. 7) and pyloric metaplasia was demonstrated in the regenerating mucosa at ulcer margins (Fig. 8).

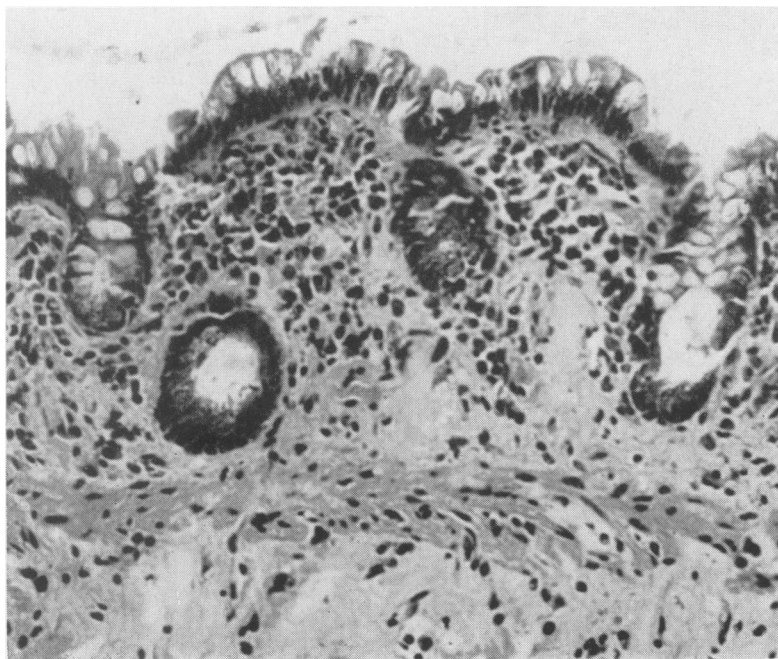


FIG. 5. Gross atrophy of the ileal mucosa with increased round-cell infiltration at the lamina propria in case 2. Haemalum-eosin \times 290.

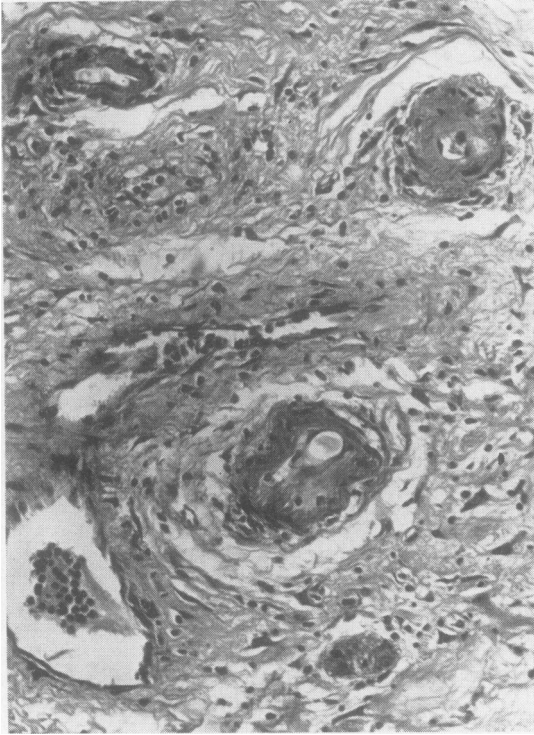


FIG. 6. Small submucosal arteries in the ileum showing hyalinization and intimal proliferation in case 2. Haemalum-eosin $\times 525$.

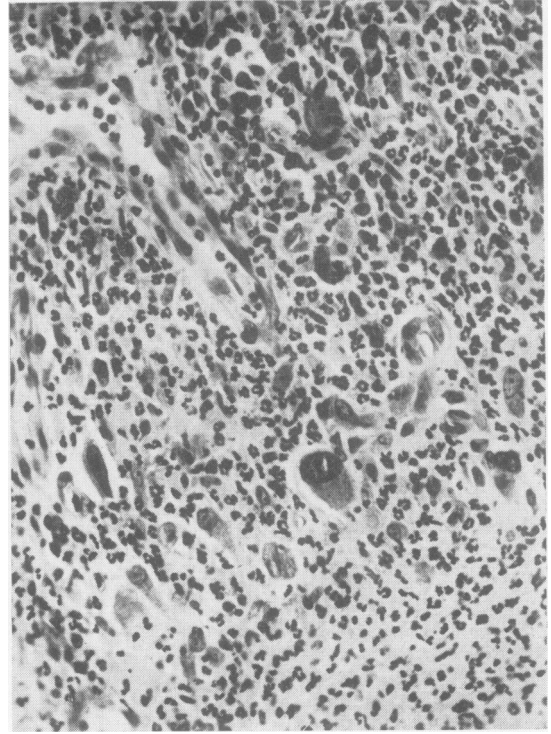


FIG. 7. Abnormal mesenchymal cells developing in granulation tissue at the base of a superficial ulcer in the ileum (case 2). Haemalum-eosin $\times 450$.

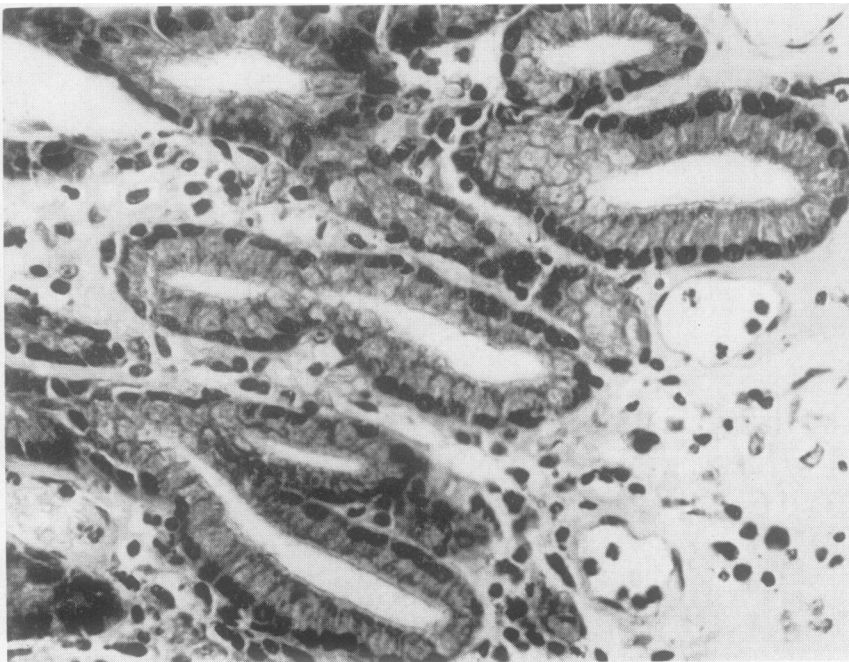


FIG. 8. Pyloric metaplasia in an early phase developing in an area of healing ulceration in the ileum in case 2. Haemalum-eosin $\times 450$.

The patient had a stormy postoperative course. The vaginal fistula healed but the faecal fistula recurred through the wound and the patient gradually deteriorated. She eventually died following a cerebrovascular accident on 15 October.

Post-mortem examination The jejunum was almost paper thin in parts. There were multiple adhesions between small bowel loops. There was no evidence of any tumour recurrence.

In summary, this patient presents a picture of diarrhoea starting with the course of radiotherapy and continuing intermittently thereafter. Subacute obstruction developed along with malabsorption of fat and iron deficiency. The vitamin B₁₂ level was low and xylose excretion diminished. Fistulation occurred between the ileum and the vagina and this was probably the site of obstruction. Radiation changes were demonstrated in the small bowel. The fistulation recurred after resection.

CASE 3 The patient was a woman aged 62 years who had a well-differentiated stage I carcinoma of cervix diagnosed by biopsy on 4 August 1961. A course of intracavitary radium lasting 50 hours was given on 8 August and another of 70 hours on 15 August followed by a course of deep x-ray therapy at 250 kv delivered in 12 treatments over four weeks between 21 August and 5 September.

Diarrhoea started on the second day of the deep x-ray therapy and was followed 10 days later by some abdominal pain, nausea and vomiting, which was, however, rapidly controlled by sparine. The diarrhoea, however, continued until her discharge home on 1 October (Fig. 9). She then remained reasonably well until she was readmitted on 7 November suffering from subacute obstruction of one week's duration, and symptoms and signs of perforation of two day's duration.

She was treated with antibiotics, drip, and suction till eventually the infection localized to two abscesses, a small one in the left iliac fossa and a large one on the right side of the abdomen. The latter gradually resolved on its own, but the former required incision and drainage on 21 November when about 600 ml. of pus was evacuated. It yielded a pure growth of coliforms. In the meantime, however, diarrhoea had continued despite large doses of neperthe and further investigations were carried out. The faecal fat excretion was found to be only 1.7 g./day on 12 December. The xylose excretion test was normal but there was a failure to absorb vitamin B₁₂.

A barium enema on 14 December showed narrowing of the sigmoid colon and a narrow area of the descending

colon at the distal end of which a leak of barium was noted. The wall of the narrowed segment was irregular and consistent with an inflammatory lesion. There was no evidence of diverticulosis or neoplasm.

On 20 December a barium meal and follow through demonstrated clumping of barium in the small bowel consistent with the deficiency pattern of steatorrhoea.

Blood and electrolyte estimations showed no specific abnormalities other than some anaemia and mild electrolyte disturbance.

No intestinal pathogens were isolated.

Since malabsorption of fat had not been demonstrated, it was felt that the diarrhoea might be due to colonic irritation, and that this might respond to a defunctioning transverse colostomy.

At laparotomy on 4 January 1962 a transverse colostomy was fashioned. The small bowel was covered with fine filmy adhesions which separated with ease, but otherwise the naked-eye appearances were normal and there was no distension. There were one or two isolated thicker vascular adhesions; in particular there was a large adhesion about 1 in. in diameter between the omentum and the lower part of the jejunum. This was divided and the jejunal portion taken as a biopsy of the jejunum. This might possibly have been a site of subacute obstruction in the past. There were rather denser adhesions in the region of the left iliac fossa where the previous abscess had been. There was no abscess cavity intraperitoneally and no evidence of colonic attachment to an old abscess. The pelvis was obliterated by fibrosis presumably secondary to irradiation, and the lower part of the pelvic colon and rectum could not be palpated. The ileo-caecal region was also difficult to define although the ascending colon appeared normal. A biopsy of the ileum was taken about 18 in. proximal to the ileo-caecal region because of the failure to absorb vitamin B₁₂.

Histologically the ileal biopsy showed submucosal oedema and early fibrosis. The mucosal villi were generally shortened and oedematous (Fig. 10) with an average height of 275 μ , which is below the normal range of 320 to 520 μ (Shiner and Doniach, 1960). The serosal tissues and a portion of attached mesentery were thickened by organizing exudate in which active fibroblasts with marked nuclear irregularity and pleomorphism were noted.

The jejunal biopsy also showed submucosal and subserosal thickening and a mild mucosal atrophy similar to the ileum.

To complete the picture, a sigmoidoscope was passed on 16 January 1962 to 13 cm. The rectum was inflamed, especially below 10 cm., the appearances being those of proctitis. A biopsy taken at 8 cm. showed mild non-

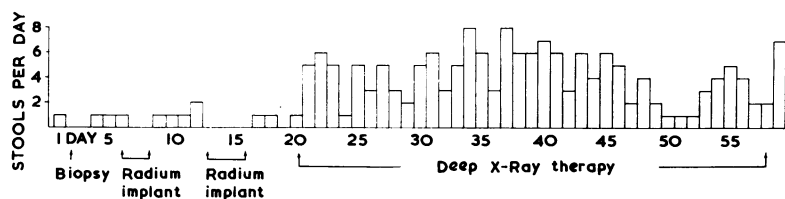


FIG. 9. Stool frequency in case 3 showing that radium implant had no effect but deep x-ray therapy produced diarrhoea.

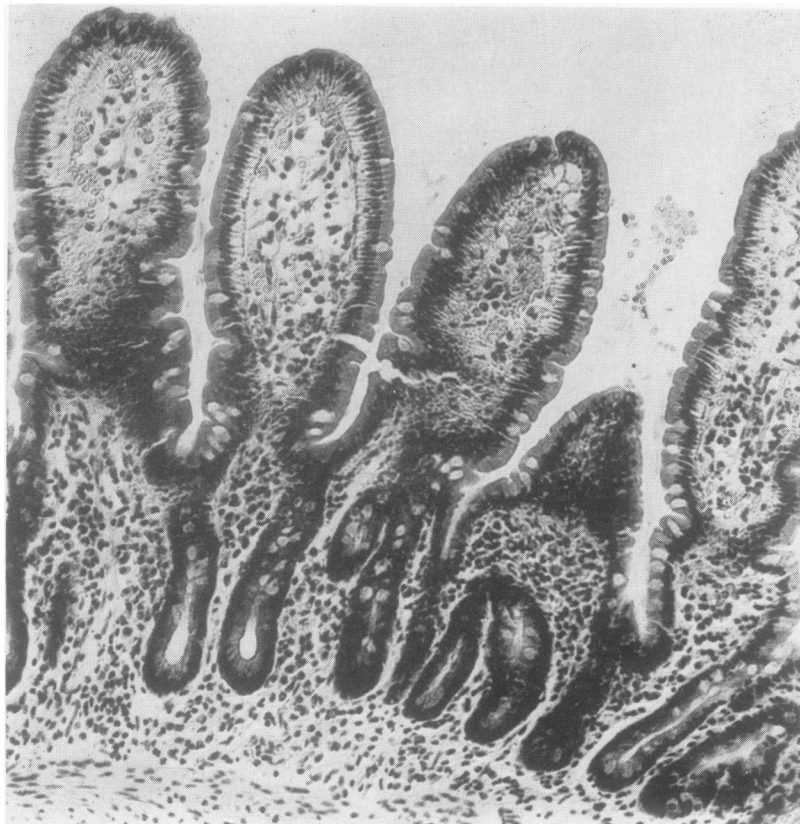


FIG. 10. *Heil biopsy showing slight shortening, thickening and oedema of the mucosal villi, with a mild increase in round-cell infiltration in the lamina propria in case 3. Haemalum-eosin $\times 190$.*

specific chronic inflammatory infiltrate, but there was no evidence of radiation changes or malignancy. These appearances might have been secondary to the diarrhoea.

Following operation the rectal diarrhoea settled within a week and the colostomy began to function normally, producing one or two semi-solid stools per day. The patient was dismissed home on 27 January.

The colostomy was finally closed nine months later elsewhere, and though the patient has refused to return for follow up, reports from her doctor indicate that she remains well without any evidence of recurrence of tumour, or any evidence of bowel irritation. She has a normal bowel habit and can probably be assumed on this basis to have no significant steatorrhoea.

In summary, this patient demonstrates a less severe lesion in which radiation changes in the small bowel were demonstrated on biopsy, but who never developed steatorrhoea and in whom the diarrhoea may have been of colonic origin since improvement followed bypass of the distal colon. She not only presented with subacute obstruction, but also with a perforation of colon at a surprisingly high level, namely, the junction of descending and pelvic colon.

DISCUSSION

CLINICAL FEATURES The three cases described present a spectrum of the changes which occur as a result of radiation to the pelvis for pelvic tumours. All of them developed diarrhoea in the course of their initial radiation treatment. This in the main failed to settle and was followed after a few weeks by symptoms of subacute obstruction with colic and abdominal distension. All showed some form of malabsorption. The first two showed malabsorption of fat with an output eventually higher than the intake in case 1. The third showed malabsorption of vitamin B₁₂ only. Case 2 showed early spontaneous fistulation between small bowel and vagina. Case 3 showed early perforation of the descending colon away from the target and not, as usually described, of the rectum or of small bowel adherent to pelvic organs. Cases 1 and 2 demonstrated the failure to heal after resection.

The biopsy material, radiographs, and post-mortem findings in these cases, together with the reports of previous cases in the literature, enable us

to paint a picture of the response to pelvic irradiation. Three stages can be distinguished.

Stage I Almost all patients undergoing a course of pelvic irradiation develop diarrhoea which begins two or three days to a week after the start of treatment. This diarrhoea may become distressing but it is rarely fatal, though Mulligan (1942) reports one case of death at this stage from severe generalized mucosal necrosis. Reeves *et al.* (1959) have recorded that 13 of 39 patients showed evidence of mild steatorrhoea and malabsorption of fat at this stage, but this rapidly subsided. Presumably this diarrhoea is due to simple inflammation of the mucosa of the small bowel and colon, a response analogous to the skin reaction with which we are all familiar. However, intracavitary radium does not produce this effect probably because its action is more localized. We have no information in our own cases about the fat excretion during the initial treatment but we do have evidence of a period of normal fat excretion after this stage in all, and before malabsorption started in cases 1 and 2.

Stage II In a small number of patients the diarrhoea fails to settle and the symptoms of subacute obstruction become superimposed upon the previous picture. This constitutes the second stage. There is colicky abdominal pain and distension, which may be combined with continuing diarrhoea, and fluid levels can be demonstrated on radiographs. The patient may again settle spontaneously at this stage which may occur as early as three months after treatment. Sometimes the obstructive element is severe enough to demand laparotomy which then reveals dilated segments of bowel alternating with areas of comparative normality. The surface of the bowel is whitish or congested and may be covered with multiple filmy adhesions or occasional tough adhesions. The bowel is thickened and appears relatively avascular when cut. The exact point or points of obstruction may be difficult to determine and therefore any decision about local resection may also be difficult. If resection is carried out fistulation may follow due to avascularity. At the beginning of this stage the general nutrition of most patients may be satisfactory though some are grossly depleted and weakened (Wiley and Sugarbaker, 1950). After treatment there may again be a period of quiescence.

Stage III The third stage is the stage of malabsorption. It may occur early and overlap the second stage or may occur after an interval of time. Malabsorption of electrolytes has been described by Dodds and Webster (1924) and Buchwald (1931) but only under highly artificial experimental conditions. In our own cases we have demonstrated malabsorption of vitamin B₁₂, iron, xylose, and fat.

The fatty diarrhoea may increase relentlessly until, as in case 1, we have an example of a fat excretion which actually exceeds the intake, presumably due to actual excretion of endogenous fat through the bowel wall as was suggested by Mead, Decker, and Bennett (1951) who found that irradiation of mice produced an increase in the fat loss in the stool although the mice were on a fat-free diet, a sort of fat-losing enteropathy. Once nutrition fails, the effects of further subacute obstruction and the risks of resection are greatly increased, and these patients are likely to die from fistulous loss and inanition.

In a certain number of cases, these stages may be short-circuited and local necrosis with fistulation (Cutler, 1942; Wiley and Sugarbaker, 1950) or perforation may occur (Peterson and Clausen, 1956; Colcock and Hume, 1959). Spackman (1948) suggested that this might be due to previous localized adhesions of gut within the pelvic area so that local overdosage occurs, the commonest outcome being a recto-vaginal or recto-vesical fistula. This particular effect may be considered as an accident and is not directly related to the more widespread changes we are describing.

A further group of patients may be well for many years and then develop obstruction due to local stenosis often related to an unhealed ulcer which may have been present for a long time (Frank and Pohle, 1951; Anderson, Witkowski, and Pontius, 1955; Peterson and Clausen, 1956). In some cases haemorrhage may occur from such an ulcer even after many years (Gardner and Anlyan, 1952). This may or may not be in an area of more widespread radiational change (Abrahamson, 1960). Norton, Mahowald, and Monroe (1962) describe one unusual case in which a choleic acid enterolith became impacted behind a localized area of radiation jejunitis 19 years after therapy.

PATHOLOGY The symptoms that have been described have to be correlated with the pathological changes in the intestinal tract, and we have been fortunate in being able to follow these changes over a period of as long as 15 months in the same patient. The histological findings in our cases are essentially similar to those reported by Mulligan (1942) and Anderson *et al.* (1955) and fulfil most of the criteria required to diagnose radiation effect histologically (Warren and Friedman, 1942). The changes are to some extent influenced by the time interval following irradiation. Thus submucosal oedema is prominent in all cases, mainly in the earlier stages. Connective tissue proliferation is observed first in the serosal coat, extending at a later stage to the submucosa, and hyalinization of connective tissue was most pronounced in case 1, 15 months after irradiation.

Abnormal mesenchymal cells are seen in all cases mainly in the serosal coat, but were conspicuous also in the active granulation tissue in zones of ulceration in case 2. Arteriolar changes such as intimal proliferation and hyalinization of vessel walls were most marked in case 2, vascular changes apart from telangiectasis being less prominent in the other cases.

The mucosal changes are of interest with regard to the development of malabsorption since they bear a superficial resemblance to those found in the primary malabsorptive disorders. The mucosal villi exhibit abnormalities varying in severity from partial (Fig. 2) to subtotal villous atrophy (Fig. 5) as seen in idiopathic steatorrhoea (Shiner and Doniach, 1960) although the characteristic surface epithelial changes are lacking. In some areas 'mucosal atrophy' clearly represents a phase of regeneration following ulceration, particularly while there is crypt irregularity (Fig. 2) and pyloric metaplasia (Fig. 8). Elsewhere it is possible that irradiation has damaged 'stem' cells and interfered with the normal process of cell replacement (Quastler, 1963) resulting in an atrophic mucosal pattern. There is, however, no close correlation between mucosal atrophy and malabsorption. In case 1, the mucosa had almost returned to normal latterly despite persistent and increasing malabsorption; and in case 3 malabsorption did not develop although mucosal atrophy of extensive degree could be demonstrated. The cause of malabsorption, particularly in the later stages of the disease, is thus uncertain although the history of frequent obstructive episodes in case 1 suggests that a situation analogous to the 'blind loop' syndrome may pertain in this case. Even so, antibiotics were without effect in reducing malabsorption.

On the other hand, biopsy of the colon in these patients did not reveal any typical abnormal finding other than mild non-specific inflammatory changes in case 2. As this area is clearly within the radiation field it would seem that the colon is more resistant to the effects of irradiation than is the ileum which is in accordance with the experimental evidence of Warren and Whipple (1922a and b) and Buchwald (1931). It may be that the significant factor in the resistance of the colon is the rate of turnover of the mucosal cells, the more rapidly changing cells of the colon being more resistant than the cells of the ileum which are turning over at only half the rate, as demonstrated by Creamer, Shorter, and Bamforth (1961). While this may be so, it is interesting that in case 3 transverse colostomy cured the diarrhoea although there were obvious radiational changes in the small bowel and an absence of severe change in the colon. It may be that here some degree of residual infection in the left para-colic gutter was

responsible for the colonic irritability or a factor adding to it.

RADIOLOGY The x-ray appearances are essentially non-specific. In the stage of subacute obstruction fluid levels can be demonstrated and there may be irregular areas of dilatation and mucosal thickening. In the stage of malabsorption the typical flocculation pattern may be seen. None of these features are diagnostic of radiation effects though their occurrence following a course of radiotherapy should give rise to the suspicion of radiation changes (Jacobs, 1963).

TREATMENT The treatment of the condition is difficult. The initial diarrhoea has to be treated symptomatically by kaolin and nepenthe, codein phosphate, and similar preparations. If subacute obstruction develops then conservative measures with drip and suction should be persevered with until laparotomy is demanded by the development of more acute obstruction or perforation. Laparotomy is likely to be followed by resection either of a fistula already present, or of an area of gut damaged in an attempt to divide adhesions. Any resection carries with it the risk of further fistulation through an anastomotic leak because of failure to heal due to avascularity of the bowel. We were completely unable to influence the progress and severity of the steatorrhoea which occurred in case 1.

It is possible that in certain cases a pre-existing mucosal abnormality may be present and may influence the effect of subsequent radiotherapy but we have no information on this point.

Finally, a word about terminology. It seems reasonable to confine the term 'radiation enteritis' to the succession of changes associated with widespread microscopic changes in the small bowel and to refer to localized strictures, perforations, and fistulation as post-radiational stricture, perforation, or fistula.

We are grateful to Mr. K. Fraser, Professor A. W. Kay, and Dr. Mary Cowell for their help and encouragement in the preparation of this paper. We also wish to thank the Pathology Departments of the Western Infirmary and Southern General Hospital, Glasgow, for the histology reports, Mr. G. Kerr for the photomicrographs, and Mr. Gabriel Donald for the histograms and x-ray photographs.

REFERENCES

- Abrahamson, R. H. (1960). Radiation ileitis. *Arch. Surg.*, **81**, 553-557.
 Anderson, R. E., Witkowski, L. J., and Pontius, G. V. (1955). Radiation stricture of the small intestine. *Surgery*, **38**, 605-609.
 Buchwald, K. W. (1931). The influence of x-ray lesions of the intestinal mucosa on absorption of glucose and other sugars. *J. exp. Med.*, **53**, 827-833.
 Colcock, B. P., and Hume, A. (1959). Radiation injury to the sigmoid and rectum. *Surg. Gynec. Obstet.*, **108**, 306-312.
 Creamer, B., Shorter, R. G., and Bamforth, J. (1961). The turnover and shedding of epithelial cells. Part I. The turnover in the gastro-intestinal tract. *Gut*, **2**, 110-116.

- Cutler, M. (1942). Complications of radiotherapy in cancer of the cervix. *Surg. Gynec. Obstet.*, **74**, 867-870.
- Dodds, E. C., and Webster, J. H. D. (1924). The metabolic changes associated with x-ray and radium treatment. *Lancet*, **1**, 533-537.
- Frank, R. C., and Pohle, E. A. (1951). Late radiation reaction in the small intestine manifest 8 years after therapy: report of a case. *Ann. Surg.*, **133**, 104-108.
- Gardner, C. E. Jr., and Anlyan, W. G. (1952). Radiation injury to the small intestine: a report of one case of massive hemorrhage and one of perforation following therapy for carcinoma of the cervix. *Surgery*, **31**, 746-749.
- Greenberger, N. J., and Isselbacher, K. J. (1964). Malabsorption following radiation injury to the gastrointestinal tract. *Amer. J. Med.*, **36**, 450-456.
- Jacobs, L. G. (1963). Unusual case of late post-irradiation damage to the ileum. *Radiology*, **80**, 57-61.
- Mead, J. F., Decker, A. B., and Bennett, L. R. (1951). Effect of x-irradiation upon fat absorption in the mouse. *J. Nutr.*, **43**, 485-499.
- Moss, W. T. (1957). The effect of irradiating the exteriorized small bowel on sugar absorption. *Amer. J. Roentgenol.*, **78**, 850-854.
- Mulligan, R. M. (1942). The lesions produced in the gastrointestinal tract by irradiation. General review with illustrative case report. *Amer. J. Path.*, **18**, 515-527.
- Norton, R. A., Mahowald, T. A., and Monroe, L. S. (1962). Radiation jejunitis and a choleic-acid enterolith. Report of a case. *Amer. J. digest. Dis.*, **7**, 634-641.
- Peterson, H. H., and Clausen, E. G. (1956). Radiation injury to the small bowel with special consideration of surgical complications. *Gastroenterology*, **31**, 47-55.
- Quastler, H. (1963). Effects of irradiation on intestinal mucosal cell population. *Fed. Proc.*, **22**, 1330-1333.
- Reeves, R. J., Sanders, A. P., Isley, J. K., Sharpe, K. W., and Baylin, G. J. (1959). Fat absorption from the human gastrointestinal tract in patients undergoing radiation therapy. *Radiology*, **73**, 398-401.
- Shiner, M., and Doniach, I. (1960). Histopathologic studies in steatorrhea. *Gastroenterology*, **38**, 419-440.
- Spackman, J. G. (1948). Obstructive lesions of the small intestine and sigmoid due to irradiation. *Ann. Surg.*, **127**, 121-127.
- Walsh, D. (1897). Deep tissue traumatism from Roentgen ray exposure. *Brit. med. J.*, **2**, 272-273.
- Warren, S. C., and Friedman, N. B. (1942). Pathology and pathologic diagnosis of radiation lesions in the gastrointestinal tract. *Amer. J. Path.*, **18**, 499-513.
- and Whipple, G. H. (1922a). Roentgen ray intoxication. I. Unit dose over thorax negative—over abdomen lethal. Epithelium of small intestine sensitive to x-rays. *J. exp. Med.*, **35**, 187-202.
- , — (1922b). Roentgen ray intoxication. II. A study of the sequence of clinical, anatomical, and histological changes following a unit dose of x-rays. *Ibid.*, **35**, 203-211.
- Wiley, H. M., and Sugarbaker, E. D. (1950). Roentgenotherapeutic changes in the small intestine. Surgical aspects. *Cancer, (Philad.)*, **3**, 629-640.